

## A case of malignant fibrous histiocytoma of the ilium, evaluation by blood-pool scintigraphy

Hitoya OHTA,\*<sup>1</sup> Tomoo KOMIBUCHI,\*<sup>1</sup> Mitsuo TOMIHARA,\*<sup>2</sup> Yoriko ASANO,\*<sup>2</sup> Hideo WATANABE,\*<sup>2</sup>  
Shigeyoshi FUJIKAWA,\*<sup>2</sup> Noriaki MURAOKA,\*<sup>3</sup> Giro TODO,\*<sup>3</sup> Kunikatsu IRIE,\*<sup>4</sup>  
Masayuki SHINTAKU\*<sup>4</sup> and Hiroyuki KOKURYU\*<sup>5</sup>

*\*<sup>1</sup>Department of Laboratories, \*<sup>2</sup>Orthopedics, \*<sup>3</sup>Radiology, \*<sup>4</sup>Pathology,  
and \*<sup>5</sup>Internal Medicine, Osaka Red Cross Hospital*

A rare case of malignant fibrous histiocytoma (MFH) of the ilium was presented and blood-pool scintigraphic images and angiographic images were correlated. Hypervascular tumor and laking of contrast material with arteriovenous shunts were shown by angiography. Intensive tracer accumulation was shown by blood-pool scintigraphy. After radiation therapy and transcatheter arterial embolization of the tumor, tracer accumulation was noticeably reduced. These findings suggested a vascular tumor such as angiosarcoma, but surgery revealed MFH of the bone. Blood-pool scintigraphy was useful in the evaluation of the vascular characteristics of the tumor.

**Key words:** malignant fibrous histiocytoma, bone, blood-pool imaging

### INTRODUCTION

MALIGNANT FIBROUS HISTIOCYTOMA (MFH), a tumor thought to arise from tissue histiocytes is the most common soft tissue sarcoma of late adult life.<sup>1</sup> But MFH of bone is rare.<sup>2</sup> We report a case of MFH of the ilium in which blood-pool scintigraphy was useful in the evaluation of the vascular characteristics of the tumor.

### CASE REPORT

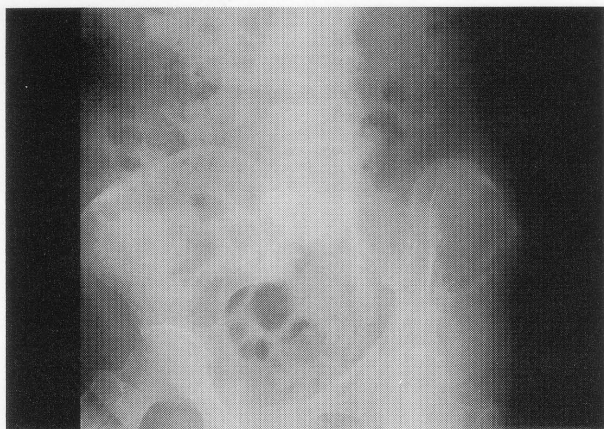A 65-year-old female was referred to the department of orthopedics in our hospital because of swelling of the left iliac region, where vascular murmur was heard. Hematological examination and blood chemistry findings were within normal limits. A pelvic radiograph showed a lytic lesion of the left ilium with an associated soft tissue mass (Fig. 1). CT section through the midportion of the lesion showed expansion and disintegration of bone structure in the left wing of the ilium with "sunburst" periosteal reaction, surrounded by a large tumor (Fig. 2). Since vascular murmur was heard in the lesion, blood-pool

scintigraphy was performed 30 minutes after intravenous injection of 740 MBq of technetium-99m-diethylene-triamine pentaacetic acid human serum albumin (<sup>99m</sup>Tc-HSA-D) with a Toshiba GCA-7200A gamma camera equipped with a high-resolution low energy collimator, and 2,000 K counts were acquired. Strong abnormal tracer accumulation in the lesion was recognized (Fig. 3). Angiography performed on the same day showed marked hypervascularity, laking of contrast material and arteriovenous shunts (Fig. 4). Radiation therapy (total 50 Gy) and transcatheter arterial embolization (TAE) of the tumor was performed. Follow-up angiography showed reduced hypervascularity (Fig. 5). Blood-pool scintigraphy performed 24 days after follow-up angiography showed greatly reduced tracer accumulation (Fig. 6). Tracer accumulation corresponded well to the laking of contrast material in the angiogram, and these findings suggested a vascular tumor such as angiosarcoma. The patient underwent surgical treatment which revealed MFH of the ilium (pleomorphic type) (Fig. 7).

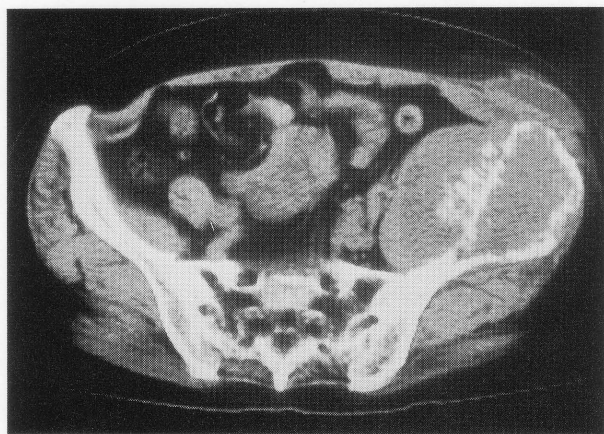
### DISCUSSION

Among primary malignant bone tumors, the incidence of MFH is low.<sup>2</sup> The tumors may occur at any age, although the average age is approximately 50 years. The most common sites of involvement are the femur, tibia, hu-

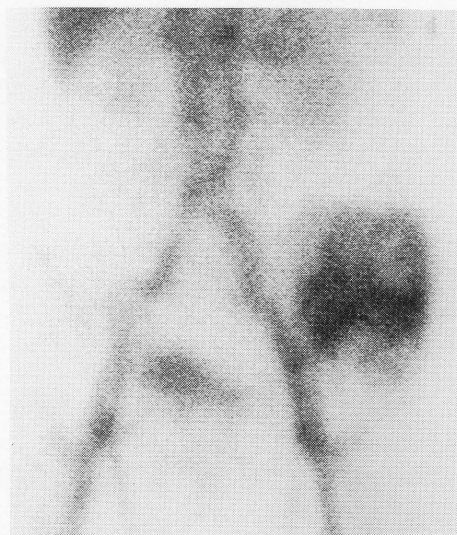Received July 4, 1996, revision accepted August 26, 1996.  
For reprint contact: Hitoya Ohta, M.D., Department of Laboratories Osaka Red Cross Hospital, 5-53 Fudegasaki-cho, Tennohji-ku, Osaka 543, JAPAN.



**Fig. 1** Pelvic radiograph showed a lytic lesion of the left ilium.

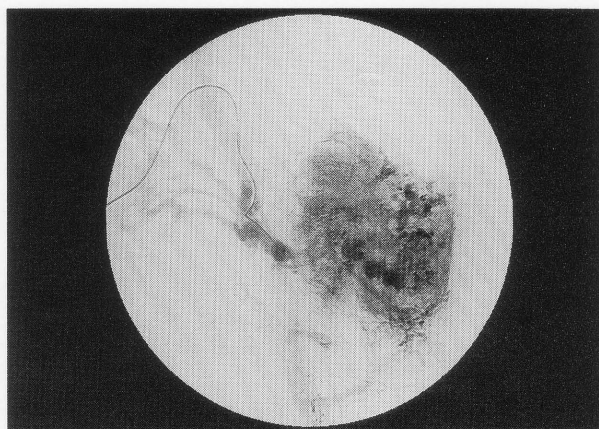


**Fig. 2** CT showed expansion and disintegration of bone structure in the left wing of the ilium with "sunburst" periosteal reaction, which is surrounded by a large tumor.

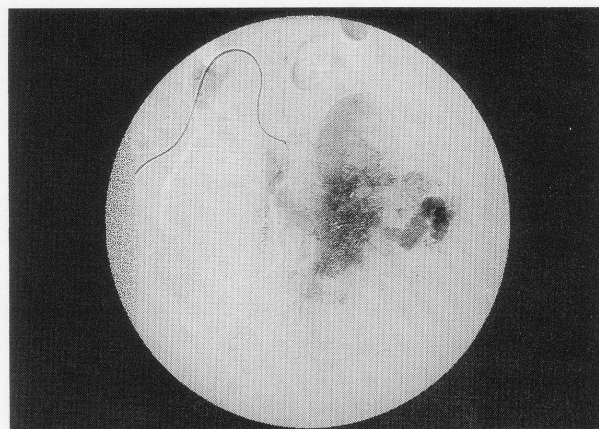


**Fig. 3**  $^{99m}\text{Tc}$ -HSA-D scintigraphy showed strong abnormal accumulation in the lesion.

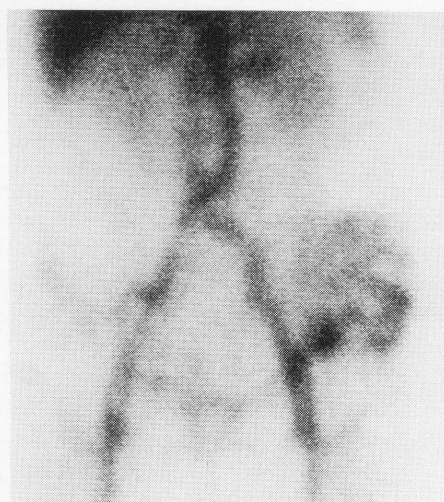
merus and ribs. Involvement of the bony pelvis accounts for about 10%.<sup>3,4</sup> Secondary MFH has been reported in Paget's disease, dedifferentiated chondrosarcoma, bone



**Fig. 4** Angiography showed marked hypervascularity, leaking of contrast material and arteriovenous shunts.

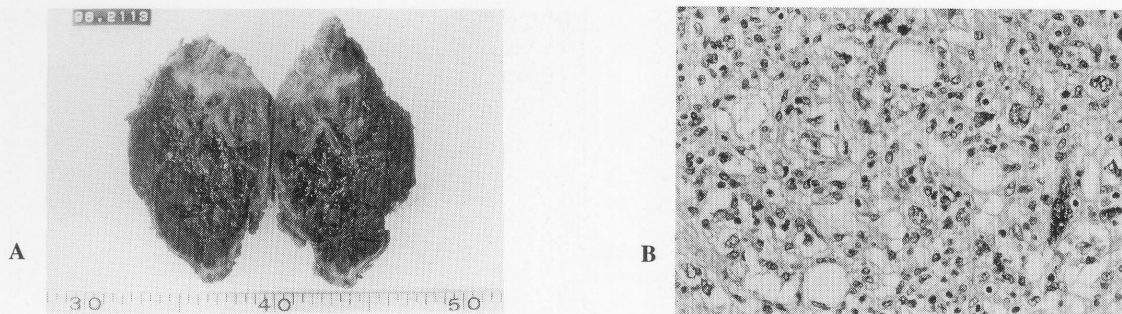


**Fig. 5** Follow-up angiography after radiation therapy and TAE showed reduced hypervascularity.



**Fig. 6** Follow-up  $^{99m}\text{Tc}$ -HSA-D scintigraphy showed markedly reduced accumulation in the lesion.

infarcts, and after irradiation.<sup>3,5</sup> Clinically, local pain and mass occur and pathological fractures are common.<sup>3,4</sup> The roentgenographic appearance is principally osteolytic.



**Fig. 7** Surgery revealed MFH of bone (Pleomorphic type). (A: Gross appearance of the tumor, B: H & E stain)

Sclerosis or calcification may rarely be seen. Periosteal bone formation is infrequent in the absence of a pathological fracture.<sup>3,4</sup> In the present case, pathological fracture was present. The angiographic appearance is usually hypervascular. A diffuse capillary blush, laking of contrast material and arteriovenous shunts may be present.<sup>6</sup>

Angiography is superior to scintigraphy as a means of morphological examination. Angiography also can do interventional treatment. But scintigraphy is less invasive and repeated examination is easy. In the present case, blood-pool scintigraphy was useful for surgeons to presuppose intraoperative blood loss. It is well known that hemangioma of the liver is described as a hot spot in the delayed image and can be distinguished from hepatocellular carcinoma.<sup>7</sup> In the present case, blood-pool scintigraphy suggested vascular tumor such as angiosarcoma, but surgery revealed MFH of the bone. The resected tumor was largely necrotic and fibrotic histopathologically. Reduction of the tracer accumulation in the lesion was thought to correspond to these histopathological findings and reflected the effectiveness of the therapy.

There is not a great deal of literature on blood-pool scintigraphic evaluation of bone tumors. In aneurysmal bone cyst, no concentration of <sup>99m</sup>Tc-HSA has been reported.<sup>8</sup>

In conclusion, a rare case of MFH of the ilium was presented. <sup>99m</sup>Tc-HSA-D accumulation in the lesion was recognized. Although tracer accumulation may be not specific for MFH, blood-pool scintigraphy was useful in the evaluation of the vascular characteristics of the tumor.

## ACKNOWLEDGMENTS

The authors thank Mr. Masahiro Takayama and Miss Kayo Sawada for their valuable assistance.

## REFERENCES

1. Weiss SW, Enzinger FM. Malignant fibrous histiocytoma. An analysis of 200 cases. *Cancer* 41: 2250-2266, 1978.
2. Dahlin DC, Unni KK. Bone tumors. *General aspects and data on 8542 cases*. 4th ed., Illinois, Charles C. Thomas Publisher, pp. 357-365, 1986.
3. Capanna R, Bertoni F, Bacchini P, Bacci G, Guerra A, Campanacci M. Malignant fibrous histiocytoma of bone. The experience at the Rizzoli Institute: Report of 90 cases. *Cancer* 54: 177-187, 1984.
4. Greenfield GB. *Radiology of bone diseases*. 5th ed. Philadelphia, Lippincott, pp. 628-630, 1990.
5. Huvos AG, Heilweil M, Bretsky SS. The pathology of malignant fibrous histiocytoma of bone. A study of 130 patients. *Am J Surg Pathol* 9: 853-871, 1985.
6. Hudson TM, Hawkins IF Jr, Spanier SS, Enneking WF. Angiography of malignant fibrous histiocytoma of bone. *Radiology* 131: 9-15, 1979.
7. Kudo M, Ikekubo K, Yamamoto K, Ibuki Y, Hino M, Tomita S, et al. Distinction between hemangioma of the liver and hepatocellular carcinoma: value of labeled RBC-SPECT scanning. *AJR* 152: 977-983, 1989.
8. Okuyama T, Suzuki H, Umehara I, Kuwabara Y, Suzuki S, Takagi M. Diagnosis of aneurysmal bone cyst of the mandible a report of two cases with emphasis on scintigraphic approaches. *Clin Nucl Med* 10: 786-790, 1985.