

## Tl-201 uptake and retention in a Warthin's tumor

Ali S. ARBAB, Kiyoshi KOIZUMI, Takao ARAI, Keiji TOYAMA and Tsutomu ARAKI

*Department of Radiology, Yamanashi Medical University*

We report scan findings of Tl-201 in a case of histologically proved Warthin's tumor. Dual isotopes acquisition was performed in a case of left parotid Warthin's tumor. Both early and delayed Tc-99m-pertechnetate (Tc-99m) images showed increased uptake at the tumor. Tl-201 scan also showed an increase of uptake on the early image and retention on the delayed image. The uptake ratios of Tl-201 were 3.0 (early) and 2.3 (delayed). Scan findings of Tl-201 in a case of Warthin's tumor were similar to those of Tc-99m, and the interpretation of Tl-201 images should be accompanied with Tc-99m images.

**Key words:** salivary gland, Warthin's tumor,  $^{99m}\text{TcO}_4^-$ ,  $^{201}\text{TlCl}$

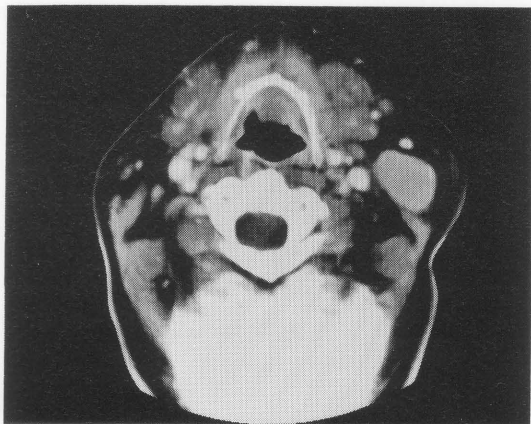### INTRODUCTION

THE DIAGNOSIS of Warthin's tumor by a nuclear medicine procedure is straight forward. Both early and delayed images, with or without lemon stimulation, by Tc-99m pertechnetate (Tc-99m) is quite suitable for diagnosing Warthin's tumor.<sup>1–3</sup> But diagnosis of other tumors of the salivary glands requires imaging by other radionuclides. To date, many radiopharmaceuticals have been used to detect salivary gland tumors.<sup>4–6</sup> Though gallium-67 (Ga-67) provided some promising results in the diagnosis of salivary gland disorders, it had certain limitations in differentiating benign from malignant tumors.<sup>7</sup> To overcome the limitations of Ga-67, we have changed our protocol for diagnosing salivary gland tumors to dual isotope (Tc-99m and Tl-201) single photon emission computerized tomography (SPECT) acquisition (early and delayed) with triple energy window (TEW) scatter correction method.<sup>8</sup> We also analyze the Tl-201 scan semiquantitatively. In a patient with left parotid gland tumor, both Tc-99m and Tl-201 images showed increased uptake on the early images and retention on the delayed images, and the final diagnosis was Warthin's tumor.

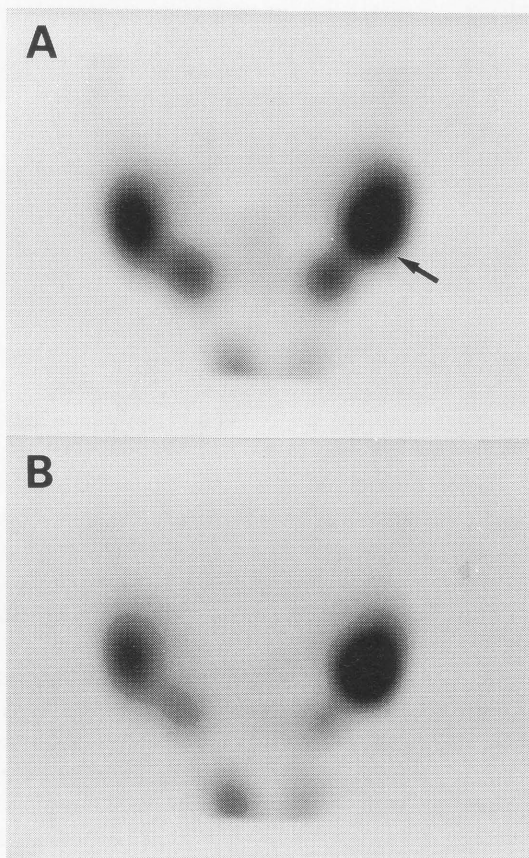
### CASE PRESENTATION

A 57-year-old female presented with left parotid gland swelling and the mass was moderately soft. Ultrasonography showed hypoechoic, and X-ray CT showed a hyperdense mass with enhancement (Fig. 1). She was referred to our department for further evaluation with radionuclides. According to our new protocol, she underwent dual isotope SPECT acquisition with the TEW method. After injection of Tc-99m (185 MBq) and Tl-201 (111 MBq), early and delayed images were acquired at 10 minutes and 3 hours, respectively, with a GCA-9300A/DI triple head gamma camera from Toshiba Co., Japan, using low-energy-high-resolution collimators. SPECT data were obtained by continuous acquisition for 20 minutes (5 rotations, 4 minutes/rotation) in a  $128 \times 128$  matrix at  $4^\circ$  step. The projection images were reconstructed using Butterworth and ramp filters but cut-off values were selected according to the count density in Tc-99m and Tl-201 images. To minimize the factors affected by the cut-off values of the filter in semiquantitative analysis, both early and delayed Tl-201 images were reconstructed with the same cut-off value. For image interpretation, matched slices of Tc-99m and Tl-201 were chosen. For semiquantitative analysis of Tl-201 images, a  $1 \times 1$  cm region of interest (ROI) was drawn over the tumor and the normal gland on matched slices. The count ratio of tumor to normal gland was calculated and referred to as the uptake ratio. Early Tc-99m images (Fig. 2A) showed increased

Received March 21, 1996, revision accepted April 24, 1996.  
For reprint contact: Ali Syed Arbab, M.B.B.S., Department of Radiology, Yamanashi Medical University, Tamaho-cho, Nakakoma-gun, Yamanashi 409–38, JAPAN.  
e-mail: saali@res.yamanashi-med.ac.jp.

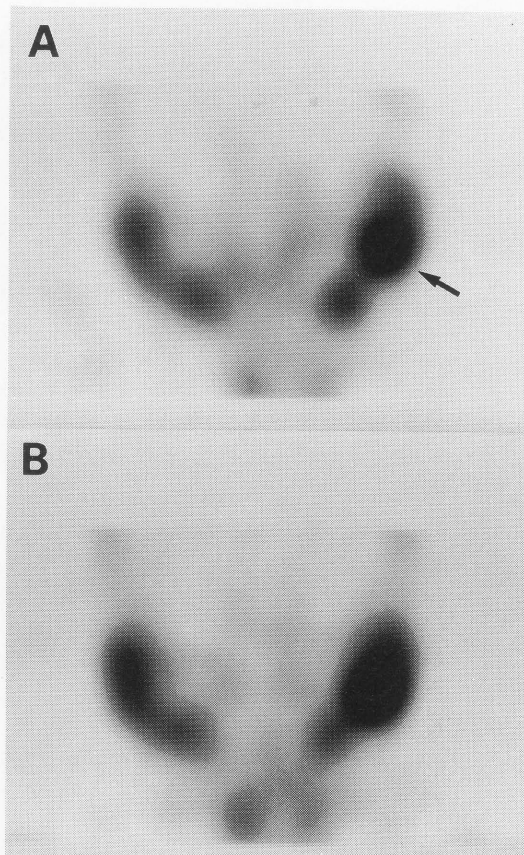


**Fig. 1** Contrast enhanced CT shows a an enhanced hyperdense soft tissue mass at the lower end of the left parotid gland.



**Fig. 2** Early (A) and delayed (B) Tc-99m images. Early image shows increased uptake at the lower end of the left parotid gland (arrow) with retention of Tc-99m activity at the corresponding site on delayed image.

uptake at the site of the mass in the left parotid gland with retention on delayed images (Fig. 2B). Tl-201 scan also showed increased uptake on early and retention on delayed images (Fig. 3). The early uptake ratio was 3.0 but delayed uptake ratios of Tl-201 became 2.3 due to retention of activity in the normal gland. We suggested a case

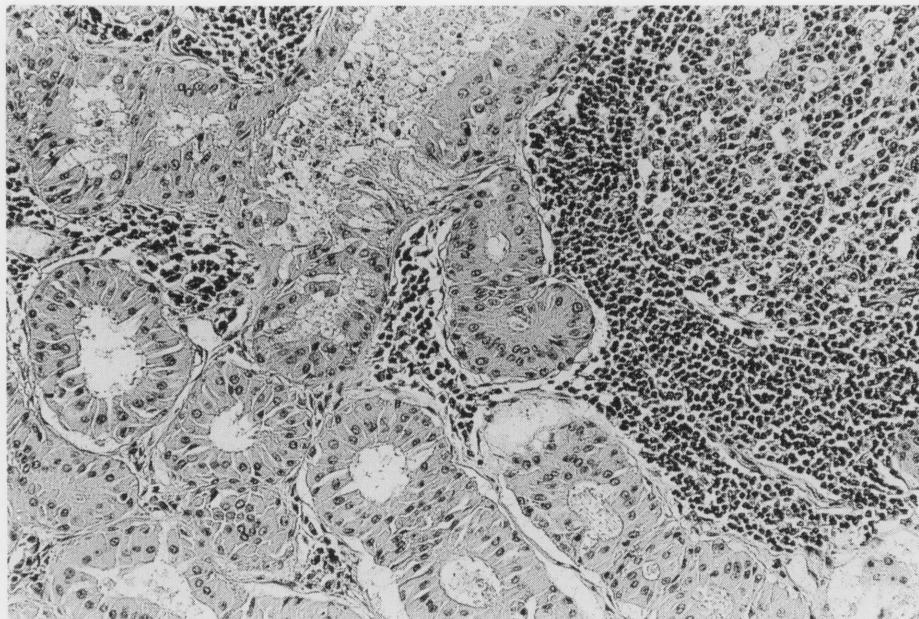


**Fig. 3** Scan findings of Tl-201. Early image (A) shows increased uptake (uptake ratio 3.0) at the lower end of the left parotid gland, the corresponding site of left parotid mass (arrow). Delayed image (B) shows retention of activity at the mass (uptake ratio 2.3).

of Warthin's tumor according to the Tc-99m scan findings. At surgery the tumor was  $3 \times 2.5$  cm in size and was confirmed histologically as a Warthin's tumor (Fig. 4).

## DISCUSSION

To date, many radionuclides have been used to detect salivary gland tumors.<sup>4-6</sup> Tc-99m scan provided very consistent results in the diagnosis of Warthin's tumor.<sup>1,2</sup> A combination of Tc-99m and Ga-67 has been used for salivary gland tumors though Ga-67 showed non-specificity in detecting malignant tumors.<sup>7</sup> Moreover, combined Tc-99m and Ga-67 scans is a time consuming study; that is, the patient has to come twice for the study. Tl-201 has shown potentiality in detecting malignant tumors in various organs.<sup>9-11</sup> To utilize the potentiality of Tl-201 for the detection of malignant tumors and to reduce the patient's and technologist's inconvenience, we changed our protocol to combined Tc-99m and Tl-201 dual isotope acquisition with the TEW method. With this new protocol, all scans are completed in 3 hours in a single day. Our preliminary study showed the advantage of Tl-201 over



**Fig. 4** The microphotograph of the Warthin's tumor. Note the characteristics columnar epithelium and lymphoid tissue.

Ga-67 in detecting salivary gland tumors regarding specificity and patient scheduling.<sup>12</sup> A phantom SPECT studies in our department showed that the cross talk of Tc-99m on Tl-201 images was 8.2% and that of Tl-201 on Tc-99m images was 2.2%.

The development of Warthin's tumor is believed to be from heterotropic salivary ducts within pre-existing lymphoid tissue.<sup>13</sup> The uptake and retention of Tc-99m in Warthin's tumor may be explained by the Warthin's tumor cells retaining their capacity to concentrate Tc-99m but not being able to secrete it, since Warthin's tumor does not communicate with the gland's ductal system.<sup>3,13</sup> The uptake and retention of Tl-201 may be due to increased cell membrane potential resulting from increased mitochondrial density<sup>13</sup> and thereby increased metabolic activity. Increased uptake of Tl-201 was observed in a tumor cell line with increased mitochondrial density.<sup>14</sup>

Though Tc-99m images alone may be enough for tentative diagnosis of Warthin's tumor, Tl-201 scan was performed in this case according to our clinical protocol. Increased uptake with retention of Tl-201 must be interpreted carefully along with Tc-99m scan results. If a Tc-99m scan also shows increased uptake with retention, a Warthin's tumor is most likely. If a Tc-99m scan provides cold or photopenic results, tumors other than Warthin's tumor should be considered.

## REFERENCES

1. Sostre S, Medina L, De Arellano GR. The various scintigraphic patterns of Warthin's tumor. *Clin Nucl Med* 12: 620-626, 1987.
2. Liu RS, Yeh SH, Yen TC, Hsu DF. Salivary scintigraphy with vitamin C stimulation: an aid in differentiating unilateral parotitis from Warthin's tumor. *Eur J Nucl Med* 16: 689-691, 1990.
3. Wienstein GS, Harvey RT, Zimmer W, Ter S, Alavi A. Technetium-99m pertechnetate salivary gland imaging. Its role in the diagnosis of Warthin's tumor. *J Nucl Med* 35: 179-183, 1994.
4. Higashi T, Shindo J, Everhart R, Mori Y, Kasai H, Kogure S, et al. Technetium-99m pertechnetate and Gallium-67 imaging in salivary gland disease. *Clin Nucl Med* 14: 504-514, 1989.
5. Kairemo KJA, Hopsu EVM. Diagnosis of tumors of the parotid gland with anti-CEA immunoscintigraphy. *AJR* 154: 1259-1262, 1990.
6. Keyes JW, Harkness BA, Greven KM, Williams DW, Watson NE, McGuirt WF. Salivary gland tumors: pretherapy evaluation with PET. *Radiology* 192: 99-102, 1994.
7. Arbab AS, Koizumi K, Uchiyama G, Arai T. The usefulness and limitations of combined Tc-99m pertechnetate and Ga-67 citrate imaging of salivary gland disorders. *Clin Nucl Med* 20: 5-12, 1995.
8. Ichihara T, Ogawa K, Motomura N, Kubo A, Hashimoto S. Compton scatter compensation using the triple-energy window method single- and dual-isotopes SPECT. *J Nucl Med* 34: 2216-2221, 1993.
9. Elgazzar AH, Fernandez-Ulloa M, Silberstein EB. Tl-201 as a tumour-localizing agent: current status and future considerations. *Nucl Med Comm* 14: 96-103, 1993.
10. Caluser C, Macapinlac H, Healey J, Ghavimi F, Meyers P, Wollner N, et al. The relationship between thallium uptake, blood flow, and blood pool activity in bone and soft tissue tumors. *Clin Nucl Med* 17: 565-572, 1992.
11. Arbab AS, Koizumi K, Arai T, Mera K, Miyazaki A, Otaka

- M. Incidental detection of breast cancer during Tl-201 myocardial SPECT study. *Ann Nucl Med* 9: 143–144, 1995.
12. Arbab AS, Koizumi K, Hiraike S, Arai T, Mera S. Will combined Tc-99m-Tl-201 scans replace Tc-99m-Ga-67 scans for the salivary gland disorder (abs.)? *J Nucl Med* 36: 220p, 1995.
  13. Chapnik JS. The controversy of Warthin's tumor. *Laryngoscope* 93: 695–716, 1983.
  14. Arbab AS, Koizumi K, Araki T. Comparison of uptake mechanisms of Tc-99m-tetrofosmin, Tc-99m-MIBI and Tl-201 in tumor cell lines (abs.). *KAKU IGAKU (Jpn J Nucl Med)* 32: 892, 1995.