

## Differences between $^{99m}\text{Tc}$ -DTPA and $^{99m}\text{Tc}$ -MAG3 captopril renographies in renovascular hypertension

Kazuo ITOH,\* Yutaka MATSUI,\*\* Chietsugu KATO,\* Takashi MOCHIZUKI\*  
and Akira KITABATAKE\*\*

*\*Departments of Nuclear Medicine and \*\*Cardiovascular Internal Medicine,  
Hokkaido University School of Medicine*

Captopril renography (CRS) with  $^{99m}\text{Tc}$ -DTPA and  $^{99m}\text{Tc}$ -MAG3 was performed on a 21-year-old woman with renovascular hypertension due to right renal artery stenosis caused by fibromuscular dysplasia. In the affected kidney, the renogram pattern was substantially changed with  $^{99m}\text{Tc}$ -DTPA and  $^{99m}\text{Tc}$ -MAG3 following the administration of captopril, and the quantitated renal uptake indicating individual renal function was significantly decreased in  $^{99m}\text{Tc}$ -DTPA and slightly decreased in  $^{99m}\text{Tc}$ -MAG3. In the contralateral normal kidney, the renogram showed some minor changes with both radioagents, while the quantitated renal uptake was significantly decreased with  $^{99m}\text{Tc}$ -DTPA and substantially increased with  $^{99m}\text{Tc}$ -MAG3. The combined use of physiologically different renal agents  $^{99m}\text{Tc}$ -DTPA and  $^{99m}\text{Tc}$ -MAG3 is helpful in investigating hemodynamic and functional changes in the stenosed kidney as well as the normal kidney in RVH.

**Key words:** captopril renography,  $^{99m}\text{Tc}$ -DTPA,  $^{99m}\text{Tc}$ -MAG3, renovascular hypertension, fibromuscular dysplasia

### INTRODUCTION

CAPTOPRIL RENOGRAPHY (CRS) is a non-invasive and excellent technique to use in the differential diagnosis of renovascular hypertension (RVH) and the indication of therapeutic outcome.<sup>1–10</sup>  $^{99m}\text{Tc}$ -DTPA measuring of the glomerular filtration rate is most common in clinical use and may be theoretically the best choice.<sup>3,11</sup> CRS with tubular radioagents such as  $^{131}\text{I}$ -hippurate (OIH) and  $^{99m}\text{Tc}$ -MAG3 also provides high diagnostic accuracy corresponding to that of  $^{99m}\text{Tc}$ -DTPA.<sup>1,8,9,12</sup> Although these renal radioagents are not identical in renal handling, CRS diagnostic criteria for the renin-dependent kidney depend on qualitative change in the renogram pattern and quantitative evaluation of transit time.

The clinical use of  $^{99m}\text{Tc}$ -MAG3 for renovascular hypertension is still new and limited,<sup>8,9,12</sup> in comparison with that of  $^{99m}\text{Tc}$ -DTPA. In this paper, we present a case of RVH, in which CRS with  $^{99m}\text{Tc}$ -DTPA and  $^{99m}\text{Tc}$ -MAG3

was useful in investigating hemodynamic and functional changes in the stenosed kidney and the contralateral normal one.

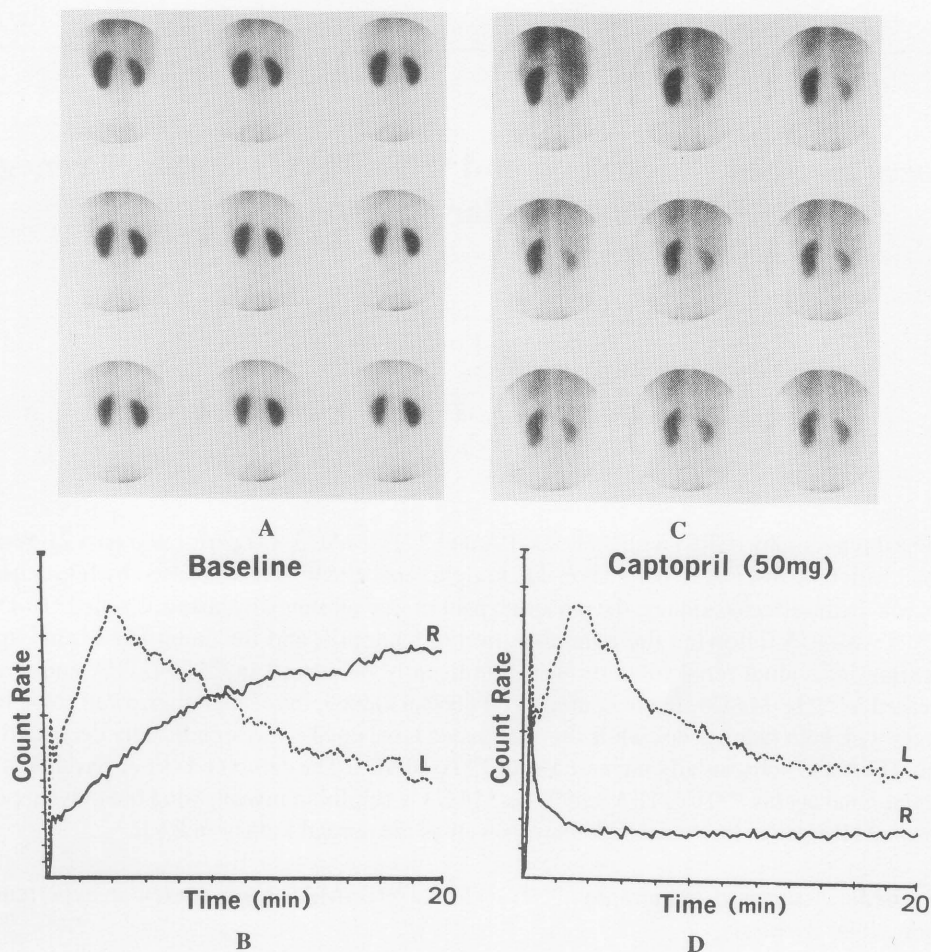
### CASE REPORT

A 21-year-old woman was admitted complaining of several sudden onsets of headache, nausea and vertigo in the previous year. Hypertension (approximately 200 mmHg maximum and 140 mmHg minimum) was then first pointed out by a physician. About 4 months later, she consulted a cardiovascular physician because of repeated symptoms. Hypertension (200 mmHg maximum and 120 mmHg minimum) was again indicated and some enlargement of the adrenal gland was detected by CT scan. Because symptoms persisted during the day, she was recommended to undergo further tests at our hospital.

On admission, she looked well. Her body weight was 50 kg and height 155 cm. Blood pressure (BP) in the right arm was 174 mmHg maximum and 126 mmHg minimum in the sitting position. No significant difference was observed between the BP in the upper arm and lower extremities. No bruit was auscultated in the abdomen. The chest radiograph was normal and ECG showed high voltage suggestive of the left ventricular hypertrophy.

Received December 14, 1995, revision accepted January 25, 1996.

For reprint contact: Kazuo Itoh, M.D., Department of Nuclear Medicine, Hokkaido University School of Medicine, Kita-15, Nishi-7, Kita-ku, Sapporo 060, JAPAN.



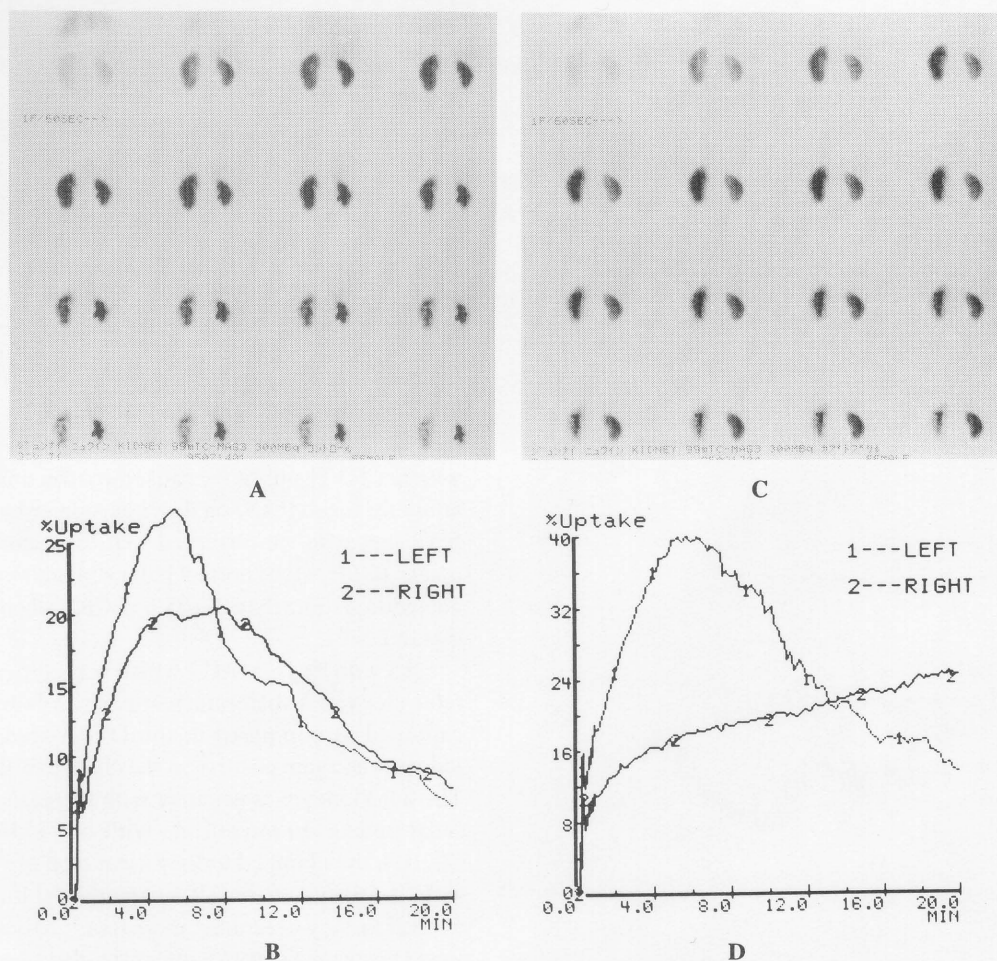
**Fig. 1**  $^{99m}\text{Tc}$ -DTPA sequential images (every 2 min) and renogram. Sequential images (A) in the baseline study demonstrate the small size and decreased parenchymal uptake of the right kidney, and the renogram (B) in the right kidney is prolonged in parenchymal transit of the  $^{99m}\text{Tc}$ -DTPA. The left kidney is normal. Sequential images (C) and the renogram (D) in captopril study show marked reduction of the renal parenchymal uptake, very poor function and dramatic change of the renogram in the right kidney. No significant drop of parenchymal uptake is not visible in the left kidney but there are some minor changes in the renogram: relative decrease in the peak activity after captopril when compared to the first pass activity. Although these findings may explain substantial qualified renal uptake in the left kidney, they do not indicate positive response to captopril.

Laboratory tests showed hypopotassemia (3.1 Eq/ml) and increased plasma activity of norepinephrine (451 pg/ml), renin (87.5 ng/ml) and aldosterone (3,251 pg/ml). No other abnormality was observed. Radiological examinations such as CT scan, MRI and digital subtraction angiography of the renal artery showed no abnormality in the adrenal glands, kidneys or renal arteries. There was no family history of hypertension.

During the admission, serum norepinephrine became lower than the normal range (90–420 pg/ml). On the other hand, plasma renin activity and the aldosterone level were within normal range or slightly increased.

Administration of only ACE inhibitors stopped for 2 days before the scintigraphy. CRS with  $^{99m}\text{Tc}$ -DTPA and  $^{99m}\text{Tc}$ -MAG3 was performed a week apart according to the following two-day protocol: 1) the baseline study was

carried out at first, 2) 3 days later, renography was repeated 1 hour after the oral administration of captopril (50 mg). The following scintigraphic protocol was the same in all studies: 1) a bolus of the radionuclide (370 MBq of  $^{99m}\text{Tc}$ -DTPA and 300 MBq of  $^{99m}\text{Tc}$ -MAG3) was injected into an antecubital vein 30 minutes after hydration; 2) sequential renal images were acquired by means of a gamma camera (Searle LFOV in DTPA study and Toshiba GCA 601A in MAG3) and a dedicated computer at the rate of one frame every 10 sec for 20–30 minutes in the supine position; 3) After regions of interests were assigned over a whole kidney and background region, the background-subtracted renogram was obtained; 4) the net renal counts accumulated at 2–3 min in DTPA and 1.5–2.5 min in MAG3 after injection, expressed as a fraction of the injected dose (%ID), were calculated for each



**Fig. 2**  $^{99m}\text{Tc}$ -MAG3 sequential images (every 1 min) and renogram. Sequential images (A) in BS demonstrate the small size and somewhat decreased parenchymal uptake of the right kidney, which are the same as Figure 1. The renogram (B) in the right kidney shows prolonged transit time, which must be accounted for by urinary retention excreted into the pelvis. Sequential images (C) in captopril study demonstrate no substantial changes in parenchymal uptake in both kidneys, but show prolonged parenchymal transit in the right kidney. The post-captopril renogram (D) shows substantial change of the renogram pattern in the right kidney and slight differences from the baseline study in the time to the peak count and in the peak time and the residual activity in the left kidney. The renogram pattern of the left kidney, however, is appreciated as normal.

kidney as an index of the glomerular filtration rate or effective renal plasma flow according to the modified Gates' method.<sup>10,13,14</sup> The renogram in the baseline study and CRS was classified into 6 patterns according to the method used in our previous report.<sup>15</sup>

CRS with  $^{99m}\text{Tc}$ -DTPA demonstrated dramatic response of the right kidney suggestive of hemodynamically significant renovascular disease (Fig. 1). The renogram pattern converted the pattern IIa (prolonged peak time) in the baseline study to V (non-functioning) in CRS. In addition, the left kidney showed some minor changes in the renogram after captopril. The renal uptake per injected dose (%ID) also decreased more in the right kidney than that in the left (Table 1). These results led us to consider that RVH might be due to bilateral renal artery stenosis according to our

previously reported criteria.<sup>10</sup>  $^{99m}\text{Tc}$ -MAG3 captopril renography was indicated for assessing pathophysiological changes in both kidneys. The responses of the two kidneys to captopril with  $^{99m}\text{Tc}$ -MAG3 were different from those for  $^{99m}\text{Tc}$ -DTPA (Fig. 2). The difference in the renogram pattern in the affected kidney was evident and the change in the quantitated renal uptake decreased slightly. There were some minimal changes in the renogram pattern of the contralateral kidney and a marked increase in the quantitated renal uptake. Contrast angiography performed a week after the radionuclide studies demonstrated the right renal artery stenosis and no stenosis of the left renal artery (Fig. 3). The BP gradually reverted to normal within a week without antihypertensives following the angioplasty.

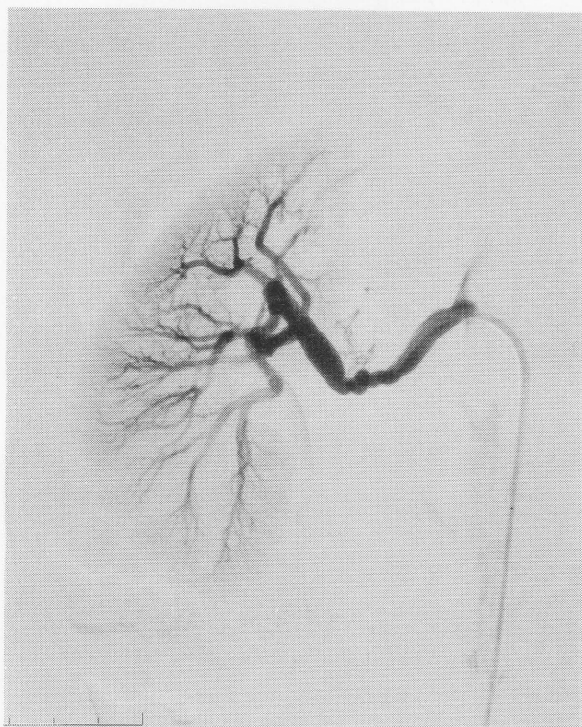


**Table 1** Comparison between captopril renography using  $^{99m}\text{Tc}$ -DTPA and  $^{99m}\text{Tc}$ -MAG3

	Absolute renal uptake (%ID)	Split renal function (%)		Renogram pattern		CRR (%)	
		R	L	R	L	R	L
DTPA							
BS	19.60	29	71	IIb	I		
CRS	10.30	17	83	V	I	-65	-30
MAG3							
BS	32.11	44	56	IIa	I		
CRS	39.05	35	65	IIb	I	-3	41

BS: baseline study, CRS: captopril renography.

CRR: captopril reduction rate =  $(\text{split renal uptake}_{\text{CRS}} - \text{split renal uptake}_{\text{BS}}) / \text{split renal uptake}_{\text{BS}} \times 100 (\%)$



**Fig. 3** Selective angiogram of the right renal artery. The photograph reveals the beaded stenosis of the right renal artery at a mid-portion. This finding suggests the stenosis is due to fibromuscular dysplasia.

## DISCUSSION

It is well known that the affected kidney in RVH shows signs of hemodynamically significant changes after the administration of ACE inhibitors.<sup>3,16</sup> These changes are observed in CRS with  $^{99m}\text{Tc}$ -DTPA as changes in the renogram pattern, decreased renal uptake (GFR), different split renal function, prolonged time to the peak count, and prolonged renal transit time.<sup>1-10</sup> In the present case, CRS with  $^{99m}\text{Tc}$ -DTPA fulfilled most of our positive criteria for the renin dependency in the right kidney in RVH.<sup>10</sup> The left kidney showed some minor changes in the renogram and a significant reduction of the quantitated renal uptake. In view of these findings we wondered

whether RVH might be caused by the unilateral renal artery stenosis (RAS) on the right side or by the bilateral RAS, because we observed that the quantitated renal uptake (GFR) in the normal kidney in unilateral RVH was not reduced more than 20–25% in CRS when compared to that in BS.<sup>10</sup>

CRS with  $^{99m}\text{Tc}$ -MAG3 which was carried out a week later showed a different response in both kidneys to captopril as compared to the DTPA study. The right kidney was again positive in the change of the renogram. The left kidney was negative with increased quantitated renal uptake. In model rats with one kidney clamped (2K1C), the clamped kidney clearance of  $^{99m}\text{Tc}$ -MAG3 and  $^{131}\text{I}$ -OIH decreases after captopril inhibition, and the normal kidney clearance increases.<sup>17</sup> Miyamori et al.<sup>18</sup> found no change in ERPF after captopril administration in unilateral and bilateral renal artery stenosis, but an increase in healthy persons. These observations indicate that scintigraphic findings in the current patient are compatible with the unilateral renovascular hypertension, ischemic kidney on the right side and normal on the left.

$^{99m}\text{Tc}$ -DTPA seems to be a more theoretically preferable choice in CRS for investigating RVH than  $^{99m}\text{Tc}$ -MAG3, although it will be decided in the near future which of the radioagents,  $^{99m}\text{Tc}$ -DTPA and  $^{99m}\text{Tc}$ -MAG3, has higher diagnostic accuracy in ACE inhibitors-enhanced renography.<sup>11</sup> Combined use of both radioagents of physiologically different properties in the kidney cannot be recommended for routine practice, but may be useful in the pathophysiological investigation of RVH. Scintigraphic findings and renogram responses in CRS in RVH have been reported to vary. Different responses in CRS when using physiologically different radioagents may be observed in a patient with RVH. Combined study with these radioagents may be helpful in investigating autoregulation in the affected kidney as well as the contralateral normal kidney in RVH.

## REFERENCES

1. Sfukianakis GN, Jaffe DJ, Bourgoignie JJ, et al. Single dose captopril renography in diagnosis of renovascular hyper-

- tension. *J Nucl Med* 28: 1383–1392, 1987.
2. Mann SJ, Pickering TG, Sos TA, et al. Captopril renography in the diagnosis of renal artery stenosis: accuracy and limitations. *Am J Med* 90: 30–40, 1991.
3. Nally JV Jr, Black HR. State-of-the-art review: captopril renography-pathophysiological considerations and clinical observations. *Semin Nucl Med* 22: 85–97, 1992.
4. Fommei E, and the European Multicentre Study Group. Captopril radionuclide test in renovascular hypertension: a European multicentre study. *Eur J Nucl Med* 20: 617–623, 1993.
5. Elliot WJ, Martin WB, Murphy MB. Comparison of two noninvasive screening tests for renovascular hypertension. *Arch Inter Med* 153: 755–764, 1993.
6. Meier GH, Sumpio B, Serato JF, Black HR, Gusberg RJ. Captopril renal scintigraphy: a new standard for predicting outcome after renal revascularization. *J Vasc Surg* 17: 280–287, 1993.
7. Shamlou KK, Drane WE, Hawkins IF, Fennell RS III. Captopril renography and the hypertensive renal transplantation patient: a predictive test of therapeutic outcome. *Radiology* 190: 153–159, 1994.
8. Dondi M, Monetti N, Fanti S, Marchetta F, Cordelli C, Zagni P, et al. Use of technetium-99m-MAG3 for renal scintigraphy after angiotensin-converting enzyme inhibition. *J Nucl Med* 32: 424–428, 1991.
9. Kahn D, Ben-Haim S, Bushnell DL, Madsen MT, Kirchner PT. Captopril-enhanced <sup>99m</sup>Tc-MAG3 renal scintigraphy in subjects with suspected renovascular hypertension. *Nucl Med Comm* 15: 515–528, 1994.
10. Itoh K, Tsukamoto E, Nagao K, Nakada K, Kanegae K, Furudate M. Captopril renoscintigraphy with Tc-99m DTPA in patients with suspected renovascular hypertension: prospective and retrospective evaluation. *Clin Nucl Med* 18: 463–471, 1993.
11. Blaufox MD. Captopril renography, considerations in the selection of radiopharmaceuticals, provocative agents, and hypertensive subjects. *Am J Hypertens* 4: 675S–677S, 1991.
12. Taylor A Jr, Martin LG. The utility of <sup>99m</sup>Tc-mercaptoacetyl-triglycine in captopril renography. *Am J Hypertens* 4: 731S–736S, 1991.
13. Gates GF. Glomerular filtration rate: Estimation from fractional renal accumulation of <sup>99m</sup>Tc-DTPA (stannous). *Am J Roentgenol* 138: 565–570, 1982.
14. Itoh K, Tsukamoto E, Kakizaki H, Nonomura K, Furudate M. Comparative study of renal scintigraphy with <sup>99m</sup>Tc-mercaptoacetyl-triglycine and <sup>123</sup>I-orthoiodohippurate. *Nucl Med Comm* 14: 644–652, 1993.
15. Itoh K, Kato C, Shiga T. Expressing kidney uptake during <sup>99m</sup>Tc-MAG3 renography in terms of administered activity. *Nucl Med Comm* 16: 504–508, 1995.
16. Pickering TG. Renovascular hypertension: etiology and pathophysiology. *Semin Nucl Med* 19: 79–88, 1989.
17. Lee H-B, Blaufox MD. Technetium-99m MAG3 clearances after captopril in experimental renovascular hypertension. *J Nucl Med* 30: 666–671, 1989.
18. Miyamori I, Yasuhara S, Takedo Y, et al. Effects of converting enzyme inhibition on split renal function in renovascular hypertension. *Hypertension* 9: 415–421, 1986.