

## A mural thrombus of an infrarenal aortic aneurysm demonstrated as photon deficiency in a radionuclide study

W.J. SHIH,\* C.H. TSAI,\*\* A. KAZMERS,\* J.K. LEE,\*\* K. GROSS,\* V. STIPP,\*  
C. PULMANO\* and S. MAGOUN\*

*\*VAMC and University of Kentucky Medical Center, USA  
and \*\*China Medical College, Taichung Taiwan, Republic of China*

Radionuclide angiogram (RNA) and aortogram may underestimate external aneurysmal diameter. Photon deficient areas are not uncommon along the abdominal aortic aneurysm (AAA) on RNA. To determine whether or not photon deficient areas along the aneurysm could represent a large thrombus, we studied radionuclide aortic angiography in thirty-eight patients during a preoperative cardiac gated study. All the patients (men, ages from 60 to 78) had CT, US, and/or aortogram for comparison. The presence of a thrombus was determined by CT, US, and/or surgical findings. Twelve of 38 (32%) patients' RNA and blood pool images showed photon deficient areas along the aneurysmal walls having a large concentric or eccentric thrombus of the AAA. A large photon deficient area could be detected along the narrowing calibre of the aorta lumen. This finding results from a large mural thrombus being interposed between the left or right bowel/mesentery activity and the activity of the aneurysms functioning patent lumen. We concluded that a photon deficient area along an infrarenal aortic aneurysm may indicate a large thrombus of either eccentric or concentric type within an AAA.

**Key words:** radionuclide angiogram, abdominal aortic aneurysm, photon deficient area, concentric/eccentric thrombus

### INTRODUCTION

AN ANEURYSM of the aorta is defined as a localized dilation of a segment of the aorta compared with the size above and below.<sup>1</sup> Abdominal aortic aneurysms (AAA) tend to form in the infrarenal aorta. Atherosclerosis is the principal pathologic process affecting large and medium-sized arteries.<sup>1,2</sup> Dilatations of an aortic aneurysm include all layers of the arterial wall, and may involve local areas or the entire aortic circumference.<sup>3</sup> In addition to degeneration of the abdominal aortic wall, a thrombus may form in an AAA. Since the prevalence of abdominal aortic aneurysm in men aged 65–75 yrs is 5.4%,<sup>4</sup> it is not infrequent to demonstrate abdominal aortic aneurysm incidentally in Tc-99m DTPA<sup>5,6</sup> and Tc-99m RBC blood pool<sup>7,8</sup> studies. Radionuclide study of an aortic aneurysm usually reveals ectasia, tortuosity or balloon-like dilatations (Figs. 1 and

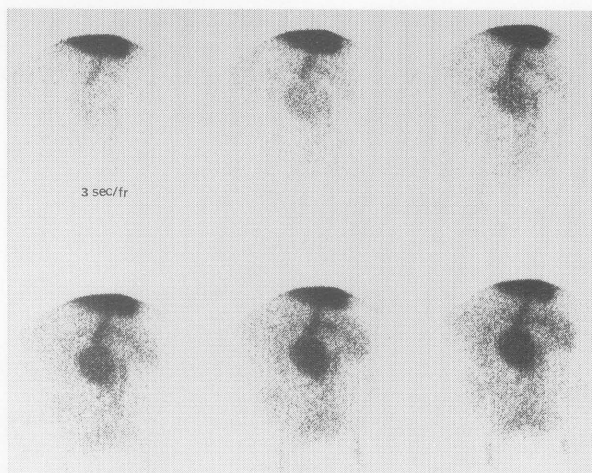
2). Occasionally we observed a photon deficient area along the abdominal aortic aneurysms.<sup>9</sup> To determine whether or not the photon deficient areas along the aneurysm represented a large thrombus, we conducted this investigation.

### MATERIALS AND METHODS

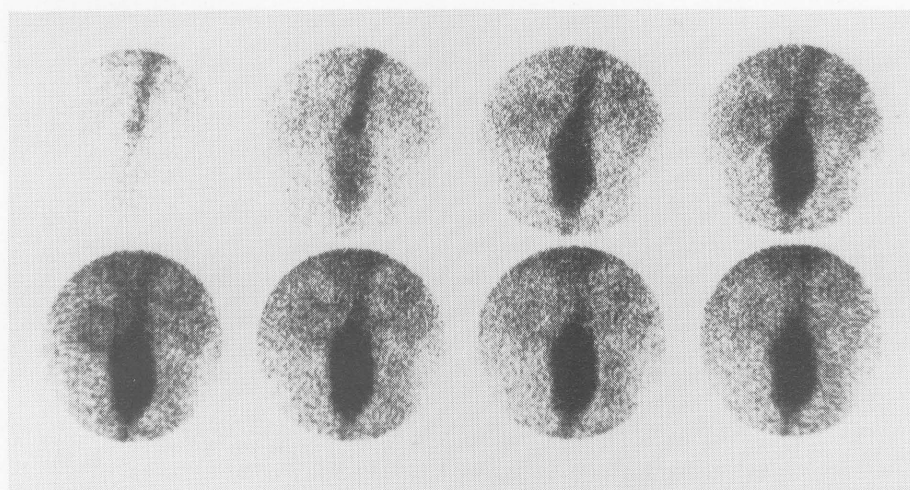
This was a retrospective study: All the male patients, aged from 60 to 78 years, were referred for evaluation of radionuclide gated cardiac function for preoperative peripheral vascular surgery, pre-chemotherapy/follow-up chemotherapy and/or coronary artery disease. Thirty-eight patients were included and met the following criteria: (1) available radiographics (CT, US, and/or aortogram) revealing an abdominal aortic thrombus and/or thrombus found at aortic graft surgery; (2) the interval between radionuclide angiogram and radiographics or surgical results was within three weeks; (3) CT, US, aortogram and/or surgical findings correlated with the radionuclide study. Our one previously reported case was not included in the study.<sup>9</sup>

Received September 6, 1995, revision accepted November 20, 1995.

For reprint contact: Dr. Wei-Jen Shih, Nuclear Medicine Service, VAMC, Lexington, KY 40511, USA.



◀ **Fig. 1** A 74-yr-old man (5776) with known pleural effusion, congestive heart failure, and abdominal aneurysm. Radionuclide first pass study shows slow progression of tracer through cardiac chamber to aorta, and a large balloon-like dilatation in the distal abdominal aorta inferiorly.



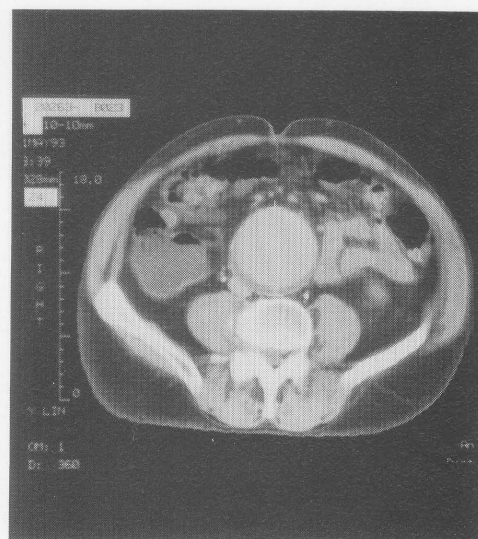A

**Fig. 2** A 76-yr-old man (HT, 5643) with known abdominal aneurysm: First pass flow study with 5 second per frame (A) shows marked dilatation of middle and distal segments of the abdominal aorta. Note that there is no photopenic area along the aorta. CT of the abdomen (B) shows dilated aorta with little thrombus along the posterior margin.

After intravenous injection of one vial of Technescan PYP (each vial containing a mixture of 3.8 mg stannous chloride dihydrate, 11.9 mg sodium pyrophosphate) each patient was placed in the supine position under a (Siemens) portable gamma camera covering the abdomen and pelvis and imaged every 5 seconds for one minute after IV injection of 740–1,110 MBq (20–30 mCi) of Tc-99m pertechnetate. Blood pool images were obtained immediately after the radionuclide angiography. The findings of the radionuclide angiogram and blood pool images were correlated with radiographic studies, including computer tomography (CT), ultrasonography (US), contrast angiogram and/or surgical findings.

## RESULTS

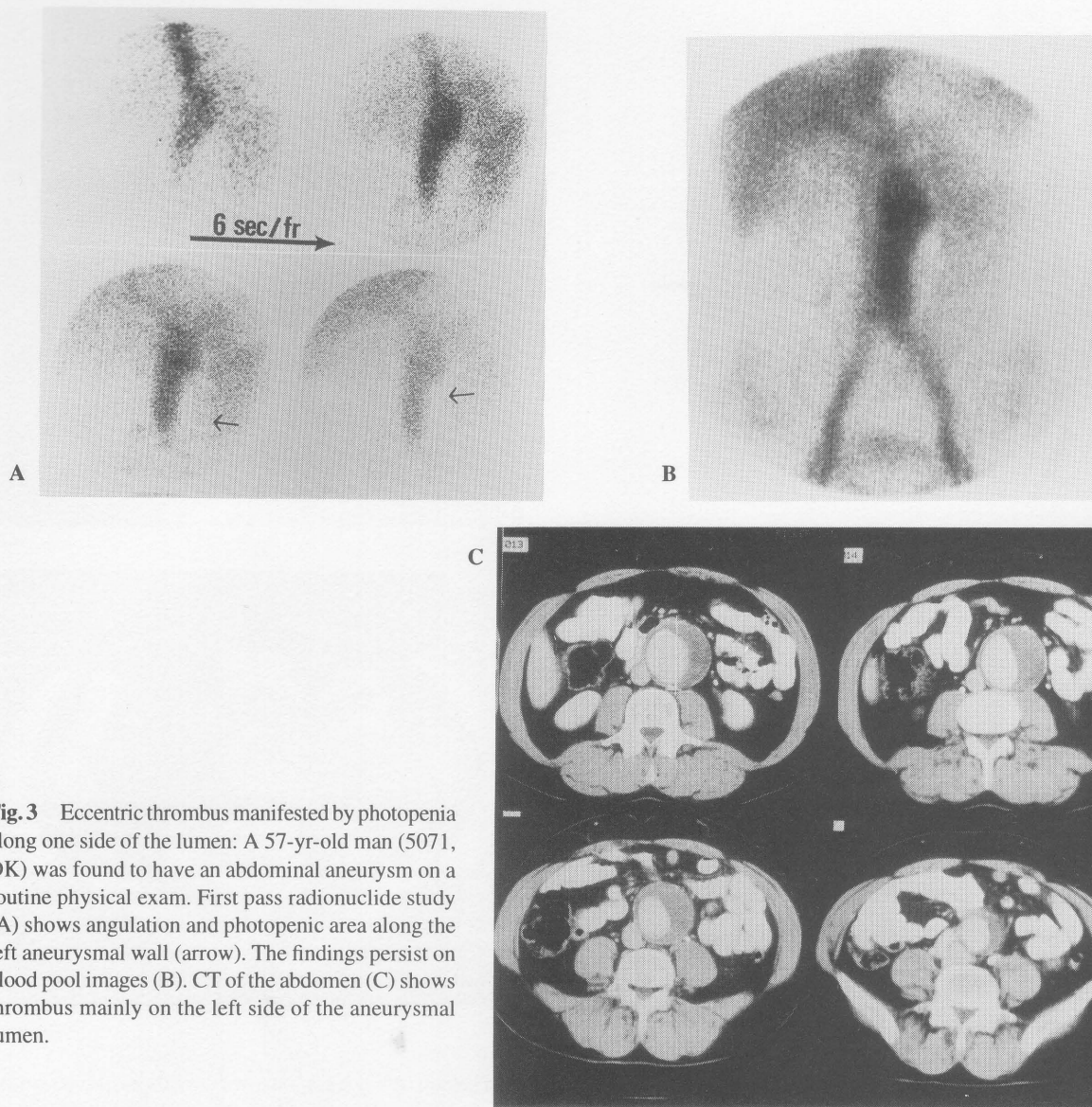
A typical infrarenal aortic aneurysm in a radionuclide angiogram is shown in Figures 1 and 2. The presence of the thrombus in 38 men with infrarenal abdominal aortic aneurysms was determined by CT, US and/or surgical results. Twelve of 38 (32%) patients had a large photon deficient area; these photon deficient areas were divided



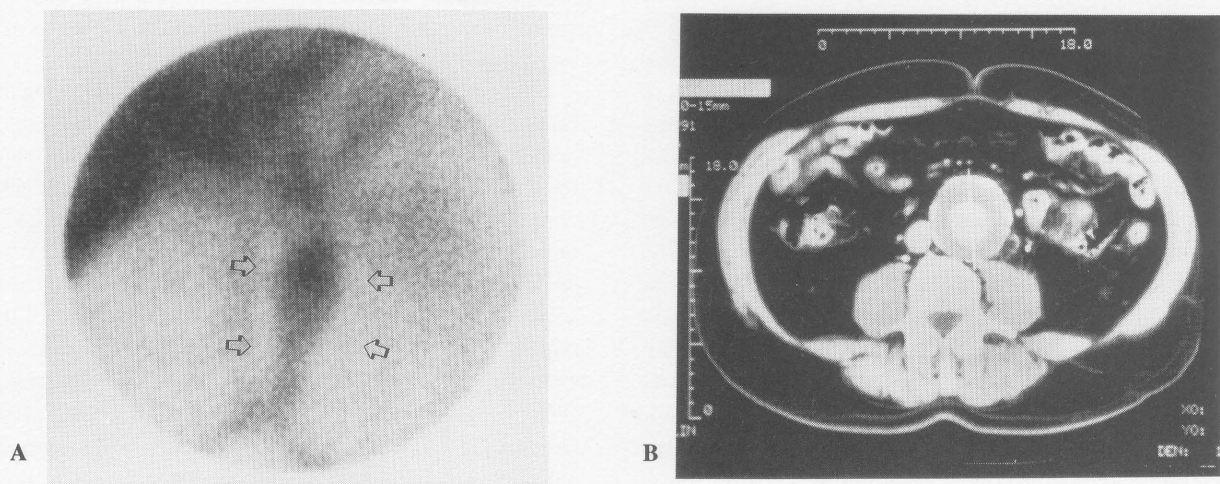
B

into two patterns, concentric and eccentric thrombi. Figure 3 shows a photon deficient eccentric thrombus along one side of the aneurysmal wall. Radionuclide studies of a concentric thrombus are shown in Figures 4A and 5A.

Twenty-eight patients (68%) who actually had a thrombus were not shown on radionuclide studies; these false

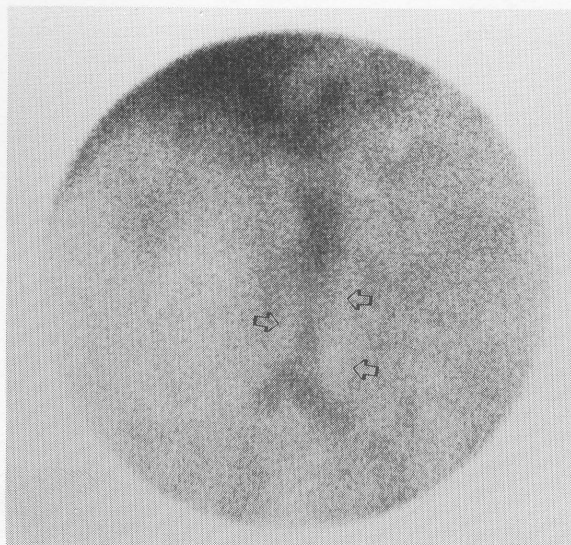


**Fig. 3** Eccentric thrombus manifested by photopenia along one side of the lumen: A 57-yr-old man (5071, DK) was found to have an abdominal aneurysm on a routine physical exam. First pass radionuclide study (A) shows angulation and photopenic area along the left aneurysmal wall (arrow). The findings persist on blood pool images (B). CT of the abdomen (C) shows thrombus mainly on the left side of the aneurysmal lumen.

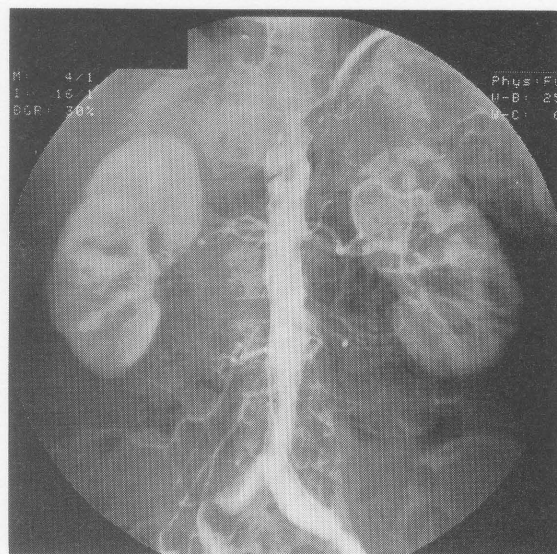


**Fig. 4** Concentric thrombus: A 70-yr-old man (7973, NL) with abdominal aneurysm: Blood pool images (A) show photopenic area along both sides of aneurysmal walls. CT of the abdomen (B) shows centrally opacified patent lumen surrounded by concentric thrombus.

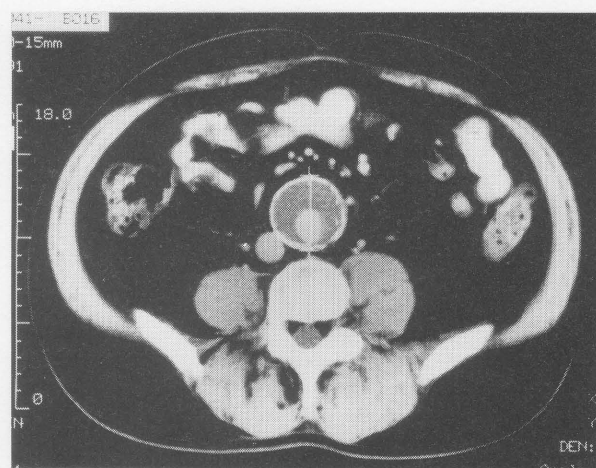




A



B



C

**Fig. 5** Concentric thrombus manifested by photopenic area along both sides of aneurysmal (4494) wall: Blood pool image (A) shows photopenic area along the aneurysmal wall. Aortogram (B) shows normal calibre of opacified lumen. CT of the abdomen (C) shows opacified lumen of the aneurysm which is located in the eccentrically posterior aspect of the aneurysm, and the rest of the lumen being occupied by thrombus.

negative results were due to a small thrombus. Figure 2A shows a large aneurysm without a photopenic area(s) along one or two sides of aneurysmal walls, and Figure 2B shows a large aneurysm with a small thrombus in the posterior aspect of the aneurysm. None of the twenty patients' available aortograms showed a demonstrable thrombus. All 38 patients' CTs and USs showed a mural thrombus, even a little thrombus as shown in Figure 2B.

## DISCUSSION

Enlargements of the aorta, both in length (elongation) and diameter (dilatation) are the findings of aortograms or radionuclide studies and thus are AAA as shown in Figure 1. Individual lesions can be complicated by hemorrhage, ulceration, or thrombosis.<sup>10</sup> The presence of an intraluminal thrombus may result in narrowing of the aorta lumen and stagnation of its flow. An aortogram may show tortuosity, ectasia, angulation, and slow flow, but may also underestimate the size of the aneurysm containing a thrombus.<sup>11</sup>

Similar to contrast angiograms, radionuclide flow studies and blood pool images show atherosclerotic aortic tortuosity, ectasia, and slow flow. An aneurysmal thrombus usually cannot be detected by an aortogram as shown in Figure 5B. Similarly, a radionuclide aortogram is unable to demonstrate extramural abnormalities, though both aortograms and radionuclide studies demonstrate the functional or patent caliber of an aneurysm's lumen. The

patent lumen of a large aneurysm may therefore be similar to the caliber of a normal aorta, or the lumen seen on arteriographic and radionuclide images may be even smaller than that of a normal aorta in the presence of a large amount of thrombus.

CT and/or US are known to be accurate in defining the outer diameter of AAA. The presence and the size of aneurysms may be demonstrated by CT and US,<sup>12,13</sup> and the thrombus is well delineated by CT (Figs. 2B, 3C, 4B and 5C). Although our previously reported case had a large eccentric mural thrombus of an abdominal aortic aneurysm which was demonstrated by aortography as well as a radionuclide study<sup>9</sup>; in this study none of the patients' available aortograms showed a thrombus or even the presence of a large amount of mural thrombus.

With a large amount of mural thrombus, 12 of 38 patients (32%) with aneurysm demonstrated a longitudinal photon-deficient area along the aneurysmal wall on radionuclide studies preferably on blood pool imaging. The longitudinal photopenic area along the one side (left side or right side) of the aneurysmal wall results in an

eccentric type thrombus, as shown in Figures 3A and B. The existence of a photopenic area along both sides of the aneurysmal wall usually results in a concentric type, as shown in Figures 4A and 5A. These findings result from the large mural thrombus being interposed between one side or both sides of bowel/mesentery radioactivity and the radioactivity of the aneurysmal functioning patent lumen. The huge AAA may occupy the entire anterior abdominal cavity, displacing the bowel to the lateral side(s) of the abdominal cavity.<sup>9</sup> There may be little or no bowel interposition between the abdominal wall and AAA.

In summary, though a radionuclide angiogram and blood pool imaging is usually unable to demonstrate an extraluminal abnormality such as a thrombus in an abdominal aortic aneurysm, 32% of our patients with AAA had a large mural thrombus of either an eccentric or a concentric type. We conclude that a photon deficient area along the narrowing aortic aneurysm may indicate a large mural thrombus associated with an abdominal aortic aneurysm.

#### ACKNOWLEDGMENTS

We would like to thank Ms. Edie Horn and Ms. Lillian Owens for their secretarial help.

#### REFERENCES

1. Stonily RH, Effency DR. Wylie's Atlas of Vascular Surgery. In Basic Consideration and Techniques, Philadelphia, J.B. Lippincott Co., pp. 4-11, 1992.
2. Reed D, Re D, Stemmermann G, Hayashi T. Are aortic aneurysms caused by atherosclerosis? *Circulation* 85: 205-211, 1992.
3. Dobrin P. Pathophysiology and pathogenesis of aortic aneurysms. *Surg Clin North Am* 69: 687-703, 1989.
4. Collin J. The epidemiology of abdominal aortic aneurysm. *British J Hosp Med* 1: 64-67, 1988.
5. Shih WJ, Pulmano C. Extrarenal abnormalities seen in <sup>99m</sup>Tc DTPA renal flow study. *Semin Nucl Med* 19: 69-71, 1989.
6. Shih WJ, Domstad PA, DeLand FH. Extrarenal abnormalities in Tc-99m DTPA renal blood flow studies. *Radiology* 154: 197, 1985.
7. Negrin JA, Mack JM, Antar MA, Spencer RP. Bilobed aortic aneurysm detected on bleeding study. *Clin Nucl Med* 15: 443-444, 1990.
8. Shih WJ, Magoun S, Domstad PA. Huge abdominal aortic aneurysm demonstrated by technetium-99m labeled RBC blood pool imaging. *Clin Nucl Med* 12: 825-826, 1987.
9. Shih WJ, Pulmano C. Large eccentric mural thrombus of abdominal aortic aneurysm: Demonstration by aortography and radionuclide angiography. *AJR* 163: 481-482, 1994.
10. Chan O, Thomas ML. The incidence of popliteal aneurysm in patients with arteriomegaly. *Clin Radiology* 41: 185-189, 1990.
11. Zwiebel WJ. Aortic and iliac aneurysm. *Semin in Ultrasound, CT, and MRI*, pp. 53-68, 1992.
12. Weiner SN, Hoffman J, Bernstein RG, Koenigsberg M. *Angiology* 34: 418-428, 1983.
13. Gomes MN. Acta scanning in the diagnosis of abdominal aortic aneurysms. *Computed Tomography* 1: 51-61, 1978.