

Extensive soft-tissue involvement of dermatomyositis detected by whole-body scintigraphy with ^{99m}Tc -MDP and ^{201}Tl -chloride

Yiwei WU, Hikaru SETO, Masashi SHIMIZU, Masanari KAGEYAMA, Gakuto TOMIZAWA,
Shinichiro TOYOSHIMA and Masao KAKISHITA

Department of Radiology, Toyama Medical and Pharmaceutical University

The authors present a case of extensive soft-tissue radioactivity visualized on both ^{99m}Tc -MDP and ^{201}Tl -chloride scintigrams in a patient with dermatomyositis and colon cancer. Incidentally, diffuse and intense uptake of ^{99m}Tc -MDP was observed in the shoulder girdles, anterior chest wall, psoas muscles, both proximal thighs and right lower limb, corresponding to the sites of symptomatic muscles, even though skin lesions were limited and no calcification was detected on radiographs. Moreover, ^{201}Tl -chloride was also intensely accumulated in nearly the same sites as the symptomatic muscles as shown on the ^{99m}Tc -MDP bone scintigrams.

Whole-body scintigraphy with ^{99m}Tc -MDP and ^{201}Tl -chloride is a useful tool to detect occult muscle lesions with dystrophic calcification and hyperemia in dermatomyositis.

Key words: dermatomyositis, ^{99m}Tc -MDP, ^{201}Tl -chloride

INTRODUCTION

^{99m}Tc -PHOSPHATE COMPOUND UPTAKE by nonneoplastic muscle during routine bone scintigraphy has been reported in various diseases including muscle trauma, rhabdomyolysis, polymyositis and dermatomyositis.¹⁻³ In addition, ^{201}Tl -chloride has found wide acceptance for cardiac and skeletal muscular imaging, but the diagnostic value of ^{201}Tl -chloride scintigraphy has not, to our knowledge, been reported in dermatomyositis. We therefore describe extensive soft-tissue uptake of both ^{99m}Tc -MDP and ^{201}Tl -chloride in a patient with biopsy-proven dermatomyositis.

CASE REPORT

A 48-year-old man was referred to a hospital for work-up of new skin lesions. These had appeared two months prior to presentation, and were described as diffuse erythema and maculopapular eruption, which involved mainly the skin of the face, chest and forearms (Fig. 1). He also complained of weakness and pain in the proximal muscles of the arm, lower back and neck.

Received June 7, 1995, revision accepted September 6, 1995.

For reprint contact: Hikaru Seto, M.D., Department of Radiology, Toyama Medical and Pharmaceutical University, 2630 Sugitani, Toyama 930-01, JAPAN.

Laboratory examination revealed an extremely high CPK value of 10,727 IU/l [BB(CK₁): 0, MB(CK₂): 659, MM(CK₃): 8,661]. Other abnormal laboratory data included antinuclear antibody (HEP₂): × 640, GOT: 473 IU/l, GPT: 330 IU/l, LDH: 1,712 IU/ml, LAP: 68 IU/l, BUN: 24.4 mg/dl.

Biopsy of the skin and muscles at the anterior chest wall and shoulder girdles revealed inflammatory infiltrates and muscle fiber damage, indicating the presence of dermatomyositis. A neoplasm was therefore searched for, and a large colon cancer in the sigmoid was detected by barium enema examination (Fig. 2).

Whole-body bone scintigraphy with ^{99m}Tc -MDP was performed to determine the presence of any metastatic bony lesions. No focal bony lesion was detected. Incidentally, diffuse and intense radioconcentration was noted in the soft tissue of both shoulder girdles, the anterior chest wall, thighs, psoas muscles and right lower limb, corresponding to the sites of symptomatic muscles (Fig. 3).

Tumor scintigraphy with ^{67}Ga -citrate, however, revealed no abnormality anywhere including the soft-tissues. Muscle scintigraphy with ^{201}Tl -chloride was performed to evaluate the state of the skeletal muscles. The patient was kept at rest in the supine position for 10 minutes before injection. Twenty minutes after the intravenous administration of ^{201}Tl -chloride (74 MBq), whole body and spot images were obtained with a gamma camera (GE MaxiCamera 400AT, USA). Interestingly,

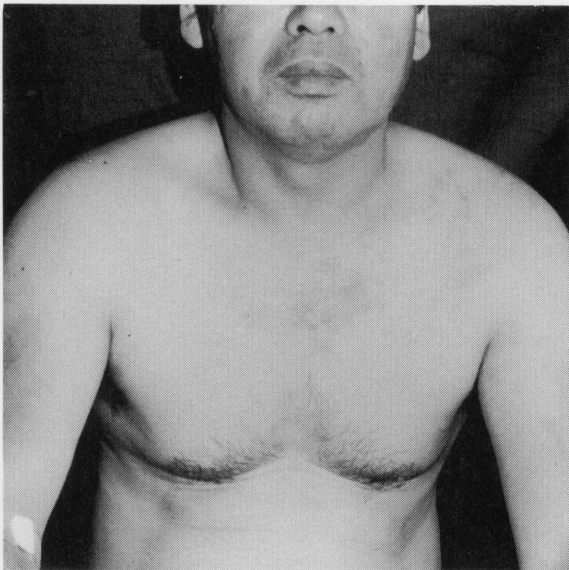

Fig. 1 Diffuse erythema and maculopapular eruption were seen in the skin of face, chest and forearms.

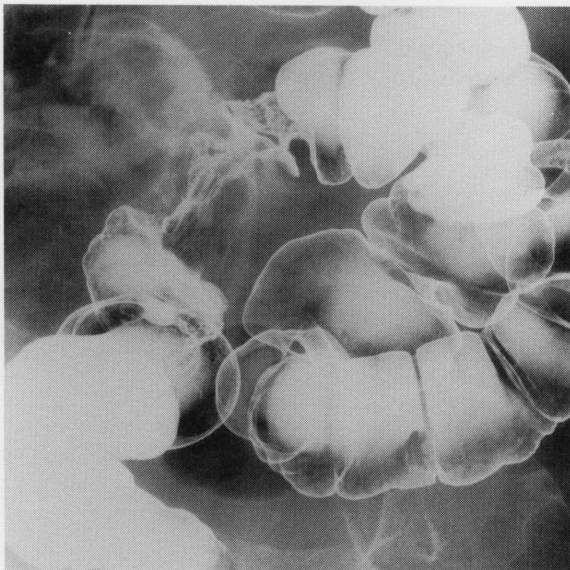


Fig. 2 A large apple-core shaped colon cancer in the sigmoid was detected on barium enema.

diffuse and intense radioactivity was also found in the shoulder girdles, anterior chest wall and both proximal thighs (Fig. 4), which were nearly the same sites as shown on the ^{99m}Tc -MDP bone scintigrams. Also noticed was the intense activity in the brachial muscles on the spot images (Fig. 5). Routine radiologic examinations, however, revealed no calcification in the soft-tissues as described above.

DISCUSSION

Dermatomyositis and polymyositis are conditions of presumed autoimmune etiology, in which the skeletal muscle

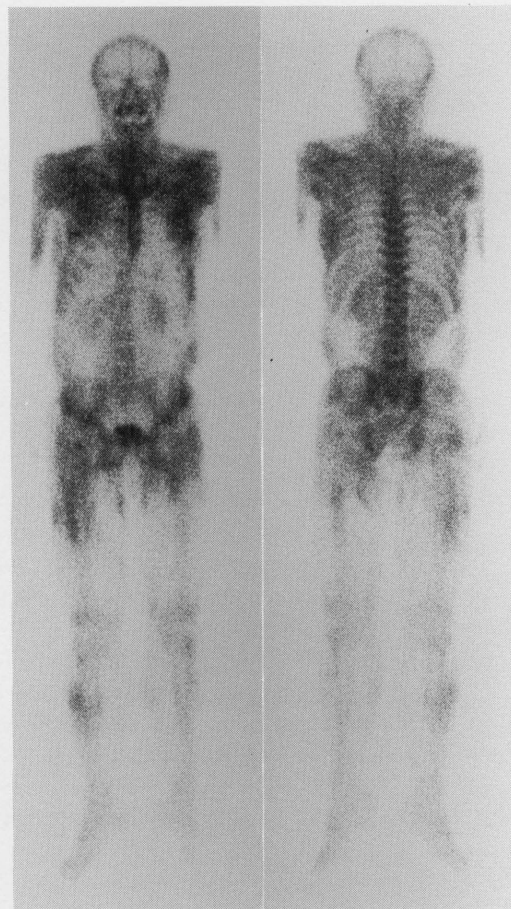

Fig. 3 Whole-body bone scintigrams with ^{99m}Tc -MDP showed extensive and intense radioconcentration in the shoulder girdles, anterior chest wall, thighs, psoas muscles and right lower limb, corresponding to the sites of symptomatic muscles.

is damaged by a nonsuppurative inflammatory process dominated by lymphocytic infiltration. The term dermatomyositis is used when polymyositis is associated with a characteristic skin rash. One-tenth of dermatomyositis may be associated with malignancy in the adult-onset form, and the most common are of lung, ovary, breast and gastrointestinal tract origin.⁴ In our case, the patient also had a colon cancer.

Previous publications have demonstrated that ^{99m}Tc -phosphate compound scintigraphy was useful in the detection of soft-tissue calcification in polymyositis and dermatomyositis,⁵⁻⁸ whether calcification was detected on radiographs or not. Soft-tissue activity demonstrated on bone scintigrams may be the result of any process causing calcification or devitalization of the tissue. Conditions with a tendency to cause soft-tissue calcification may be dystrophic or metastatic. Dystrophic calcification is a calcium salt deposition in abnormal or dead tissue. In dermatomyositis, the bone-seeking radiopharmaceuticals may be deposited onto the calcium-phosphate complex, which is formed in the mitochondria of the degenerated muscle cells when the muscle is damaged.⁷

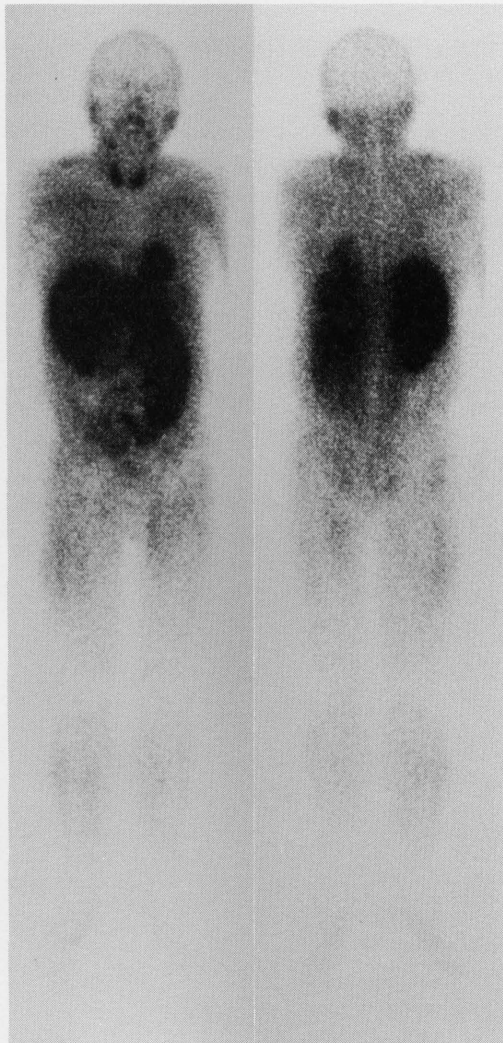

Fig. 4 Whole-body muscle scintigrams with ^{201}Tl -chloride demonstrated extensive and intense uptake in the symptomatic muscles corresponding to nearly the same sites of $^{99\text{m}}\text{Tc}$ -MDP abnormal uptake.

In the present case, extensive soft-tissue uptake of $^{99\text{m}}\text{Tc}$ -MDP was observed incidentally in both shoulder girdles, the anterior chest wall, psoas muscles, thighs and right lower limb, without calcification detection on radiographs. The skin lesions were limited, therefore, and these findings on the bone scintigrams are of clinical use in searching for occult muscle lesions affected by dermatomyositis. In fact, the muscles showing $^{99\text{m}}\text{Tc}$ -MDP uptake corresponded to the sites of symptomatic muscles exhibiting pain and weakness.

Interestingly, extensive intense muscle uptake of radioactivity was also shown on the muscle scintigrams with ^{201}Tl -chloride, which revealed almost the same soft-tissue distribution as $^{99\text{m}}\text{Tc}$ -MDP. The mechanism of ^{201}Tl -chloride uptake in the muscles involved with dermatomyositis is not clear. It appears in general to be related to its biological properties, which are similar to those of potassium.⁹ It is rapidly and highly extracted by striated muscles

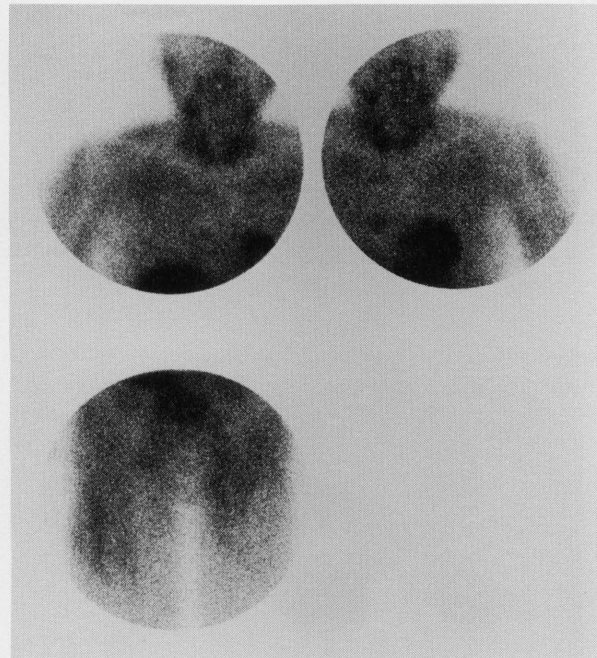

Fig. 5 Spot scintigrams with ^{201}Tl -chloride clearly demonstrated the muscle lesions with intense uptake, and also noticed the intense activity in the brachial muscles of forearms.

such as myocardium and skeletal muscles.¹⁰ Its initial distribution in the muscles therefore reflects the fractional cardiac output and parallels regional blood flow to these tissues. The skeletal muscles involved with dermatomyositis may be inflamed and hyperemic, causing increased ^{201}Tl uptake depending on the disease stage.

In conclusion, ^{201}Tl -chloride muscle scintigraphy can be a useful tool to investigate occult muscle lesions affected by dermatomyositis as well as $^{99\text{m}}\text{Tc}$ -MDP bone scintigraphy. However, further investigations should be performed on larger patient groups to confirm the present observations.

REFERENCES

1. Brill DR. Radionuclide imaging of nonneoplastic soft tissue disorders. *Sem Nucl Med* 11: 277-288, 1981.
2. Desai A, Eymontt M, Alavi A, Schaffer B, Dalinka MK. $^{99\text{m}}\text{Tc}$ -MDP uptake in nonosseous lesions. *Radiology* 135: 181-184, 1980.
3. Goldfarb CR, Ongseng F, Kuhn M, Metzger T. Non-skeletal accumulation of bone seeking agents: pelvis. *Sem Nucl Med* 18: 159-161, 1988.
4. Tandan R, Bradley WG. Dermatomyositis and polymyositis. In Harrison's Principles of Internal Medicine, 13th ed., New York, McGraw-Hill, pp. 2379-2383, 1994.
5. Pendergrass HP, Potsaid MS, Castronovo FP. The clinical use of $^{99\text{m}}\text{Tc}$ -diphosphonate (HEDSPA). *Radiology* 107: 557-562, 1973.
6. Sarminento AH, Alba J, Lanaro AE, Dietrich R. Evaluation of soft-tissue calcifications in dermatomyositis with $^{99\text{m}}\text{Tc}$ -

- phosphate compounds: case report. *J Nucl Med* 16: 467–468, 1975.
7. Otsuka N, Fukunaga M, Ono S, Nagai K, Morita K, Tomomitsu T, et al. Visualization of soft tissue by technetium-99m MDP in polymyositis. *Clin Nucl Med* 13: 291–293, 1988.
 8. Sfakianakis GN, Damoulaki-sfakinaki E, Bass JC, Earl WC, Riccobono XJ. Tc-99mpoly-phosphate scanning in calcinosis universal's of dermatomyositis. *J Nucl Med* 16: 568, 1975 (abstract).
 9. Gehring PJ, Hammond PB. The interrelationship between thallium and potassium in animals. *J Pharm Exp Ther* 55: 187–201, 1967.
 10. Seto H, Kageyama M, Shimizu M, Nagayoshi T, Futatsuya R, Kakishita M. Effect of ionic and nonionic contrast media on regional distribution of thallium-201 in rabbits. *Radiat Med* 13: 19–22, 1995.