

Comparative accuracy of various Tl-201 reinjection imaging protocols to detect myocardial viability

Hitoshi NARUSE, Tomohiro KONDO, Tohru ARII, Masato MORITA, Mitsumasa OHYANAGI,
Tadaaki IWASAKI and Minoru FUKUCHI

*First Department of Internal Medicine and Department of Nuclear Medicine,
Hyogo College of Medicine*

The conventional exercise-3 hours-redistribution thallium-201 [^{201}Tl] imaging protocol has been recognized to be suboptimal for reliable detection of myocardial viability. Although ^{201}Tl rest-reinjection after exercise has improved detection of viable myocardium, it is still underestimated in some patients. The present study was designed to compare detection of viable myocardium in five separate imaging steps: step 1: initial-exercise imaging, step 2: delayed-exercise imaging, step 3: Tl-201 reinjection imaging after delayed-exercise imaging, step 4: separate day rest-reinjection imaging, and step 5: separate day delayed-rest imaging. The study group consisted of 22 patients scheduled for coronary revascularization (either percutaneous transluminal coronary angioplasty or coronary bypass surgery). Pre- and postintervention echocardiographic wall motion and thickness served as independent markers of myocardial viability. Results: Accuracy in identifying myocardial viability gradually improved incrementally from ^{201}Tl imaging step 1 to step 5. The positive predictive value, negative predictive value and overall accuracy were best for the separate day delayed-rest study (step 5) at 90%, 33% and 78%, respectively. Myocardial segments had fixed defects on separate day delayed-rest ^{201}Tl imaging (step 5), but nevertheless echocardiographic evidence of myocardial viability indicated less severe defects than segments judged nonviable by echocardiography ($p = 0.021$). The overall accuracy of separate day delayed-rest imaging (step 5) in predicting viability improved to 88% when segments with moderate or mild defects were considered viable. In conclusion, the most reliable predictor of myocardial viability with ^{201}Tl imaging is defect severity on separate day delayed-rest images.

Key words: ^{201}Tl exercise-reinjection study, ^{201}Tl rest-injection study, myocardial infarction, coronary revascularization, myocardial viability

INTRODUCTION

THALLIUM-201 [^{201}Tl] redistribution, i.e. complete or partial reversibility of a myocardial perfusion defect, is generally accepted to indicate the presence of viable myocardium,¹⁻³ but some apparently fixed ^{201}Tl defects on delayed redistribution imaging after exercise may nevertheless show improvement after coronary revascularization.^{4,5} Conventional redistribution ^{201}Tl imaging may therefore underestimate myocardial viability in some patients.^{6,7}

In recent years, various protocols using rest reinjection of ^{201}Tl have been shown to improve the accuracy of

detection of viable myocardium. A multitude of ^{201}Tl rest-reinjection protocols have been proposed,⁸⁻²² none of which appears to detect myocardial viability with complete accuracy.

The purpose of the present study was to systematically evaluate the increasing value of various steps in a Tl-201 exercise-redistribution-rest-reinjection imaging protocol to identify viable myocardium.

MATERIALS AND METHODS

Patients

The study population consisted of 22 patients with previous myocardial infarction (21 men and 1 woman, mean age 60 ± 11 years), who had coronary revascularization 2 to 6 months after the infarction. The diagnosis of acute

Received August 16, 1995, revision accepted November 24, 1995.

For reprint contact: Hitoshi Naruse, M.D., Hyogo College of Medicine, 1-1 Mukogawa-cho, Nishinomiya 663, JAPAN.

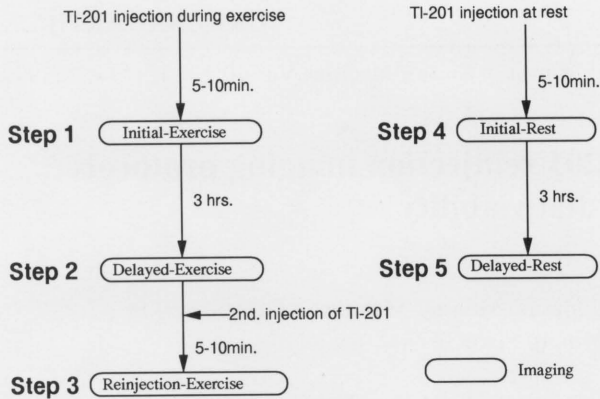


Fig. 1 ^{201}Tl imaging protocol. Myocardial perfusion imaging was performed in 5 steps: step 1) Initial-Exercise, step 2) Delayed-Exercise, step 3) ReInjection-Exercise, step 4) Initial-Rest and step 5) Delayed-Rest. Steps 1 through 3 were performed in one day, steps 4 and 5 on a different day with one week interval.

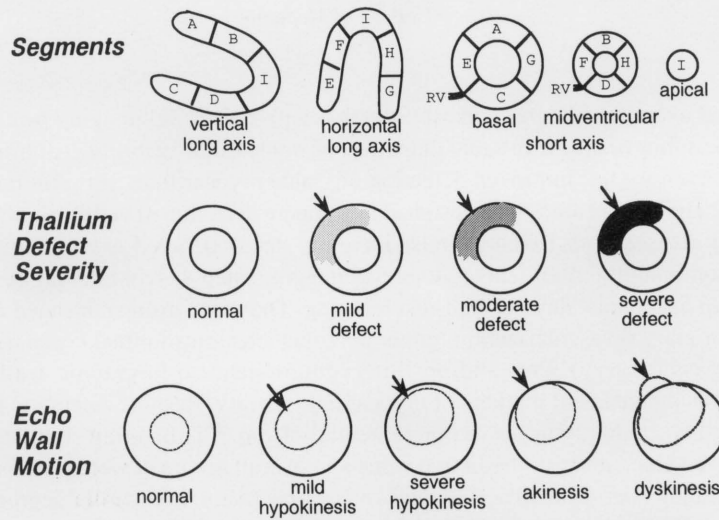


Fig. 2 Schema of analysis of SPECT images and echocardiography. Left ventricular myocardium in SPECT slices was divided into 9 segments (A through I). ^{201}Tl defect severity was scored from mild to severe. Echocardiographic wall motion was scored from mild hypokinesis to dyskinesis. Arrows indicate abnormal area.

myocardial infarction was based on all of the following criteria: acute chest pain lasting longer than 30 min, serum creatine kinase > 1,000 IU and development of abnormal Q-waves on electrocardiography.

All patients underwent ^{201}Tl exercise and rest imaging prior to revascularization. The infarct related artery was the right coronary artery in 5 patients and the left anterior descending coronary arteries in 17 patients. Coronary artery bypass surgery was performed in 5 patients (2-vessel bypass in 4 patients and 3-vessel bypass in 1 patient), and single-vessel percutaneous transluminal angioplasty (PTCA) was performed in the remaining 17 patients. All patients had repeat coronary (or graft) angiography 6 months after revascularization to confirm patency in the target vessels.

^{201}Tl SPECT imaging

Symptom-limited exercise testing was performed on an upright bicycle ergometer. The workload was increased with 25 Watts in 3 minute increments until an exercise end point was reached i.e. fatigue, severe angina, ST segment depression more than 2 mm, decrease in blood pressure

more than 20 mmHg or ventricular tachycardia. At the end point of the exercise, 74 MBq (2.0 mCi) of ^{201}Tl -chloride was administered intravenously, followed by a 10 ml saline flush. Preoperative ^{201}Tl SPECT imaging was performed in 5 "steps" (Fig. 1). An initial-exercise image (step 1) was acquired within 10 minutes after injection; a delayed (redistribution)-postexercise image (step 2) was acquired 3 hours later. Immediately thereafter 37 MBq (1.0 mCi) of ^{201}Tl -chloride was injected, and a reinjection-exercise image (step 3) was acquired within 10 minutes of the injection. Approximately 1 week later, 111 MBq (3.0 mCi) of ^{201}Tl -chloride was injected at rest, and an initial-rest image (step 4) was acquired within 10 minutes after the injection. A delayed-rest (step 5) image was acquired 3 hours later.

A StarCam SPECT gamma camera (General Electric, Milwaukee) was used for single-photon emission computed tomography (SPECT) data acquisition and analysis. From the 45° right-anterior oblique to the 45° left-posterior oblique projection, 32 acquisitions (30 seconds each) were taken over a 180° arc. By filtered back-projection, 6-mm thick short axis and vertical and

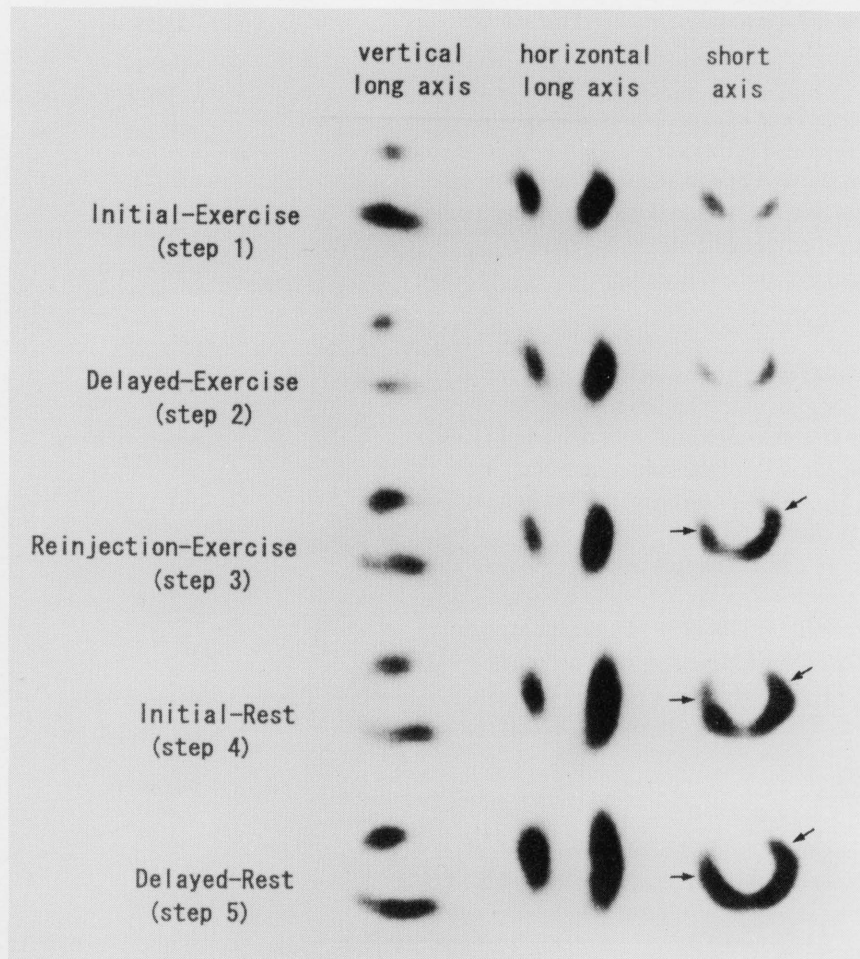


Fig. 3 Example of five-step ^{201}Tl imaging protocol. The images are of a 70-year-old male with a previous myocardial infarction, who had successful PTCA of a 99% stenosis of the proximal left-descending coronary artery. The pre-intervention step 3 ^{201}Tl images show partial improvement of radiotracer uptake in septal and anterolateral regions. On separate day rest-reinjection further improved to normal ^{201}Tl uptake was observed with initial-rest imaging (step 4), and complete fill-in can be appreciated on the delayed-rest imaging (step 5).

horizontal long axes slices of the left ventricle were constructed.

The SPECT images were evaluated qualitatively as the consensus of three experienced observers who were not informed of the patient's history or echocardiographic findings. The left ventricle was divided into 9 segments for analysis of reconstructed slices. Myocardial segments judged to be abnormal were classified according to the severity of myocardial perfusion defects as one of three grades: mild, moderate or severe (Fig. 2).

Thallium-201 redistribution (radiotracer fill-in of perfusion defects) was considered to be present if defect severity on delayed images improved by more than one grade (e.g., from severe to mild or normal or from moderate to normal).

Echocardiography

All patients underwent 2-dimensional echocardiography

before and after revascularization, in a semi-reclining position, by means of Toshiba SSH-60A or SSH-160A ultrasonic equipment. The locations of the short-axis echocardiographic slices were selected to correlate with the short-axis SPECT images.

The left ventricle was divided into 9 segments for analysis. Regional wall motion of the left ventricle was evaluated qualitatively by three experienced observers who were unaware of the ^{201}Tl findings. In segments with abnormal wall motion, the severity of abnormality was classified as one of four grades: mild hypokinesis, severe hypokinesis, akinesis or dyskinesis (Fig. 2). The change in wall motion was considered to be significant and to be evidence of myocardial viability if postoperative wall motion improved by one or more grades compared with the preoperative assessment (e.g., from dyskinesis to severe hypokinesis and from akinesis to normal). Wall thickness, measured on the end-diastolic short-axis

echocardiogram, was judged to be normal if it measured > 10 mm.

Echocardiographic evidence of myocardial viability

The myocardium was judged to be viable if the postoperative echocardiogram showed one or more of the following: 1) normal wall thickness, 2) normal wall motion or 3) improved wall motion as defined above by comparing pre- and post-revascularization wall motion.

Data analysis

The following ^{201}Tl imaging patterns were prospectively hypothesized to predict postintervention myocardial viability: 1) Normal ^{201}Tl uptake at initial-exercise (step 1); 2) Filling-in of a defect at any of the subsequent imaging steps (step 2 to step 5); 3) Defect severity on ^{201}Tl images with fixed defects on step 5 images.

Predictive values are defined as follows:

Positive predictive value = $\text{TP}/(\text{TP} + \text{FP})$, negative predictive value = $\text{TN}/(\text{TN} + \text{FN})$ and overall accuracy = $(\text{TP} + \text{TN})/(\text{TP} + \text{FP} + \text{TN} + \text{FN})$. (TP: true positive, FP: false positive, TN: true negative and FN: false negative).

Statistics

Mann-Whitney U tests were used to compare defect severity. Differences were considered statistically significant when $p < 0.05$.

RESULTS

Angiographic and echocardiographic findings after revascularization

All bypass grafts and recanalized arteries were patent at the time of post-revascularization coronary angiography. In 22 patients, 198 segments were available for analysis. Of a total of 198 available myocardial segments, 121 segments showed both normal wall motion and normal wall thickness, and 48 segments satisfied one of three echocardiographic criteria for myocardial viability. The remaining 29 segments did not show echocardiographic evidence of myocardial viability.

Stepwise ^{201}Tl imaging

Figure 3 shows a representative example of a patient who had the 5-step imaging protocol. Initial-exercise studies showed normal myocardial perfusion in 78 segments and myocardial perfusion defects in 120 segments. Figure 4 displays the occurrence of ^{201}Tl filling-in at each of the subsequent imaging steps. Of 120 initially abnormal segments, filling-in of defects was observed in 36 on delayed-exercise imaging (step 2), in 21 on reinjection-exercise imaging (step 3), in 14 on initial-rest imaging (step 4) and in 7 on delayed-rest imaging (step 5). The remaining 42 segments had fixed myocardial perfusion

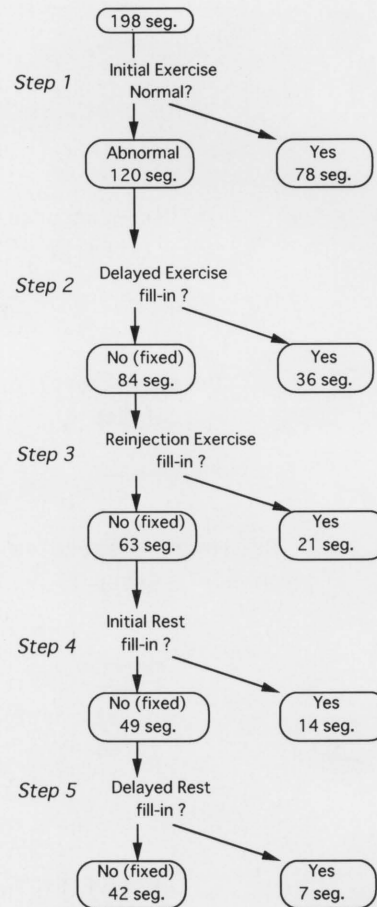


Fig. 4 Flow chart of filling-in of ^{201}Tl defects from step 1 through 5.

defects throughout all imaging steps.

^{201}Tl imaging and echocardiographic evidence of viable myocardium

Echocardiographic evidence of myocardial viability was present in 77 of 78 (99%) normal segments in step 1; in 31 of 36 (86%) segments with reversible defects in step 2; in 15 of 21 (71%) segments with reversible defects in step 3; in 12 of 14 (86%) segments with reversible defects in step 4; and in 6 of 7 (86%) segments with reversible defects in step 5. Overall 141 of 156 (90%) segments that were normal or filled-in had echocardiographic evidence of viability, but 28 of 42 (67%) segments with fixed ^{201}Tl defects on step 5 had apparent echocardiographic evidence of viability.

Figure 5 shows predictive values and overall accuracies for myocardial viability for each step. The accuracies increased from step 1 to step 5. The positive predictive value, negative predictive value, and accuracy of step 5 were 90%, 33% and 78%, respectively.

Defect severity in segments with discordant ^{201}Tl and echocardiography results

In 28 segments, ^{201}Tl defects remained fixed (suggesting




Fig. 5 Positive predictive value, negative predictive value and overall accuracy at each of five imaging steps to detect the echocardiographic evidence of myocardial viability.

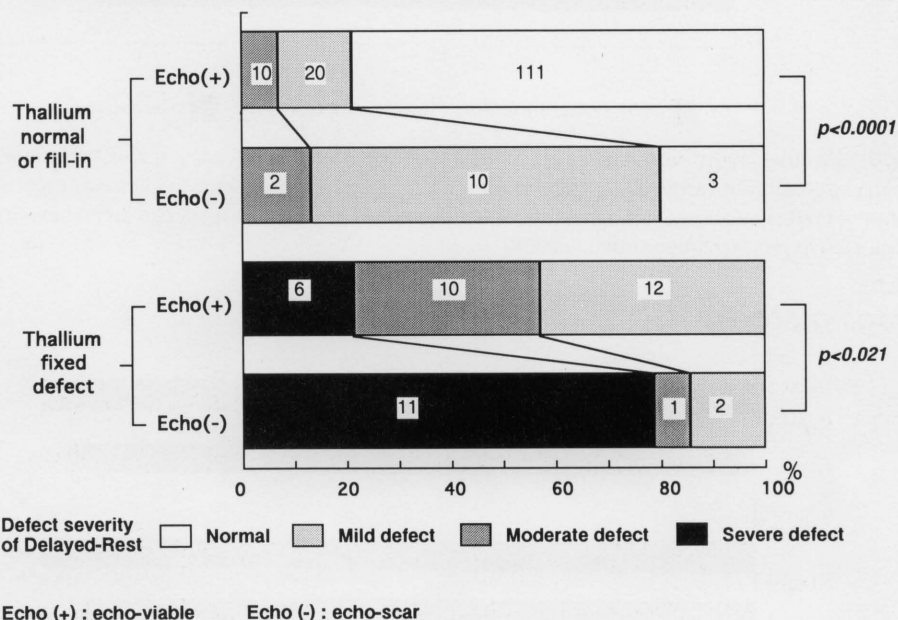


Fig. 6 Defect severity on Delayed-Rest ^{201}Tl imaging (step 5). All 198 segments were classified into four categories with respect to scintigraphic defect severity and echocardiographic evidence of myocardial viability. Echo (+)/(-): echocardiographic viability (+)/scar

scar) on step 5 imaging. Nevertheless echocardiography indicated myocardial viability in these segments. Defect severity in these discordant segments was significantly less severe ($p < 0.021$) than in concordant segments (Fig. 6).

In 15 segments, ^{201}Tl defects showed filling-in at any of the separate steps (suggesting viability), but echocardiography nevertheless indicated scar in these segments. Analyzing the severity in these segments, defect severity (after partial filling-in) was greater ($p < 0.0001$) in these 15 discordant segments than in concordant segments.

When segments with moderate or mild defects were assumed to be viable, the overall accuracy of delayed-rest (step 5) images increased to 88% (Fig. 7).

Although the overall accuracy of reinjection-exercise (step 3) and initial-rest images (step 4) were equivalent, the negative predictive value of step 5 was higher than that

of step 3 and step 4 (Fig. 8).

DISCUSSION

Although the "gold standard" for myocardial viability remains somewhat controversial, in the present study we used echocardiographic normal or improved wall motion, and/or normal wall thickness, as evidence of myocardial viability.

Our results show that additional rest ^{201}Tl imaging increases the accuracy of detecting myocardial viability. In this study, the accuracy increased from step 1 to step 5 (Fig. 4), primarily due to the increase in negative predictive values with a small decrease in positive predictive values. The delayed-rest (step 5) ^{201}Tl images provided the most accurate assessment of myocardial viability.

Exercise-induced myocardial perfusion defects that fill

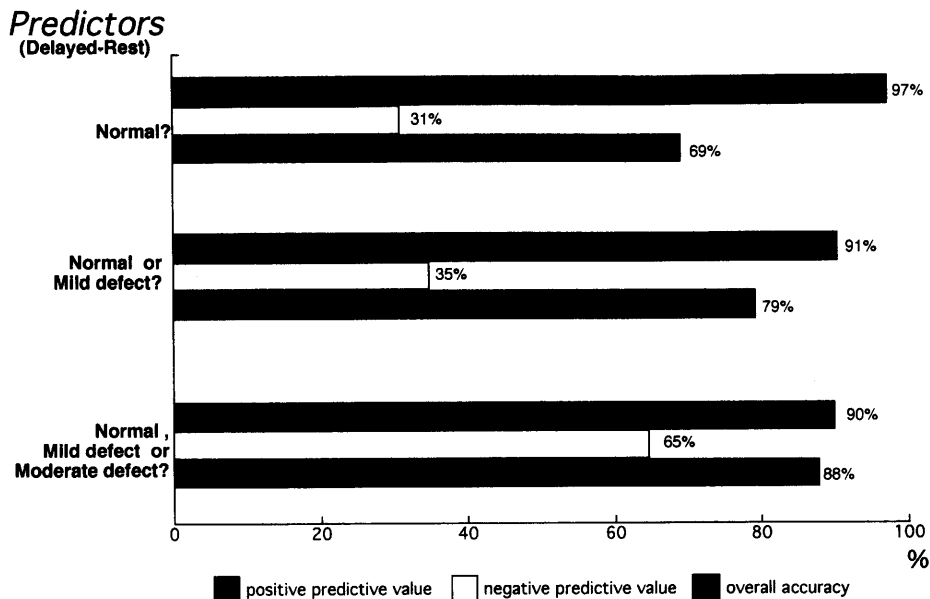


Fig. 7 Positive predictive value, negative predictive value and overall accuracy of ^{201}Tl uptake on separate day delayed-rest imaging (step 5) for predicting echocardiographic evidence of myocardial viability. Predictive accuracy is optimal when normal uptake and mild or moderate defect severity are considered to represent myocardial viability.

Imaging steps

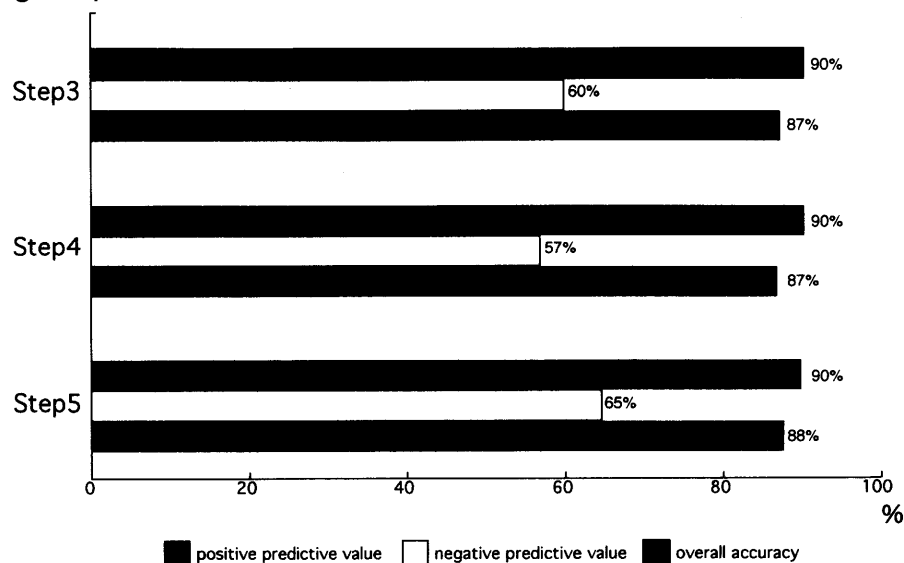


Fig. 8 Positive predictive value, negative predictive value and overall accuracy of each steps for predicting echocardiographic evidence of myocardial viability. Normal uptake and mild or moderate defect severity are considered to represent myocardial viability in this figure.

in with ^{201}Tl redistribution represent myocardial ischemia, and thus myocardial viability, but some ischemic defects take longer to fill in, and are not identified in typical ^{201}Tl stress/delayed protocols.^{23,24} The ^{201}Tl reinjection protocol was designed to address this limitation. Compared with positron emission tomography (PET), however, ^{201}Tl reinjection SPECT still may underestimate myocardial viability.¹⁷⁻¹⁹ Despite the importance of identifying myo-

cardial viability in patients with fixed defects, there have been only a few studies that compared all possible variations in ^{201}Tl reinjection protocols in the same patients, as evaluated in the present study.²⁵⁻²⁷

After our extensive reinjection protocol involving 5 imaging steps, there were still 28/198 false-negative segments (14%) for myocardial viability. Some investigators suggested that defect severity is useful in distinguishing

viable from necrotic (scar) tissue in fixed defects.²⁸⁻³⁰ Our analysis validates this approach. When fixed defects with moderate or mild severity were considered viable, overall accuracy improved to 88%, matching the best reported accuracy based on defect severity.²⁹

Our results show that defect severity on delayed-rest imaging (step 5) is the best overall predictor of myocardial viability. Using this criterion, myocardial viability was underestimated in only 6 of 198 (3.0%) segments.

CONCLUSION

Separate-day delayed-rest ²⁰¹Tl imaging (step 5) provides optimal accuracy for detecting myocardial viability, but this protocol is not practical for routine clinical use, because of the camera time required, the increased cost and patient dosimetry. For most patients, a two-step protocol, initial-exercise/delayed-exercise, is the method of choice for determining viable myocardium. When the delayed-exercise study shows fixed defects, additional separate day delayed-rest ²⁰¹Tl imaging is optimal to determine myocardial viability.

ACKNOWLEDGMENTS

We would like to thank Professor Frans J. Th. Wackers (Yale University) for reviewing the manuscript and making a number of helpful suggestions.

REFERENCES

1. Strauss HW. Thallium redistribution: Mechanisms and clinical utility. *Semin Nucl Med* 10: 70-93, 1980.
2. Pohost GM, Zir LM, Moore RH, McKusick KA, Guiney TE, Beller GA. Differentiation of transiently ischemic from infarcted myocardium by serial imaging after a single dose of thallium-201. *Circulation* 55: 294-302, 1977.
3. Rozanski A, Berman DS, Gray R, Levy R, Raymond M, Maddahi J, et al. Use of thallium-201 redistribution scintigraphy in the preoperative differentiation of reversible and non-reversible myocardial asynergy. *Circulation* 64: 936-944, 1981.
4. Liu P, Kiess MC, Okada RD, Block PC, Strauss HM, Pohost GM, et al. The persistent defect on exercise thallium imaging and its fate after revascularization: does it represent scar or ischemia? *Am Heart J* 110: 996-1001, 1985.
5. Gibson RS, Watson DD, Taylor GJ, Crosby IK, Wellons HL, Holt ND, et al. Prospective assessment of regional myocardial perfusion before and after coronary revascularization surgery by quantitative thallium-201 scintigraphy. *J Am Coll Cardiol* 1: 804-815, 1983.
6. Naruse H, Ohyanagi M, Iwasaki T, Fukuchi M. Indications for coronary revascularization and the postoperative evaluations using thallium-201 exercise myocardial scintigraphy and a bull's eye display. *Am J Noninvas Cardiol* 4: 352-357, 1990.
7. Cloninger KG, DePuey EG, Garcia EV, Roubin GS, Robbins WL, Nody A, et al. Incomplete redistribution in delayed thallium-201 single photon emission computed tomographic (SPECT) images: An overestimation of myocardial scarring. *J Am Coll Cardiol* 12: 955-963, 1988.
8. Dilsizian V, Rocco TP, Freedman NM, Leon MB, Bonow RO. Enhanced detection of ischemic but viable myocardium by the reinjection of thallium after stress-redistribution imaging. *N Engl J Med* 323: 141-146, 1990.
9. Tamaki N, Ohtani H, Yonekura Y, Nohara R, Kambara H, Kawai C, et al. Significance of fill-in after thallium-201 reinjection following delayed imaging: comparison with regional wall motion and angiographic findings. *J Nucl Med* 31: 1617-1622, 1990.
10. Kiat H, Friedman JD, Wang FP, van Train KF, Maddahi J, Takemoto K, et al. Frequency of late reversibility in stress-redistribution thallium-201 SPECT using an early reinjection protocol. *Am Heart J* 122: 613-619, 1991.
11. Ohtani H, Tamaki N, Yonekura Y, Mohiuddin IH, Hirata K, Ban T, et al. Value of thallium-201 reinjection after delayed SPECT imaging for predicting reversible ischemia after coronary artery bypass grafting. *Am J Cardiol* 66: 394-399, 1990.
12. Tsukamoto T, Gotoh K, Yagi Y, Takatsu H, Terashima Y, Nagashima K, et al. Usefulness of resting thallium-201 delayed imaging for detecting myocardial viability in patients with previous myocardial infarction. *Ann Nucl Med* 7: 79-86, 1993.
13. Berger BC, Watson DD, Burwell LR, Crosby IK, Wellons HA, Teates CD, et al. Redistribution of thallium at rest in patients with stable and unstable angina and the effect of coronary artery bypass surgery. *Circulation* 60: 1114-1125, 1979.
14. Gewirtz H, Beller GA, Strauss HW, Dinsmore RE, Zir LM, McKusick KA, et al. Transient defect of resting thallium scans in patients with coronary artery disease. *Circulation* 59: 707-713, 1979.
15. Mori T, Minamiji K, Kurogane H, Ogawa K, Yoshida Y. Rest-injected thallium-201 imaging for assessing viability of severe asynergic regions. *J Nucl Med* 32: 1718-1724, 1991.
16. Ragosta M, Beller GA, Watson DD, Kaul S, Gimble LW. Quantitative planar rest-redistribution ²⁰¹Tl imaging in detection of myocardial viability and prediction of improvement in left ventricular function after coronary bypass surgery in patients with severely depressed left ventricular function. *Circulation* 87: 1630-1641, 1993.
17. Tamaki N, Ohtani H, Yamashita K, Magata Y, Yonekura Y, Nohara R, et al. Metabolic activity in the areas of new fill-in after thallium-201 reinjection: comparison with positron emission tomography using fluorine-18 deoxyglucose. *J Nucl Med* 32: 673-678, 1991.
18. Tamaki N, Yonekura Y, Senda M, Yamashita K, Koide H, Saji H, et al. Value and limitation of stress thallium-201 single photon emission computed tomography: Comparison with nitrogen-13 ammonia positron tomography. *J Nucl Med* 29: 1181-1188, 1988.
19. He ZX, Darcourt J, Guignier A, Ferrari E, Bussiere F, Baudouy M, et al. Nitrates improve detection of ischemic but viable myocardium by thallium-201 reinjection SPECT. *J Nucl Med* 34: 1472-1477, 1993.
20. Kayden DS, Sigal S, Soufer R, Mattera J, Zaret BL, Wackers FJ. Thallium-201 for assessment of myocardial viability:

- Quantitative comparison of 24-hour redistribution imaging with after reinjection at rest. *J Am Coll Cardiol* 18: 1480–1486, 1991.
21. Van Eck-Smit BLF, Van der Wall EE, Kuijper AFM, Zwinderman AH, Pauwels EKJ. Immediate thallium-201 reinjection following stress imaging: A time saving approach for detection of myocardial viability. *J Nucl Med* 34: 737–743, 1993.
 22. Rocco TP, Dilsizian V, McKusick A, Fischman AJ, Boucher CA, Streass HW. Comparison of thallium redistribution with rest “re-injection” imaging for the detection of viable myocardium. *Am J Cardiol* 66: 158–163, 1990.
 23. Gutman J, Berman DS, Freeman M, Rozanski A, Maddahi J, Waxman A, et al. Time to complete redistribution of thallium-201 in exercise myocardial scintigraphy; Relationship to the degree of coronary artery stenosis. *Am Heart J* 106: 989–995, 1983.
 24. Yang LD, Berman DS, Kiat H, Resser KJ, Friedman JD, Rozanski A, et al. The frequency of late reversibility in SPECT thallium-201 stress-redistribution studies. *J Am Coll Cardiol* 15: 334–340, 1990.
 25. Dilsizian V, Perrone-Filardi P, Arrighi JA, Bacharach SL, Quyyumi AA, Freedman NMT, et al. Concordance and discordance between stress-redistribution-reinjection and rest-redistribution thallium imaging for assessing viable myocardium. *Circulation* 88: 941–952, 1993.
 26. Galassi AR, Centamore G, Fiscella A, Coppola A, Liberti F, Franco M, et al. Comparison of rest-redistribution thallium-201 imaging and reinjection after stress-redistribution for the assessment of myocardial viability in patients with left ventricular dysfunction secondary to coronary artery disease. *Am J Cardiol* 75: 436–442, 1995.
 27. Favaro L, Masini F, Serra W, Gavaruzzi G, Benecchi G, Tagliavini S, et al. Thallium-201 for detection of viable myocardium: Comparison of different reinjection protocols. *J Nucl Cardiol* 1: 515–521, 1994.
 28. Dilsizian V, Freedman NM, Bacharach SL, Perrone-Filardi P, Bonow RO. Regional thallium uptake in irreversible defects. *Circulation* 85: 627–634, 1992.
 29. Bonow RO, Dilsizian V, Cuocolo A, Bacharach SL. Identification of viable myocardium in patients with chronic coronary artery disease and left ventricular dysfunction. *Circulation* 83: 26–37, 1991.
 30. Sabia PJ, Powers ER, Ragosta M, Smith WH, Watson DD, Kaul S. Role of quantitative planar thallium-201 imaging for determining viability in patients with acute myocardial infarction and a totally occluded infarct-related artery. *J Nucl Med* 34: 728–736, 1993.