

Scintigraphic evaluation of testicular torsion and acute epididymitis

Leo G. FLORES II, Toru SHIBA, Hiroaki HOSHI, Seishi JINNOUCHI, Shigeki NAGAMACHI
and Katsushi WATANABE

Department of Radiology, Miyazaki Medical College

Purpose of the Study: To evaluate the effectiveness of testicular scintigraphy in differentiating testicular torsion from acute epididymitis. **Method:** 14 out of 17 patients previously screened by urologist were referred for testicular scintigraphy. Preoperative diagnosis was made based on dynamic and static image findings. Close follow-up was done and final diagnosis was confirmed on the basis of operative findings or relief of symptoms after conservative management. **Results:** Eight of the nine patients with a photopenic area in the hemiscrotum were confirmed surgically as having testicular torsion. One patient was diagnosed as having an inflammatory process. Relief from symptoms after conservative management was noted in three patients with increased activity on the affected side and in two others whose uptake patterns were not different from the unaffected side. **Conclusion:** Testicular scintigraphy is effective in differentiating testicular torsion from acute inflammation when all other scrotal anomalies have been eliminated.

Key words: testicular torsion, acute epididymitis, testicular scintigraphy, technetium-99m pertechnetate

INTRODUCTION

TESTICULAR TORSION is considered a surgical emergency because its rapid diagnosis and management could determine the viability of the testis. It is important though to rule out acute epididymitis that could be managed conservatively since it accounts for the majority of testicular morbidity. The overlapping signs and symptoms and the difficulty of examining a tender testicle contribute to the dilemma. Scintigraphy has been reported to have a sensitivity of 90%, a specificity of 89% and an accuracy of 90% in diagnosing torsion.¹ In another study, an accuracy of 80% for acute torsion and 74% for epididymo-orchitis was reported.² There have been reports of false-positive scans for testicular torsion and false negative scans for epididymitis.^{3,4} In this study we found out that prior complete urological examination increased the efficacy of testicular scintigraphy in differentiating testicular torsion from acute epididymitis.

PATIENTS AND METHODS:

The subjects of the study were 17 patients with ages ranging from 7 to 20 years old who presented with acute scrotal pain or swelling or both. The patients were initially thoroughly examined by an experienced urologist. Only those patients in whom testicular torsion could not be differentiated from an inflammatory process were included in the study. Two patients with reactive hyperemia after testicular trauma and another with hematoma of the scrotum were excluded on the basis of the clinical presentation, transillumination test findings and ultrasonographic findings.

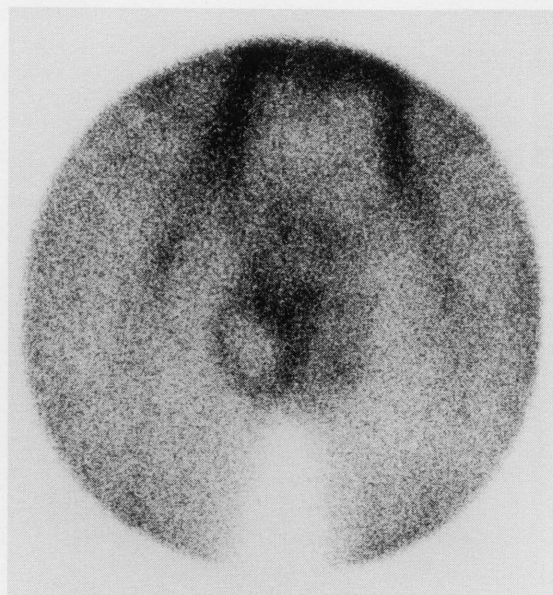
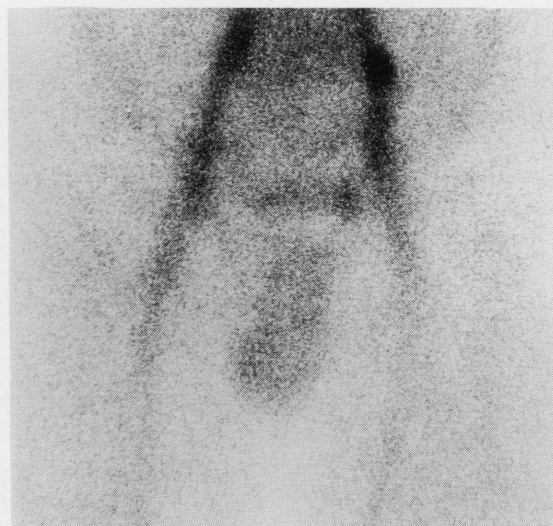Testicular scintigraphy was done by administering 370 MBq (for adults) and 185 MBq (for children) of Technetium-99m pertechnetate intravenously. The patients were then positioned supine and raised as close to the gamma camera as possible. Thighs were abducted to prevent background activity and to achieve maximum elevation of the scrotum. The penis was then taped cephalad on the lower abdominal wall. Acquisition started immediately after the appearance of radioactive dots on the oscilloscope. Initially a dynamic image with a sequence of 10 images of five seconds per image was acquired followed by a static image of 300 seconds per image. A MaxiCamera 400T (GE) gamma camera was used with a low energy

Received August 16, 1995, revision accepted November 13, 1995.

For reprint contact: Leo G. Flores II, M.D., Department of Radiology, Miyazaki Medical College, 5200, Kihara, Kiyotake, Miyazaki 889-16, JAPAN.

Table 1 Comparison of scintigraphic and final diagnosis

Scan diagnosis	Final diagnosis		Total
	Testicular torsion	Acute epididymitis	
Testicular torsion	8	1	9
Acute epididymitis	0	5	5
Total	8	6	14

**Fig. 1** Static image showing a central photon deficient area with a peripheral high uptake in the right testicle.**Fig. 2** Static image showing slight increased of activity in the right testicle.

high resolution parallel beam collimator and data were processed in a Scintipac 700 data processor. During working hours readings were made by more than one qualified physician and after office hours by one nuclear

medicine physician.

Patients with a cold area replacing the testicle or with nubbin sign and with increased activity in the dartos were suspected of having testicular torsion. Those with increased linear or curvilinear activity and increased flow through the cord vessels were suspected of having an inflammatory condition. The final diagnosis was based on operative findings and relief of symptoms after conservative management.

RESULTS

The results have been summarized in Table 1. Nine patients with probable testicular torsion displayed a photon deficient area in the affected testicle. One false positive testicular torsion patient was diagnosed intra-operatively with an infectious process. Three of the five with probable acute epididymitis had increased activity on the affected side. The remaining two patients did not show changes in the accumulation pattern when compared to the unaffected side. Five patients with a final diagnosis of acute epididymitis had relief of the symptoms after conservative management.

Representative cases

Case 1: Testicular torsion: The case of an 11-year-old child who complained of fever and gradually increasing intensity of pain in the right hemiscrotum. There were no abnormal findings on physical examination and laboratory examination. Testicular scintigraphy a few days after the onset of pain showed a central photopenic area surrounded by a rim of high activity. This is typical of a late or missed phase of testicular torsion. Orchiopexy of the left testicle was done, and on follow up atrophy of the right testis was noted (Fig. 1).

Case 2: Acute epididymitis: The case of a 12-year-old child who complained of sudden pain and erythema of the right testicle. There was no significant physical and laboratory examination findings except for the tenderness and erythematous right testicle. There were no abnormal findings on color Doppler examination. A testicular scintigraphy static image 4 hours after the onset of pain showed a mild increase in activity in the right testicle. The patient was given antibiotics and eventually relief was noted (Fig. 2).

Case 3: Acute epididymitis: The case of 16-year-old male who complained of right scrotal pain radiating to the right lower abdomen. A history of scrotal trauma 2 months prior to consultation was extracted. The right testicle was tender and erythematous. Because testicular scintigraphy 11 hours after the onset of pain showed a focal defect on the lower aspect of the testicle, testicular torsion was highly suspected. Relief of symptoms was noted after conservative management (Fig. 3).

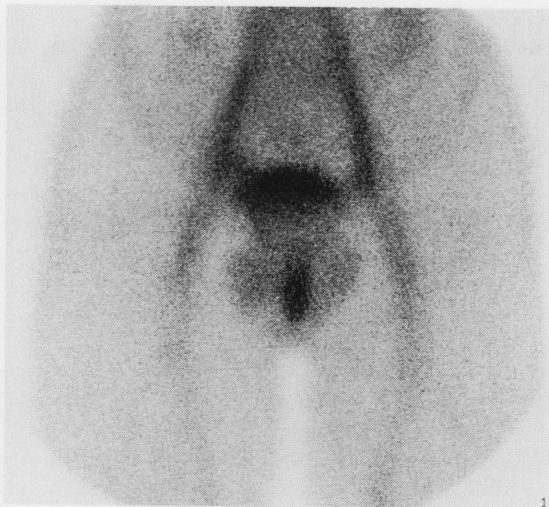

Fig. 3 Static image showing a focal photon deficient area in the right testicle.

DISCUSSION

Previous studies have adequately described the anatomy of the testicular area allowing us to understand the pathophysiology and scintigraphic findings in testicular torsion. It is the abnormally high attachment of tunica vaginalis (bell clapper deformity) and abnormal (long, incomplete and short based) attachment of the mesorchium that causes abnormal mobility of the testicles. There will either be obstruction of the arteries themselves or initially it may be the veins that are obstructed then dilate and exert pressure on the arteries. At the onset there would be edema and congestion of the affected testicle followed by hemorrhage and infarction. The speed of the process depends on the severity of arterial occlusion.⁵⁻⁸

In the early phase (less than five to seven hours after the onset of torsion), dynamic scintigraphy will occasionally show "nubbin sign." Nubbin sign is a bump of activity extending medially from the iliac artery due to a compensatory increase in blood flow from the spermatic cord vessel that suddenly end at the twist. On the static image a cold area replaces the testicle. Increased activity in the dartos is not frequently noted. It will never show increased perfusion. At this stage the testicular salvage rate is between 70–100%.^{5,6}

In the midphase or early "missed torsion" (seven to 24 hours after the torsion), there will be increased perfusion in the scrotal area via the pudendal arteries. This will cause scrotal erythema and edema that would appear as a hot rim ("halo") around a photon deficient testis. The photon deficient area is centrally located and is usually ovoid in adults and circular in children. The size is almost the same as or larger than the normal hemiscrotum. Dynamic scintigraphy will frequently show "nubbin sign." At 12 hours the salvage rate drops to less than 20%.^{5,6}

In the late phase or missed testicular torsion (more than

24 hours after torsion), there would be an increase in pudendal flow causing intensification of scrotal halo. The degree of scrotal reaction is proportional to the degree of ischemia. It has been observed that when the intensity of the scrotal activity exceeds that of the femoral vessel, the salvage rate is almost zero. Due to probable contralateral antispermatic effects of damaged testicular tissue left *in situ*, there is still a need to diagnose and treat testicular torsion at this stage.^{5,6}

In our study of the eight patients confirmed surgically as having testicular torsion, 5 were in the early phase, 1 in the midphase and 2 in the late phase.

Differential diagnosis of a cold testis includes epididymo-orchitis, abscess, trauma, hydrocele, inguinal hernia, testicular prosthesis, spermatocele, appendage torsion, granuloma and tumor. Most of the above conditions could be ruled out by their clinical presentation, physical examination, transillumination, ultrasonography or specific scintigraphic appearance.³

In acute epididymitis, dynamic scintigraphy will show increased flow through the cord vessels and the static image will show increased linear or curvilinear activity directed laterally. A more medial curvilinear activity due to medial displacement of the epididymis and "spot" of increased tracer activity due to focal epididymitis are two of the most common variations of the inflammatory process. As in one of our patients there have been some reports of epididymo-orchitis showing as a relatively cold and focal defect on the affected side due to tissue swelling and edema.^{2,5,6}

There have been reports on the difficulty of differentiating between acute epididymitis and spontaneous detorsion with reactive hyperemia which also shows increased scrotal activity and not testicular photopenia. Since the stage of spontaneous detorsion occurs 0–4 hours after the onset of pain, prior knowledge of the history could lessen errors in scintigraphic interpretation.^{3,4,11}

Some other diagnostic tools suggested to be useful in differential diagnosis of an acute scrotum include Color Doppler, high resolution grey-scale and real-time ultrasonography techniques. Color Doppler has the ability to detect distinct pulsation in the spermatic vessels. In the mid to late phase of testicular torsion the increased pudendal artery perfusion could be confused with the testicular artery pulsation. This could lead to false negative findings. High resolution grey-scale and real-time techniques of ultrasonography can detect hypoechogenicity due to edema in testicular torsion, but edema is a nonspecific finding present also in an infectious process. It has been suggested that the use of both scintigraphy and ultrasonography is the work-up of choice in an acute setting.^{6,10}

Our study showed 100% sensitivity, 83% specificity and 93% accuracy in delineating testicular torsion from acute epididymitis. Prior knowledge of the clinical history and findings in the different phases of testicular torsion and epididymitis with its variations increases the

sensitivity and specificity of testicular scintigraphy. The prior exclusion of other hypovascular scrotal conditions could therefore enhance the usefulness of testicular scintigraphy.

REFERENCES

1. Levy OM, Gittelman MC, Strashun AM, et al. Diagnosis of acute testicular torsion using radionuclide scanning. *J Urol* 129: 975-977, 1983.
2. Dunn EK, Macchia RJ, Chauhan PS, et al. Scintiscan for acute intrascrotal conditions. *Clin Nucl Med* 11: 381-388, 1986.
3. Rosenson AS, Ali A, Fordham EW, et al. A false-positive scan for testicular torsion and false-negative scan for epididymitis. *Clin Nucl Med* 15: 863-864, 1990.
4. Palestro CJ, Finn C. Hydrocele and epididymitis mimicking testicular torsion on scrotal scintigraphy. *Clin Nucl Med* 18: 910-911, 1993.
5. Holder LE, Melloul M, Chen D. Current status of radionuclide scrotal imaging. *Sem Nucl Med* 11: 232-249, 1981.
6. Lutzker LG, Zuckier LS. Testicular scanning and other applications of radionuclide imaging of the genital tract. *Sem Nucl Med* 20: 159-188, 1990.
7. Patriquin HB, Yazbeck S, Trinh B, et al. Testicular torsion in infants and children: diagnosis with Doppler sonography. *Radiology* 188: 781-785, 1993.
8. Chen DCP, Holder LE, Melloul M. Radionuclide scrotal imaging: further experience with 210 patients Part 1: anatomy, pathophysiology, and methods. *J Nucl Med* 24: 735-742, 1983.
9. Chen DCP, Holder LE, Melloul M. Radionuclide scrotal imaging: further experience with 210 new patients Part 2: result and discussion. *J Nucl Med* 24: 841-853, 1983.
10. Middleton WD, Siegel BA, Leland Melson G, et al. Acute scrotal disorders: prospective comparison of color Doppler, US and testicular scintigraphy. *Radiology* 177: 177-181, 1990.