Annals of Nuclear Medicine Vol. 10, No. 1, 57–61, 1996

Bone scintigraphy in detection of bone invasion by oral carcinoma

Kotaro HIGASHI,* Hiromi WAKAO,** Hiroyuki IKUTA,** Isamu KASHIMA** and F. Richard EVERHART, Jr.***

** Department of Radiology, Kanazawa Medical University, Ishikawa, Japan*
*** Kanagawa Dental College, Yokosuka, Japan*
**** Humana Hospital, Aurora, Colorado, USA*

Detecting osseous involvement is clinically important in the management of oral carcinoma. Thirty-one patients with osseous involvement due to oral carcinoma who underwent panoramic radiography and bone scintigraphy were evaluated retrospectively. Bone scintigraphy confirmed osseous involvement in all 31 (100%) of these patients. In 27 (87%) of 31 patients with osseous involvement, both the panoramic radiogram and bone scintigram were positive. In the remaining four patients (13%), bone scintigram was positive for mandibular or maxillary invasion, while panoramic radiogram was negative. There were no instances of an abnormal radiogram with a normal bone scintigram. These findings strongly suggest that bone scintigraphy is more sensitive than panoramic radiography in detecting osseous involvement of the mandible and maxilla due to oral carcinoma. Furthermore, bone scintigraphy was a critical pre-surgical tool in determining the extent of the osseous involvement.

Key words: bone scintigraphy, bone invasion, oral carcinoma

INTRODUCTION

Tc-99m labeled phosphate compounds, introduced by Subramanian and McAfee[1] have proven very useful in the detection of occult skeletal metastases. Optimal treatment planning for oral carcinoma demands accurate determination of whether or not bone invasion is present. Clinical evaluation alone tends to overestimate the likelihood of bone involvement.[2] In conventional radiography, a skeletal metastatic lesion must destroy 30 to 50% of the calcium salts before the lesion is visible.[3] Since Tc-99m phosphate compounds are much more sensitive than radiography in the detection of osseous involvement by tumor,[2-12] bone scintigraphy should provide a more reliable determination of the presence or absence of bone invasion, but the use of Tc-99m phosphate scintigraphy in planning treatment for oral carcinoma has been limited. This study compares the sensitivity of bone scintigraphy to panoramic radiography in the detection of osseous involvement in patients with oral carcinoma.

Received May 19, 1995, revision accepted September 19, 1995.

For reprint contact: Kotaro Higashi, M.D., Department of Radiology, Kanazawa Medical University, 1–1, Daigaku, Uchinada, Kahoku-gun, Ishikawa 920–02, JAPAN.

MATERIALS AND METHODS

Thirty-one patients with osseous involvement due to oral carcinoma who underwent panoramic radiography and bone scintigraphy were evaluated retrospectively. Histological proof of the osseous involvement was obtained at surgery in 29 of the 31 patients. In 2 of the 31 patients, confirmation of the osseous involvement was made by means of a follow-up radiography. These 31 patients with osseous involvement due to oral carcinoma were enrolled in this study, and they consisted of 16 mandibular gingival carcinomas, 10 maxillary gingival carcinomas and 5 buccal carcinomas. All the primary lesions were biopsy proven. The diagnosis in all cases was squamous cell carcinoma except one case which was malignant melanoma.

Bone scintigraphy was performed with a gamma camera (Toshiba Co., Ltd.) equipped with a converging collimator. Approximately 10–15 mCi (370–555 MBq) of Tc-99m MDP (methylene diphosphonate) was injected intravenously, and imaging was perfomed three hours

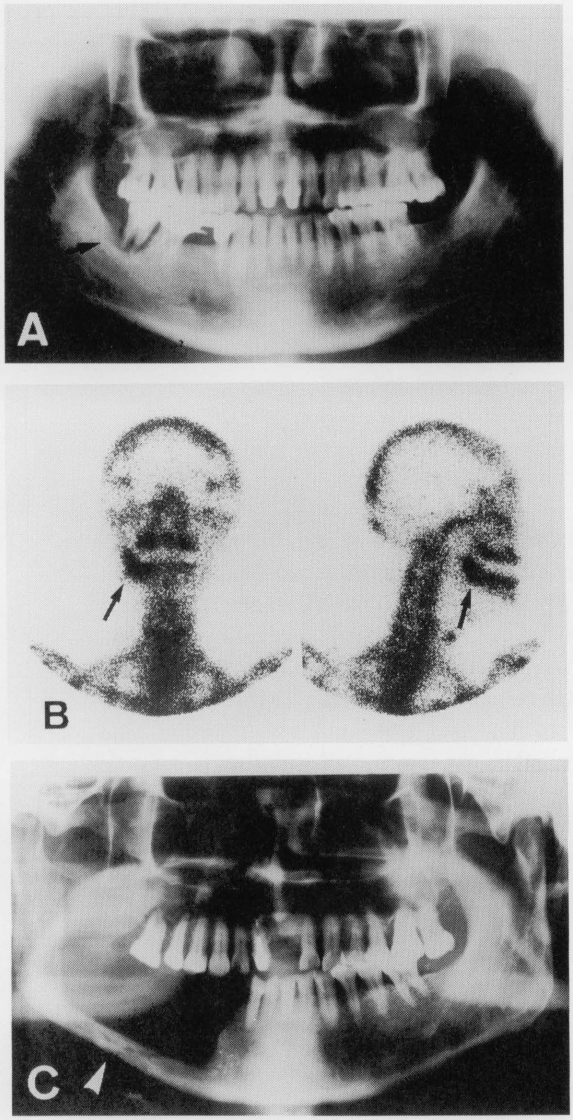

Fig. 1 Mandibular gingival carcinoma. Panoramic radiography and bone scintigraphy both abnormal. Panoramic radiography (A) showed a focal, subtle, radiolucent lesion in second molar of right mandible (arrow). Bone scintigraphy (B), however, demonstrated a much larger area of abnormal increased activity under the inferior cortical border of mandible (arrow). Panoramic radiography (C) made ten months post-operatively demonstrated tumor recurrence with radiolucent lesion (arrow head) at the site of positive scintigraphy.

later. Anterior and both lateral images of the maxillofacial skeleton were obtained. Resultant images were compared to panoramic radiograms retrospectively.

RESULTS

Mandibular gingival carcinoma

Sixteen patients had bone invasion by mandibular gingival carcinoma. Of these, 15 cases (94%) had abnormal panoramic radiography and bone scintigraphy. All the cases were confirmed as osseous involvement on pathological examination of the decalcified mandibular specimen at surgery. A representative case is shown in Figure 1. In this case, the panoramic radiography and bone scintigraphy were positive, but the bone scintigraphy showed a much wider tumor extent than could be predicted from the panoramic radiography.

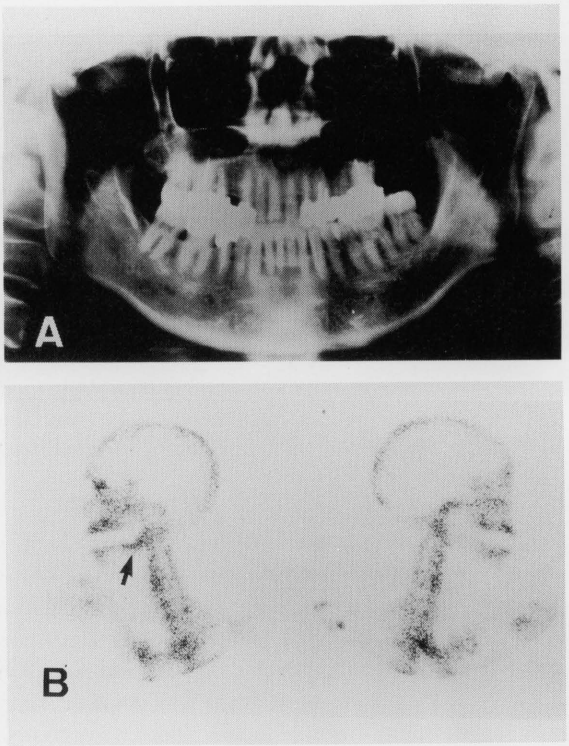

Fig. 2 Mandibular gingival carcinoma. Panoramic radiography negative, bone scintigraphy positive. Panoramic radiography (A) was normal at left second molar. Bone scintigraphy (B) demonstrated minimally increased uptake in left second molar region (arrow), where was the site of the gingival carcinoma and was interpreted as positive for bone involvement. Bone invasion of the mandible by carcinoma was confirmed pathologically. This case illustrates detection of bone invasion earlier with bone scintigraphy than panoramic radiography.

In one patient (6%), the panoramic radiography was normal, but the bone scintigraphy was abnormal, indicating bone invasion of the mandible by the carcinoma. This case is shown in Figure 2. The bone invasion was confirmed pathologically. There were no instances of a normal scintigram with an abnormal radiogram.

Maxillary gingival carcinoma

Of the 10 patients with bone invasion by maxillary gingival carcinoma, nine (90%) were abnormal on both panoramic radiography and bone scintigraphy. A representative case is shown in Figure 3. There was one case (10%) of normal panoramic radiography with abnormal bone scintigraphy, showing maxillary invasion by squamous cell carcinoma (Fig. 4). There were no instances of normal scintigraphy with abnormal radiography.

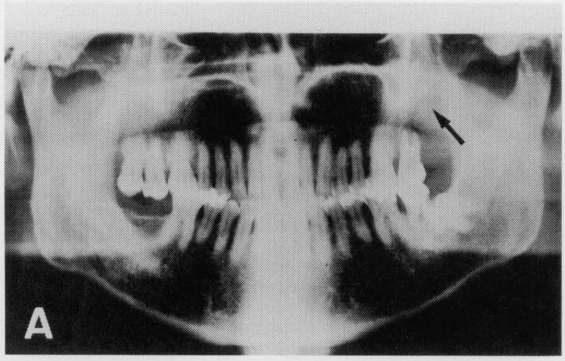

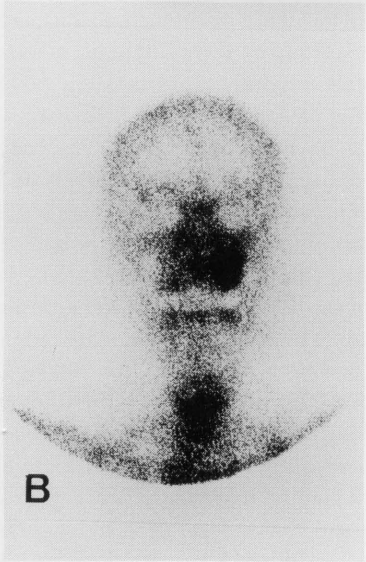

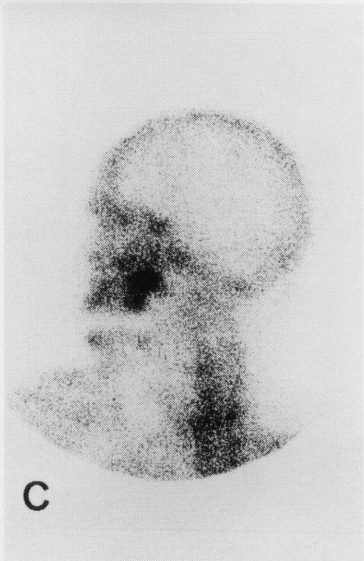

Fig. 3 Maxillary gingival carcinoma. Panoramic radiography and bone scintigraphy both abnormal. Panoramic radiography (A) demonstrated a radiolucent lesion in left maxillary molar region (arrow). Anterior (B) and left lateral (C) view of bone scintigraphy showed increased uptake over a much larger area. Bone scintigraphy was superior in showing extent of lesion.

Buccal carcinoma

Of the 5 cases with bone invasion by buccal carcinoma, three (60%) were abnormal for mandibular involvement on both panoramic radiography and bone scintigraphy. In two patients (40%), panoramic radiography was initially normal while bone scintigraphy was abnormal. In these patients, the follow-up radiography subsequently became positive.

Summary of results

Of the thirty-one patients in this series, twenty-seven patients (87%) had abnormalities demonstrating osseous involvement on both panoramic radiography and bone scintigraphy. In the remaining four patients (13%), panoramic radiography was normal but bone scintigraphy was abnormal for mandibular or maxillary invasion. There were no instances of abnormal radiography with normal bone scintigraphy. For diagnosis of the presence or absence of osseous involvement, bone scintigraphy was 100% sensitive, whereas panoramic radiography was 87% sensitive. Bone scintigraphy was therefore more sensitive than panoramic radiography in detecting osseous involvement of the mandible and maxilla due to oral carcinoma. Furthermore, bone scintigraphy was superior to panoramic radiology in determining the extent of the osseous involvement.

DISCUSSION

Preoperative evaluation of bone invasion by oral carcinoma has always been a difficult problem. Various methods have been used, including clinical evaluation, panoramic radiography, intraoral radiography, routine mandible radiography, bone scintigraphy, computed tomography (CT) and magnetic resonance imaging (MRI). Close et al.[13] reported that, of the 11 cases in which pathologic examination confirmed mandibular invasion, CT confirmed osseous involvement in all 11 (100%) of these patients, while conventional radiography was positive in only seven (63.6%). Shaha[14] compared the diag-

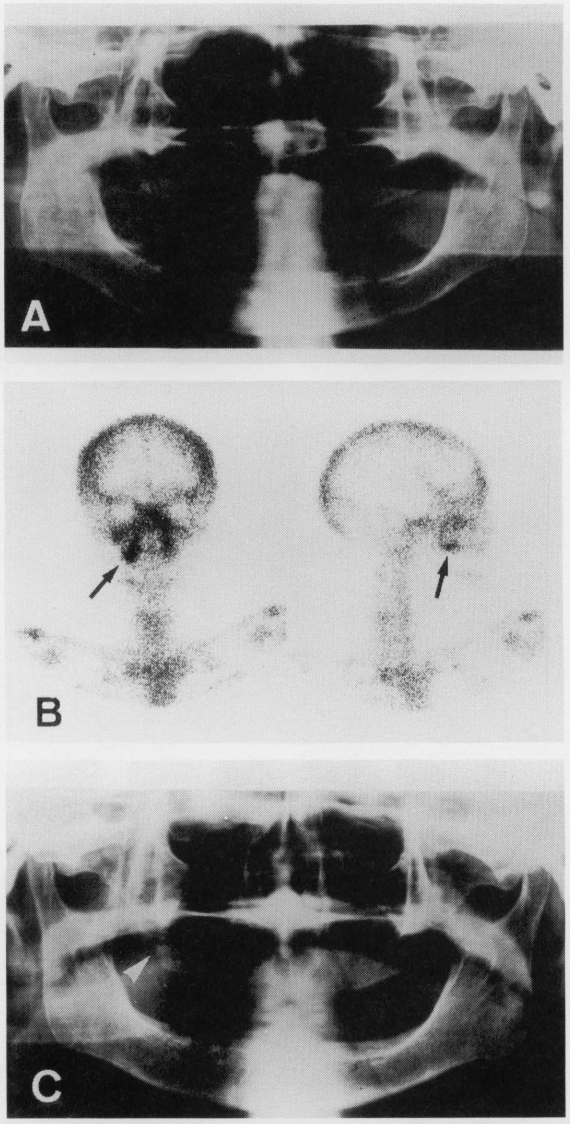

Fig. 4 Maxillary gingival carcinoma. Panoramic radiography negative, bone scintigraphy positive. Panoramic radiography (A) was negative at the site of carcinoma. Bone scintigraphy (B) slightly positive in right maxillary molar region (arrow). Repeat panoramic radiography (C), performed one month later, showed subtle radiolucency (arrow head) corresponding to abnormal bone scintigraphy. Subsequent surgery confirmed the bone invasion by carcinoma. Bone scintigraphy was positive earlier than radiography.

nostic effectiveness of clinical evaluation, panoramic radiography and CT in 60 patients with carcinoma of the floor of mouth. Shaha showed, however, that CT was not very helpful, mainly because of the presence of irregular dental sockets and artifacts, and clinical evaluation was the most accurate, both to determine mandibular invasion and to decide the type of mandibular resection. Ator et al.[15] compared MRI with conventional imaging including panoramic radiography and CT, and found that MRI most accurately determined the full extent of tumor invasion in the mandibular marrow spaces. Pellisser et al.[16] also assessed the impact of MRI and CT as compared to physical examination in the choice of the type of surgery for advanced oral carcinomas (with or without resection of the mandible). MRI and CT both have high sensitivity, as does physical examination, but neither has good specificity. The diagnostic accuracy of these methods has therefore not been totally satisfactory from the clinical standpoint. These evaluation of osseous involvement due to oral carcinoma with MRI and CT have been limited to the mandible, and the evaluation of maxillary bone invasion by MRI and CT have not been reported. Furthermore, dental amalgam artifacts and beam-hardening artifacts from the dense mandible may obscure CT imaging,[17] and the subsets of ferromagnetic metals and certain other metals causing radio frequency power tissue maldistribution cause artifacts on MR images.[17] Although dental amalgam produces no artifact, root canals or metal bridgework occasionally cause artifacts on MR imagings.[17]

Bone scintigraphy is far more sensitive than roentgenography in screening for neoplastic bone disease. Anywhere there is bone tumor, trauma, or infection, there is increased osteoblastic proliferation and an increase in the calcium phosphate product utilized in the osteoid matrix for new bone formation. Bone seeking radionuclides such as Tc-99m phosphate compounds will accumulate in these metabolically active areas and permit detection of abnormalities earlier and with greater sensitivity than radiography. It is generally accepted that trabecular bone changes can be seen on roentgenograms only when mineral loss approaches 30–50%.[3] Alexander reported in 1976[4] that bone scintigraphy was extremely valuable in the early detection and differential diagnosis of lesions involving the maxillo-facial region, such as neoplasm, trauma, inflammation, and metabolic disease. Lurie et al.[3] pointed out that bone scintigraphy is of considerable value in planning surgical treatment of odontogenic keratocysts. Additional articles on the usefulness of maxillo-facial bone scintigraphy followed, including a report from Higashi et al.[6] in 1979 describing the use of bone scintigraphy in estimating the extent of oral cavity carcinoma. In 1981, Bergstedt et al.[7,8] noted that bone scintigraphy was superior to clinical examination or radiography in determining the extent of mandibular and maxillary bone involvement in patients with maxillofacial carcinoma. Similarly, Baker et al.[9] reported the superior sensitivity of bone scintigraphy over panoramic radiography in detecting early mandibular involvement by oral carcinoma.

Our study confirms the superiority of bone scintigraphy versus panoramic radiography in early detection of osseous involvement of not only the mandible but also the maxilla, and in the determination of the extent of bone invasion by oral carcinoma. Of our total thirty-one patients, four patients (13%) had normal panoramic radiography but abnormal bone scintigraphy. Furthermore, in many instances in which radiography is positive for

osseous involvement, the plain films may grossly underestimate the extent of neoplastic bone invasion when compared to bone scintigraphy (see Figs. 1 and 3). Finally, in certain patients with oral carcinoma, there may be technical problems associated with intraoral radiography because of difficulty in film placement. Bone scintigraphy is especially valuable in searching for mandibular involvement in these patients who may have restriction in the opening of their mouth.

A note of caution is, however, in order regarding the interpretation of bone scintigraphy in patients with oral carcinoma. While extremely sensitive, bone scintigraphy is non-specific, and abnormal uptake may occur in such diverse conditions as gingival inflammation, fibrous dysplasia, osteomyelitis, trauma, apical periodontitis, prior dental surgery, radiation osteitis, etc., in addition to neoplasm.[18] Gilbert et al.[2] found a 50% (3/6) false positive rate with bone scintigraphy as compared to 40% (8/20) false positive with roentgenography. Weisman et al.[12] also showed that the false positive rate with bone scintigraphy was 53% as a result of mandibular inflammatory changes. Maxillo-facial bone scintigraphy should therefore never be interpreted without a thorough knowledge of the patient's current dental status and appropriate history. The results of bone scintigraphy must be correlated with physical findings and conventional radiography to exclude irrelevant causes of pathological isotope uptake. The main disadvantage of bone scintigraphy in this setting is still its non-specificity. The low false negative rate, however, leads us to believe that normal bone scintigraphy precludes osseous involvement due to oral carcinoma.

CONCLUSION

Thirty-one patients with osseous involvement due to oral carcinoma were examined by panoramic radiography and bone scintigraphy. Bone scintigraphy confirmed osseous involvement of the maxilla and mandible in all 31 (100%) of these patients, and was more sensitive than panoramic radiography which confirmed osseous involvement in 27 of 31 patients (87%). Furthermore, bone scintigraphy was a critical pre-surgical tool in determining the extent of osseous involvement due to oral carcinoma.

ACKNOWLEDGMENTS

The greater part of this manuscript was designed and written by Tomomitsu Higashi, M.D. who died on June 12, 1989. The authors would like to dedicate this manuscript to his memory.

REFERENCES

1. Subramanian G, McAfee JG. A new complex of ^{99m}Tc for skeletal imaging. *Radiology* 99: 192, 1971.
2. Gilbert S, Tzadik A, Leonard G. Mandibular involvement by oral squamous cell carcinoma. *Laryngoscope* 96: 96–101, 1986.
3. Lurie AG, Puri S, James RB, Jensen TW, Conn F. Radionuclide bone imaging in the surgical treatment planning of odontogenic keratocysts. *Oral Surg* 421: 726–730, 1976.
4. Alexander JM. Radionuclide bone scanning in the diagnosis of lesions of the maxillofacial region. *J Oral Surg* 34: 249–256, 1976.
5. Front D, Hardoff R, Robinson E. Bone scintigraphy in primary tumors of the head and neck. *Cancer* 42: 111–117, 1978.
6. Higashi T, Sugimoto K, Shimura A, Shimura K, Massman JE. Technetium 99m bone imaging in the evaluation of cancer of the maxillofacial region. *J Oral Surg* 37: 254–258, 1979.
7. Bergstedt HF, Lind MG, Silfversward C. Facial bone scintigraphy VII. Diagnosis of malignant lesions in the mandible. *Acta Radiol Diag* 22: 485–493, 1981.
8. Bergstedt HF, Lind MG. Facial bone scintigraphy VIII. Diagnosis of malignant lesions in the maxillary, ethomoidal and palatal bones. *Acta Radiol Diag* 22: 609–617, 1981.
9. Baker HL, Woodbury DH, Krause CJ, Saxon KG, Stewart RC. Evaluation of bone scan by scintigraphy to detect subclinical invasion of the mandible by squamous cell carcinoma of the oral cavity. *Otolaryngol Head Neck Surg* 90: 327–336, 1982.
10. Pretorius D, Taylor A. The role of nuclear scanning in head and neck surgery. *Head & Neck Surg* 4: 427–432, 1982.
11. Gray HW, Souttar DS. Bone scanning in the demonstration of local bony involvement by intra-oral tumors. *Eur J Nucl Med* 11: A20, 1985 (abstract).
12. Weisman RA, Kimmelman CP. Bone scanning in the assessment of mandibular invasion by oral cavity carcinomas. *Laryngoscope* 92: 1–4, 1982.
13. Close LG, Marie M, Burns DK, Schaefer SD. Computed tomography in the assessment of mandibular invasion by intraoral carcinoma. *Ann Otol Rhinol Laryngol* 95: 383–388, 1986.
14. Shaha AR. Preoperative evaluation of the mandible in patients with carcinoma of the floor of mouth. *Head Neck* 13: 398–402, 1991.
15. Ator GA, Abemayor E, Lufkin RB, Hanafee N, Ward PH. Evaluation of mandibular tumor invasion with magnetic resonance imaging. *Arch Otolaryngol Head Neck Surg* 116: 454–459, 1990.
16. Pellissier S, Duvoisin B, Fontolliet C, Monnier P. Magnetic resonance imaging and x-ray computed tomography in advanced cancer of the oral cavity. A comparative clinical, radiological and morphological study. *J Radiol* 75: 577–583, 1994.
17. Lufkin RB, Wortham DG, Dietrich RB, Hoover LA, Larsson SG, Kangarloo H, et al. Tongue and oropharynx: Findings on MR imaging. *Radiology* 161: 69–75, 1986.
18. D'Avignon MB, Baum S. Increased jaw radioactivity on bone imaging. *Sem Nucl Med* XII: 219, 1982.