

## The value of Tc-99m MIBI SPECT during isosorbide dinitrate infusion in assessment of viable myocardium in patients with myocardial infarction

Sheng-Ting LI, Xiu-Jie LIU, Zong-Liang LU, Xiao-Dong ZHU, Rong-Fang SHI, Yao-Jin YANG, Feng LU, Wen-Qi CHEN, Qing-Wen WU and Yun-Zhong LIU

*Cardiovascular Institute and Fu Wai Hospital, Chinese Academy of Medical Sciences, China*

Tc-99m MIBI myocardial SPECT has shown promise for evaluation of coronary artery disease. But its role in predicting myocardial viability is still under investigation. The purpose of this study was to evaluate the value of Tc-99m MIBI myocardial SPECT during isosorbide dinitrate (ISDN) infusion in the assessment of myocardial viability. Thirty-seven patients with previous myocardial infarction (the infarct age ranged from  $\leq 30$  days to 900 days) were studied, of them 13 patients had Tc-99m MIBI studies before and after coronary artery bypass grafting (CABG). The results showed that out of 134 segments with hypoperfusion at resting SPECT, 56 segments (41.8%) had an increase in Tc-99m MIBI uptake during ISDN infusion. Among them, 17 segments (30.4%) were normalized, 6 segments (10.7%) were significantly improved and 33 segments (58.9%) were improved. The degree of improvement in perfusion was related to the age of the myocardial infarction. In 13 patients with CABG, of 31 segments with improvement in perfusion post CABG, 25 segments (80.6%) showed perfusion improvement during ISDN infusion, and of 28 segments with improved wall motion post CABG, 23 segments (82.1%) showed improvement in perfusion during ISDN infusion. Tc-99m MIBI SPECT during ISDN infusion may therefore be a useful approach for assessing myocardial viability.

**Key words:** myocardial viability, myocardial infarction, Tc-99m MIBI SPECT, isosorbide dinitrate

### INTRODUCTION

A SIGNIFICANT AMOUNT of ischemic but still viable myocardium is a necessary condition for successful revascularization, including coronary artery bypass grafting (CABG) and percutaneous transluminal coronary angioplasty (PTCA). The detection of severe ischemic but viable myocardium in patients with myocardial infarction is very important for the further management of these patients.<sup>1</sup> F-18 FDG PET and Thallium-201 reinjection methods have been proven as techniques for the identification of myocardial viability.<sup>2-9</sup>

Received December 19, 1994, revision accepted August 21, 1995.

For reprint contact: Xiu-Jie Liu, M.D., Director & Professor, Department of Nuclear Medicine, Cardiovascular Institute and Fu Wai Hospital, CAMS & PUMC, Beijing, 100037, CHINA.

This work was supported by International Atomic Energy Agency. Contract No: 6907/RB.

Tc-99m MIBI myocardial SPECT has been clinically used for assessing coronary artery disease (CAD).<sup>10</sup> But the role of Tc-99m MIBI myocardial SPECT for the identification of myocardial viability is still under investigation.<sup>11-15</sup> Altchoefer et al.<sup>6</sup> have demonstrated that Tc-99m MIBI at rest underestimated the amount of viable myocardium by 23%. In order to improve the ability to detect myocardial viability by resting Tc-99m MIBI myocardial SPECT, a study of Tc-99m MIBI myocardial SPECT during isosorbide dinitrate (ISDN) infusion was performed in 37 patients with previous myocardial infarction.

### MATERIALS AND METHODS

#### *Patient population*

Thirty-seven patients (34 males and 3 females) with previous myocardial infarction who had undergone coronary angiography were studied. The mean age was  $57 \pm 7$

years (38–72 years). The location of myocardial infarction based on 12 leads ECG was defined as anterior in 20 patients, and infero-posterior wall in 25 patients. According to the infarction age, the patients were divided into three subgroups. Subgroup 1 consisted of 13 patients with an infarction age of  $\leq 30$  days, Subgroup 2 consisted of 11 patients with an infarction age ranging from 31 to 90 days, Subgroup 3 consisted of 13 patients with an infarction age ranging from 91 to 900 days. And thirteen patients had nuclear studies before and post-CABG. Resting Tc-99m MIBI and ISDN infusion Tc-99m MIBI SPECT were performed in 24 patients. Resting Tc-99m MIBI, ISDN SPECTs and radionuclide ventriculography (RVG) were performed in 13 patients pre-CABG and repeated resting MIBI SPECT and RVG post- CABG within 15 days.

#### Resting Tc-99m MIBI SPECT:

Resting Tc-99m MIBI SPECT was performed 1.5 hours after injection of 740 MBq of Tc-99m MIBI (Beijing Normal University, radiochemical purity,  $> 97\%$ ) with Toshiba 90B gamma camera equipped with a low energy all-purpose collimator. Thirty projections (40 seconds per projection) were obtained over a  $180^\circ$ , semicircular arc extending from the  $45^\circ$  RAO to the  $45^\circ$  LPO position. All images were acquired with a  $64 \times 64$  matrix and a zoom of 2.0. The images were reconstructed by the filtered back-projection method with a Shepp-Logan filter. The short-axis, horizontal long-axis and vertical long-axis slices were obtained.

#### Isosorbide dinitrate (ISDN) infusion imaging

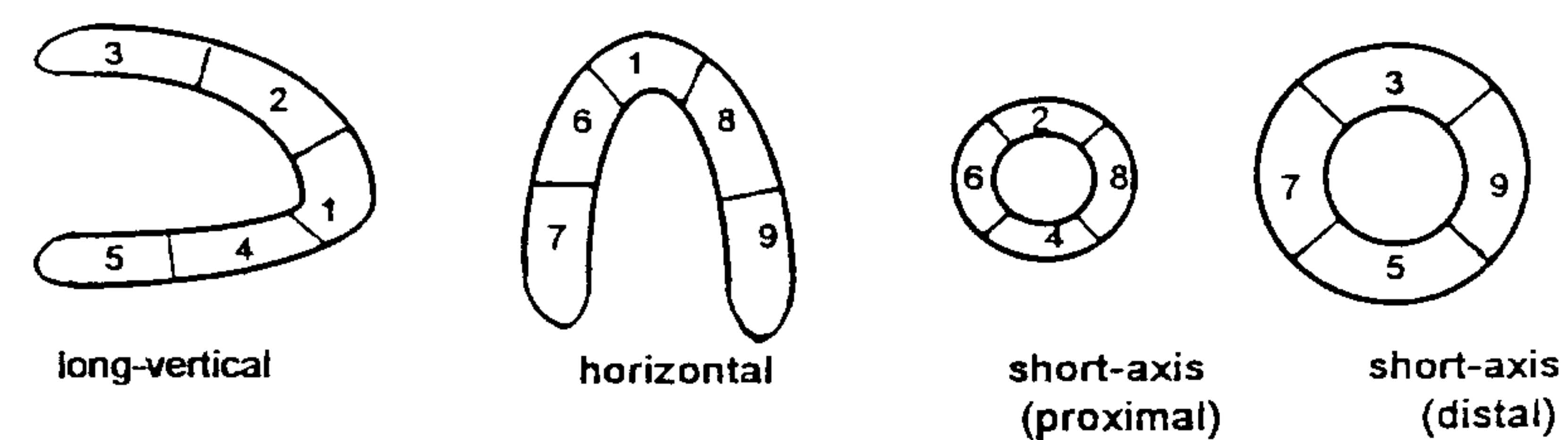
ISDN solution (Schwarz Pharma AG, Germany) was infused into the patient at a beginning dose of  $30 \mu\text{g}/\text{min}$ , then the infusion dose was gradually increased until the mean blood pressure dropped by  $1.33 \text{ kPa}^{17}$  and the dose was maintained for continued infusion for 20 min. The maintaining dose was  $90\text{--}450 \mu\text{g}/\text{min}$  (mean  $289 \pm 144 \mu\text{g}/\text{min}$ ). Thirty min after the initiation of ISDN infusion, a dose of 740 MBq Tc-99m MIBI was injected intravenously and ISDN infusion was continued for another 10 min. The tomographic data were acquired 1.5 hr after the injection of Tc-99m MIBI by means of the same protocol as for resting Tc-99m MIBI studies.

#### Wall motion analysis

Equilibrium radionuclide ventriculography was performed in 13 patients pre- and post-CABG. After *in vivo* labeling of red blood cells with 925 MBq of technetium-99m, imaging was obtained at anterior,  $30^\circ$  and  $70^\circ$  left anterior oblique views. Data were stored in a  $64 \times 64$  matrix. The left ventricular ejection fraction was calculated automatically and regional wall motion was assessed by radionuclide cine ventriculography.

#### Imaging interpretation

The left ventricle in the tomographic images was divided



**Fig. 1** The diagram of standard segmentation scheme used for scoring MIBI images in this study in the transverse slices, vertical long-axis and short-axis. 1 = apical; 2 = anterior; 3 = anterobasal; 4 = inferior; 5 = posterior; 6 = proximal septal; 7 = distal septal; 8 = proximal lateral; 9 = distal lateral.

into 9 segments: anterior, anterobasal, apical, inferior, posterior, proximal and distal septum, proximal and distal lateral wall (Fig. 1). Myocardial perfusion imaging was analyzed by three experienced nuclear medicine physicians on a 4-point scoring system: 0 = normal; 1 = moderate reduction of uptake, implying abnormality; 2 = severe reduction of uptake; 3 = absence of uptake. The criteria for evaluation of ISDN effects were defined as follows: if the initial score at a segment was dropped by two after the administration of ISDN, the perfusion of that segment was defined as significant improvement, and if the initial score dropped by one, that was defined as improvement.

#### Statistical analysis

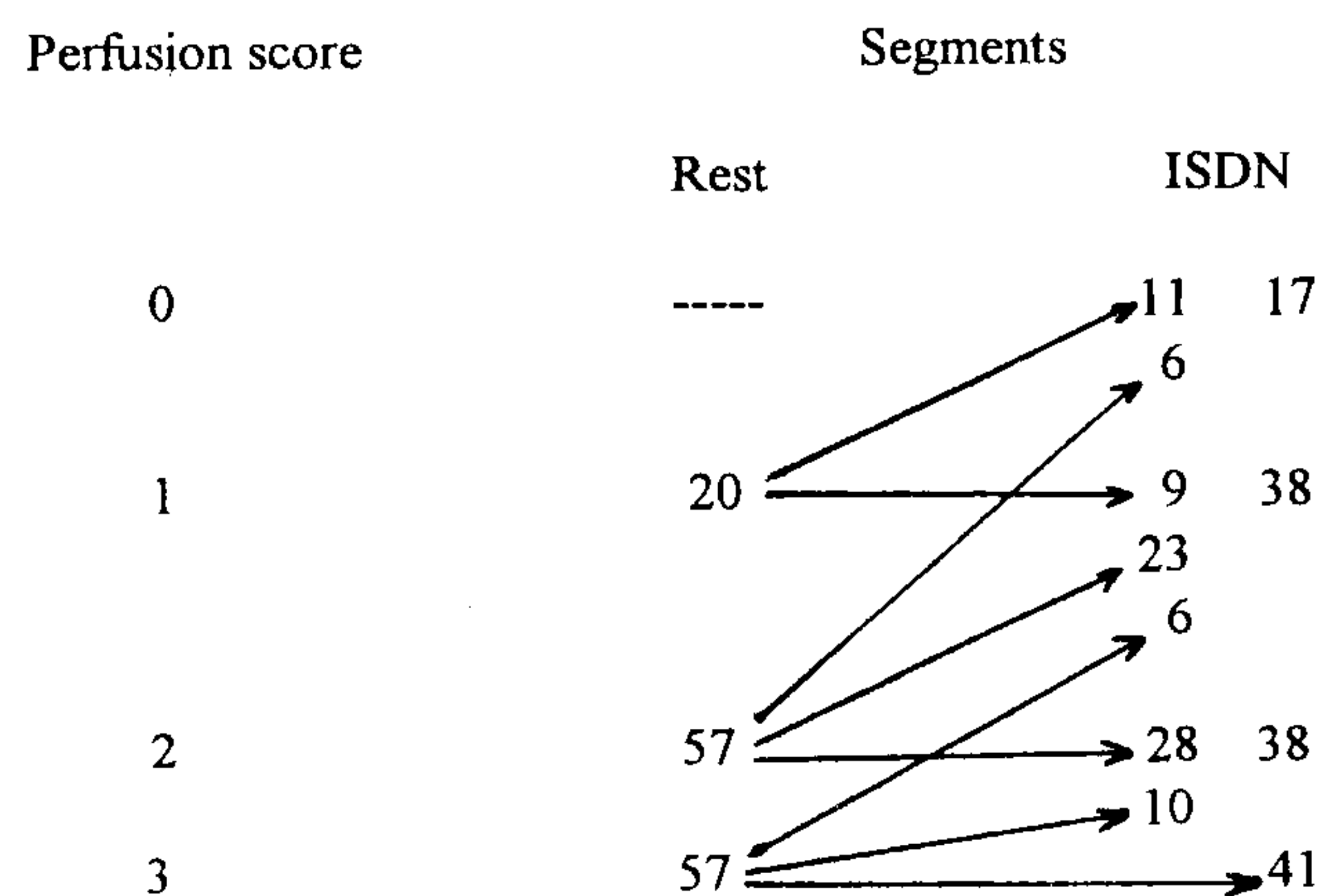
All data are presented as the mean  $\pm$  standard deviation (SD). Paired Student's t-test was employed to analyze the difference between the paired data. Chi square was used to determine the difference between the percentages for each two groups. A p value  $< 0.05$  was considered significant.

## RESULTS

### The results of the studies at rest and during ISDN infusion

Resting Tc-99m MIBI myocardial SPECT showed perfusion abnormalities in 134/333 (40.2%) segments. During isosorbide dinitrate infusion, Tc-99m MIBI SPECT showed that improvement in Tc-99m MIBI uptake was found in 56/134 (41.8%) segments. Out of 56 segments with Tc-99m MIBI perfusion improvement, 17 (30.4%) were completely normal, 6 (10.7%) were significantly improved and 33 (58.9%) were improved in Tc-99m MIBI perfusion (Fig. 2).

The improvement rate for Tc-99m MIBI perfusion during ISDN infusion in the three subgroups was 52.5%, 45% and 31.5%, respectively (Table 1). There was a significant difference in Tc-99m MIBI perfusion improvement between subgroup 1 (infarction age  $< 30$  days) and subgroup 3 (91–900 days) ( $p < 0.025$ ). There was no significant difference between subgroup 1 and subgroup 2 and subgroup 2 and subgroup 3.



**Fig. 2** The changes of myocardial perfusion at resting and during ISDN infusion in the 37 patients.

**Table 1** The changes of Tc-99m MIBI uptake in the three subgroups during Isosorbide dinitrate infusion

Tc-99m MIBI	subgroup 1 segments %	subgroup 2 segments %	subgroup 3 segments %
Perfusion improved	21/40 (52.5%)**	18/40 (45.0%)#	17/54 (31.5%)*##
Normalized	4/40 (10.0%)	4/40 (10.0%)	9/54 (16.7%)
Significantly improved	1/40 (2.5%)	1/40 (2.5%)	4/54 (7.4%)
improved	16/40 (40.0%)	13/40 (32.5%)	4/54 (7.4%)

\*\*p < 0.025, subgroup 1 vs. subgroup 3;

#NS, subgroup 1 vs. subgroup 2, subgroup 3 vs. subgroup 2

**Table 2** The changes of perfusion during ISDN infusion and post-CABG (compared to resting studies)

Tc-99m-MIBI uptake	During-ISDN	Post-CABG
Perfusion improved	30/57 (52.6%)	31/57 (54.4%)*
Normalized	9/57 (15.8%)	15/57 (26.3%)
Sig. improved#	6/57 (10.5%)	4/57 (7.0%)
Improved	15/57 (26.3%)	12/57 (21.1%)
Perfusion unchanged	27/57 (47.4%)	26/57 (45.6%)

\* NS, improvement between post-CABG and during ISDN,

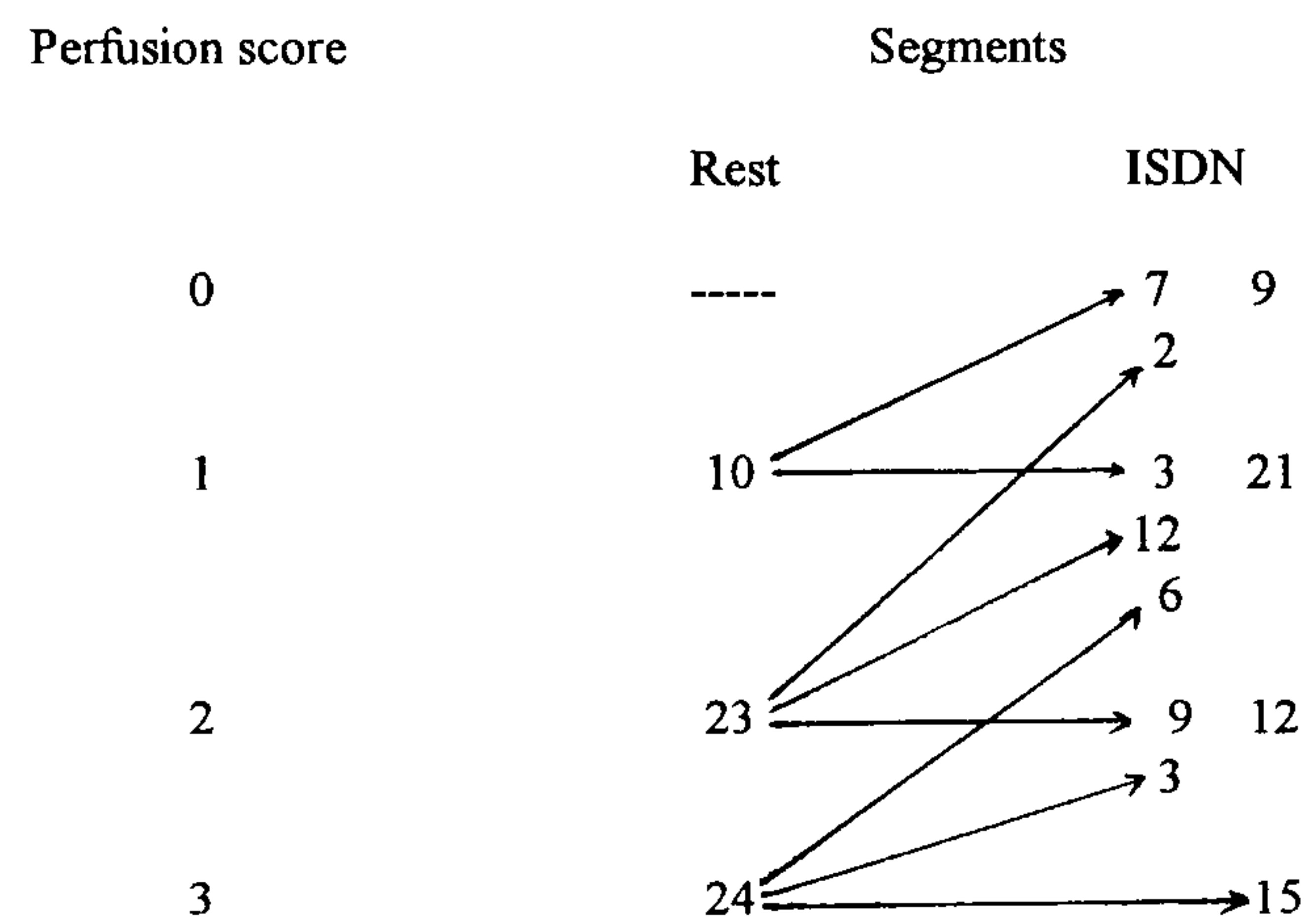
#Sig. improved = significantly improved

### The results of the studies in 13 patients who underwent CABG

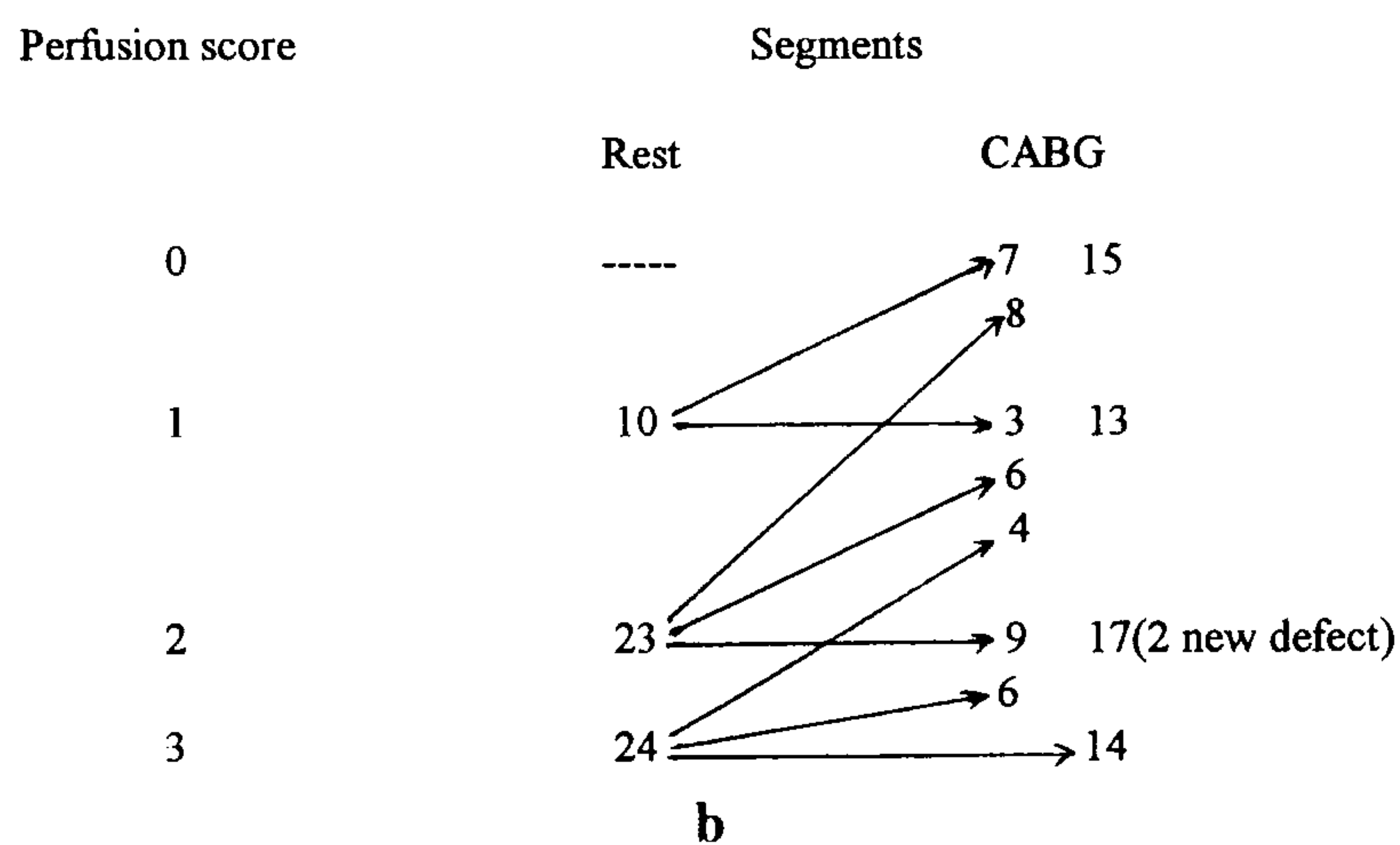
#### Myocardial perfusion imaging pre- and post-CABG.

**Pre-CABG:** Compared to resting studies, ISDN Tc-99m-MIBI SPECT showed that perfusion improved in 30/57 (52.6%) segments and was unchanged in 27/57 (47.4%) segments. Out of 30 segments with improved perfusion during ISDN infusion, 9/57 (15.8%) showed perfusion normal, 6/57 (10.5%) showed perfusion significantly improved and 15/57 (26.3%) segments showed perfusion improved (Fig. 3a).

**Post-CABG:** Compared to pre-CABG resting studies, Tc-99m MIBI SPECT revealed perfusion improved in 31/57 (54.4%) segments and unchanged in 26/57 (45.6%) segments. Out of 31 segments with perfusion improved, 15/57 (26.3%) segments showed perfusion normal, 4/57 (7.0%) segments revealed perfusion signifi-



a



b

**Fig. 3** The results of myocardial perfusion at resting and during ISDN (a), and that post-CABG (b) in the 13 patients.

cantly improved and 12/57 (21.1%) segments revealed perfusion improved (Table 2 and Fig. 3b). Among 31 segments with improved perfusion post-CABG, ISDN Tc-99m MIBI SPECT showed perfusion improved in 25/31 segments. The concordance between ISDN Tc-99m MIBI and post-CABG MIBI was 80.6%. Out of 26 segments with perfusion unchanged post-CABG, ISDN Tc-99m MIBI SPECT showed perfusion unchanged in 21 segments. The concordance between ISDN Tc-99m MIBI and post-CABG MIBI was 80.8% (Table 3).

#### Myocardial perfusion imaging vs. WM analysis post-CABG

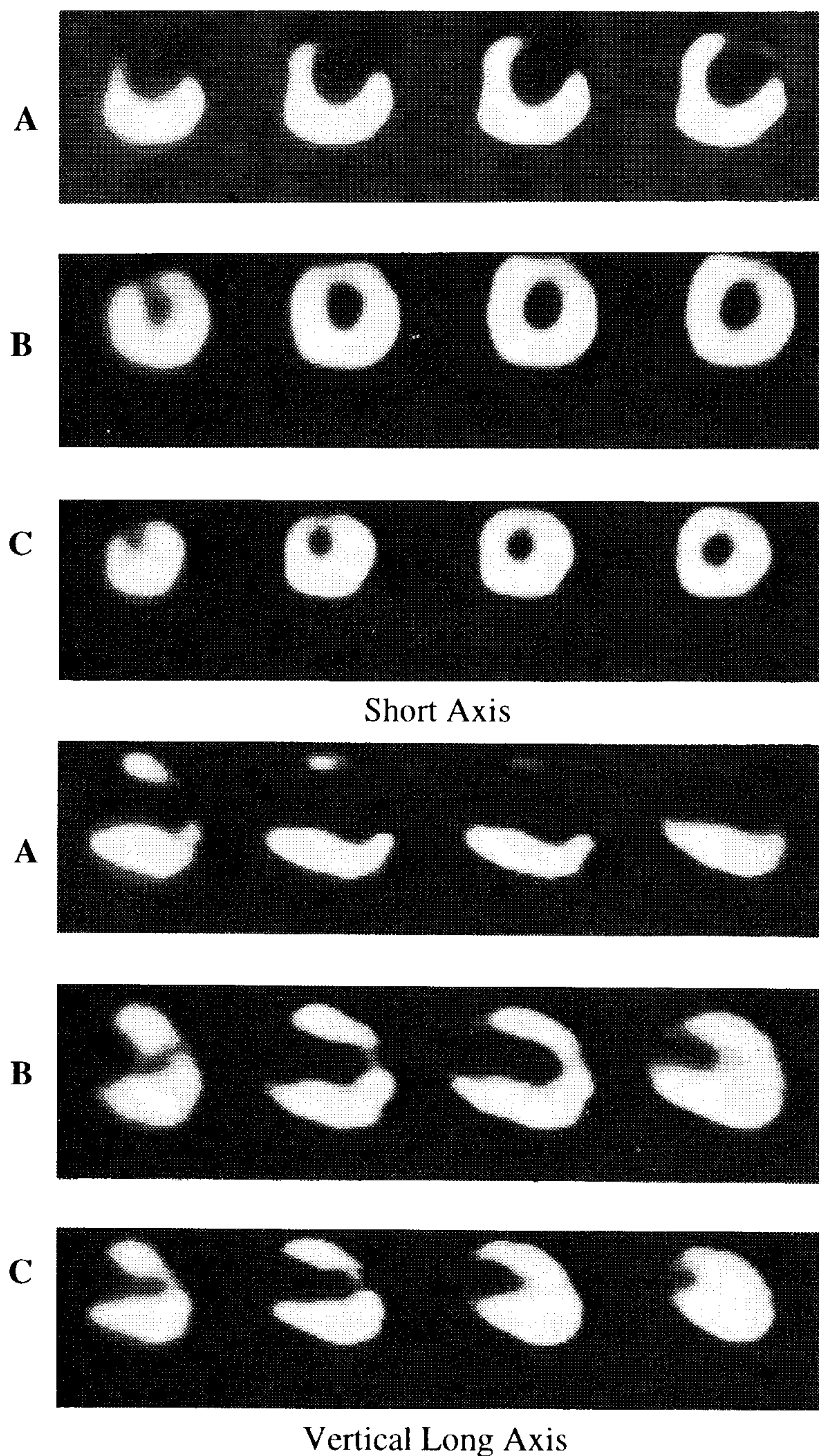
Post-CABG, regional wall motion was improved in 28 segments, of which, ISDN Tc-99m MIBI SPECT showed perfusion improved in 23 segments (82.1%) and unchanged in 5 segments (17.9%). Post-CABG regional wall motion was unchanged in 29 segments, of which ISDN Tc-99m MIBI perfusion was unchanged in 22 segments (75.9%), improved in 7 (24.1%, Table 3).

### DISCUSSION

To distinguish viable from non viable myocardium and to predict similar reversibility of regional wall motion abnormalities after revascularization in patients with myocardial infarction is of paramount importance for patient management. After revascularization of ischemic areas showing myocardial dysfunction, normal function can be

**Table 3** The comparison of changes of myocardial perfusion imaging Vs. analysis of wall motion post CABG

		Post-CABG			
		Improvement		Unchanged	
		Perfusion (31 segments)	WM (28 segments)	Perfusion (26 segments)	WM (29 segments)
ISDN infusion (pre-CABG)	Improvement	25	23	5	7
	Unchanged	6	5	21	22
Concordance		80.6%	82.1%	80.8%	75.9%



**Fig. 4** Tc-99m MIBI myocardial tomographic imaging obtained in a patient with previous myocardial infarction: at rest (A), during isosorbide dinitrate infusion (B) and post-CABG (C). At resting imaging, the MIBI uptake in anterior wall was diminished, and the uptake was significantly improved during ISDN infusion and post-CABG.

restored and the prognosis and quality of life will be improved. In contrast, revascularization of fibrotic myocardium will not lead to restoration of myocardial function and improvement of prognosis.

Thallium-201 has been used for more than 20 years in

the assessment of coronary artery disease, and recently the thallium-201 reinjection method has been used for the identification of myocardial viability.<sup>4-9,18</sup> But thallium-201 has significant disadvantages such as soft tissue attenuation and scatter caused by low photon energy emission and a relatively long half-life (73 hr) limiting the administration dose.

Tc-99m labeled Isonitriles have been used for myocardial imaging. Of the isonitriles, Tc-99m Sestamibi has the best properties for myocardial imaging, it has minimal lung uptake, transient liver uptake, and no or minimal myocardial redistribution. This combination of the properties makes it a better tracer for myocardial perfusion SPECT.<sup>19-21</sup> Tc-99m MIBI has been shown to be at least as good as thallium-201 for the assessment and management of patients with definite or suspected coronary artery disease.<sup>18,22-24</sup> Our previous data showed that the sensitivity and specificity of Tc-99m MIBI myocardial perfusion tomography for the detection of coronary artery disease were 96% and 87% respectively,<sup>10</sup> but the role of Tc-99m MIBI myocardial SPECT for predicting myocardial viability is still uncertain.<sup>11-15</sup> It has been demonstrated that Tc-99m MIBI myocardial uptake is proportional to regional blood flow in the physiologic range with enhanced extraction of the tracer in low flow regions where some tissue is still viable. However, the data have shown that resting Tc-99m MIBI substantially underestimated the amount of viable myocardium in comparison to thallium reinjection.<sup>2-9,18</sup> Our previous data have also demonstrated that Tc-99m MIBI myocardial SPECT at rest underestimated myocardial viability after myocardial infarction, 26.5% of regions in which reduced MIBI uptake at rest showed normal wall motion, and 43.1% of segments with defects of Tc-99m MIBI imaging had improvement in perfusion after CABG.<sup>25</sup> Cuocolo et al.<sup>4</sup> found that MIBI SPECT underestimated viable tissue in about 30% of segments which were viable on thallium reinjection. Landoni et al.<sup>26</sup> compared MIBI SPECT and F-18-FDG PET imaging in patients undergoing CABG. The results showed that there was a close relationship between FDG uptake prior to CABG and postoperation functional recovery, but MIBI was insufficient to predict the viable myocardium. Recently, He<sup>16</sup> has demonstrated that nitroglycerin can improve the efficiency of the thallium rein-

jection method in the detection of myocardial viability.

Tc-99m MIBI imaging during isosorbide dinitrate infusion was employed to assess myocardial viability in 37 patients with myocardial infarction. The results of this study showed that out of 134 abnormal perfusion segments at resting MIBI SPECT, 56 segments (41.8%) were improved in perfusion during ISDN infusion. Out of 56 segments with Tc-99m MIBI uptake improvement, 17 (30.4%) were recovered to normal, 6 (10.7%) were significantly improved and 33 (58.9%) were improved in Tc-99m MIBI uptake. There was a significant difference between the perfusion improvement for an infarction age < 30 days and an age > 90 days ( $p < 0.025$ ). The improvement rate for Tc-99m MIBI uptake during ISDN infusion declined with increasing infarct age. These data suggest that this approach may be useful for the detection of myocardial viability.

In 13 patients received coronary artery bypass grafting, Tc-99m MIBI showed 31 segments with improved myocardial perfusion post-CABG, of which 25 segments were improved during ISDN infusion with a concordance of 80.6%; in 26 segments there was unchanged myocardial perfusion post CABG, and of these 21 segments were unchanged during ISDN infusion with a concordance of 80.8%. Of the 28 segments with improvement in wall motion post-CABG, 23 (82.1%) segments showed an increase in uptake of MIBI during ISDN infusion. Of the 29 segments with unchanged wall motion post-CABG, 22 (75.9%) segments showed unchanged perfusion during ISDN infusion.

In conclusion, isosorbide dinitrate infusion may improve the uptake of Tc-99m MIBI in ischemic but viable myocardium and increase the sensitivity for detection of myocardial viability in patients with myocardial infarction.

## REFERENCES

1. Margonato A, Ballarotto C, Bonetti F, et al. Assessment of residual tissue viability by exercise testing in recent myocardial infarction: Comparison of the electrocardiogram and myocardial perfusion scintigraphy. *J Am Coll Cardiol* 19: 948-952, 1992.
2. Kiat H, Berman DS, Maddahi J, et al. Late reversibility of tomographic myocardial thallium-201 defects: an accurate marker of myocardial viability. *J Am Coll Cardiol* 12: 1456-1463, 1988.
3. Bonow RQ, Dilsizian V, Cuocolo A, et al. Identification of viable myocardium in patients with chronic coronary artery disease and left ventricular dysfunction. Comparison of thallium scintigraphy with reinjection and PET imaging with 18-fluorodeoxyglucose. *Circulation* 83: 26-37, 1991.
4. Cuocolo A, Pace L, Ricciardelli B, et al. Identification of viable myocardium in patients with chronic coronary artery disease. Comparison of thallium-201 scintigraphy with reinjection and technetium-99m methoxyisobutyl isonitrile. *J Nucl Med* 33: 505-511, 1992.
5. Dilsizian V, Marin-Neto JA, Arrighi JA, et al. Myocardial viability: comparison of thallium-201 reinjection, rest-stress

6. sestamibi, and positron emission tomography. *J Am Coll Cardiol* 19: 21A, 1992 (abstract).
6. Althoefer C, Kaiser HJ, Doerr R, et al. Fluorine-18 deoxyglucose PET for assessment of viable myocardium in perfusion defects in <sup>99m</sup>Tc-MIBI-SPECT: a comparison study in patients with coronary artery disease. *Eur J Nucl Med* 19: 334-342, 1992.
7. Marzullo P, Sambuceti G, Parodi O. The role of sestamibi scintigraphy in the radioisotopic assessment of myocardial viability. *J Nucl Med* 33: 1925-1930, 1992.
8. Taylor AM, Merhige ME. Detection of myocardial viability: sestamibi overestimates necrosis compared with thallium. *J Am Coll Cardiol* 21: 283A, 1993 (abstract).
9. Dondi M, Tartagni F, Faliani F, et al. A comparison of rest sestamibi and rest-redistribution thallium single photon emission tomography: possible implication for myocardial viability detection in infarcted patients. *Eur J Nucl Med* 20: 26-31, 1993.
10. Liu XJ, Wang XB, Gao RL, et al. Clinical evaluation of Tc-99m MIBI SPECT in the assessment of coronary artery disease. *Nucl Med Commu* 13: 776-779, 1992.
11. Sinusas AJ, Trautman KA, Bergin JD, et al. Quantification of area at risk during coronary occlusion and degree of myocardial salvage after reperfusion with technetium-99m methoxyisobutyl isonitrile. *Circulation* 82: 1424-1437, 1990.
12. Berman DS, Kiat H, Van Train KF, et al. Comparison of SPECT using technetium-99m agents and thallium-201 and PET for the assessment of myocardial perfusion and viability. *Am J Cardiol* 66: 72E-79E, 1990.
13. Beller GA, Watson DD. Physiological basis of myocardial perfusion imaging with the technetium 99m agents. *Semin Nucl Med* 21: 171-181, 1991.
14. Liu P. New technetium 99m agents: Promising windows for myocardial perfusion and viability. *Am J Cardiac Imag* 6: 28-41, 1992.
15. Meerdink DJ, Leppo JA. Myocardial transport of hexakis (2-methoxyisobutylisonitrile) and thallium before and after coronary reperfusion. *Circ Res* 66: 1738-1746, 1990.
16. He ZX, Barcourt J, Guignier A, et al. Nitrate improve detection of ischemic but viable myocardium by thallium-201 reinjection SPECT. *J Nucl Med* 34: 1472-1477, 1993.
17. Maseri A. The role of nitrates in the treatment of spontaneous angina pectoris. In NITRATES '84—Analysis and Perspectives Eur Congress Cardiol pp. 85-95, 1984.
18. Tailleffer R, Lambert R, Essianbie R, et al. Comparison between thallium-201, technetium-99m sestamibi and technetium-99m teboroxime planar myocardial perfusion imaging in detection of coronary artery disease. *J Nucl Med* 33: 1091-1098, 1992.
19. Holman BL, Jones AG, Lister-James J, et al. A new Tc-99m labeled myocardial imaging agent, hexakis(t-butyl-isonitrile)-technetium(1) (Tc-99m-TBI): initial experience in the human. *J Nucl Med* 25: 1830, 1984.
20. Liu XJ, Wang XB, Lahiri A, et al. Tc-99m CPI. *Drugs of the Future* 15: 883, 1990.
21. Liu XJ, Wang XB, Liu YZ, et al. The experimental and clinical studies of Tc-99m MIBI myocardial imaging: compared with Tc-99m CPI. *Chin J Nucl Med* 9: 129, 1989.
22. Iskandrian AS, Heo J, Kong B, et al. Use of technetium-99m isonitrile (RP-30A) in assessing left ventricular perfusion

- and function at rest during exercise in coronary artery disease and comparison with coronary arteriography and exercise thallium-201 imaging. *Am J Cardiol* 64: 270–275, 1989.
23. Canby RC, Silber S, Pohost GM, et al. Relations of the myocardial imaging agents Tc-99m MIBI and thallium-201 to myocardial blood flow in a canine model of myocardial ischemic insult. *Circulation* 81: 289–296, 1990.
  24. Meerdink DJ, Leppo JA. Comparison of hypoxia and ouabain effects on the myocardial uptake kinetics of technetium-99m hexakis 2-methoxyisobutyl isonitrile and thallium-201. *J Nucl Med* 30: 1500–1506, 1989.
  25. Liu XJ, Li ST, Lu ZL, et al. Clinical evaluation of myocardial viability using Isoket infusion and Tc-99m MIBI myocardial SPECT. World Chinese Conference of Nuclear Medicine, Wuxi, China, Aug 8–11, p. 33, 1993.
  26. Landoni C, Lucignani C, Paolini G, et al. Identification of hibernating myocardium with PET/FDG and SPECT/MIBI in patients undergoing coronary artery bypass. *Eur J Nucl Med* 19: 571, 1992 (abstract).