

Experimental and Clinical Applications of MR Contrast Agents

1

PRINCIPLES AND ABDOMINAL APPLICATION OF MRI CONTRAST MEDIA. I. Mano and M. Iio, Toshiba Central Hospital and Tokyo University School of Medicine, Tokyo

Contrast media for MRI play a similar role to those for X-ray CT, in order to obtain additional information not available from conventional pulse sequence. Numerous MRI contrast media are undergoing study. Table 1 indicates representative contrast media which have been so far reported.

We have tried a gas-injection method for identification of digestive organs and an intravenous Gd-DTPA injection method for contrast of abdominal tumors. Interesting resultant findings will also be reported. Fig. 1 shows a case of hepatoma, whereby two different contrast media are proved to be effective.

Table 1. MRI Contrast agent

1. Vessel Administration
NSFR, $MnCl_2 \cdot O_2$
Gd-DTPA & its Modifications
Fe-EHPG (Hepatobiliary syst.)
 Fe_3O_4 particle (RES system)
Metallo-porphyrin
Liposome (microsphere)
Monoclonal antibody

2. Oral Administration
Gas, Mineral oil, Ferric
substance

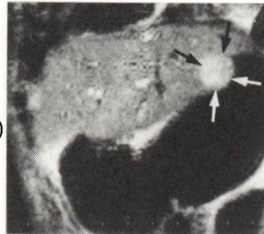


Fig. 1. Hepatoma (arrow) enhanced by Gd-DTPA. Note the effect of gas in the stomach.

2

CLINICAL EXPERIENCE OF GD-DTPA IN BRAIN TUMORS. Y. Inoue Osaka City University Medical School, Osaka

Although magnetic resonance imaging (MRI) is important new imaging modality for lesions of central nervous system, it does not allow consistent differentiation of cerebral edema from gliomas. Gadolinium diethylenetriamine pentaacetic acid (Gd-DTPA) is a strongly paramagnetic, stable complex which reduces hydrogen proton relaxation times even in low concentrations. The pharmacokinetic behavior of intravenous Gd-DTPA is similar to the well known iodinated contrast agents used in contrast computed tomography (CT). On contrast brain CT scans, there is an increase in density of an area of abnormalities of blood brain barrier (BBB) as well as large vessels, dura, choroid plexus and pituitary gland. MRI with Gd-DTPA shows an increase in the areas of absence or abnormalities of BBB, particularly on T1 weighted images, but no enhancement of blood vessels or dura matter because of blood flow, or probable lack of mobile hydrogen proton, respectively. On our experiences of 25 patients with brain tumors, the margin between glioma and peritumoral edema which was unclear on plain MRI, was well delineated with contrast MRI to the degree possible with contrast CT.

3

MRI OF CEREBRAL INFARCTION----CONTRAST ENHANCEMENT WITH Gd-DTPA AND ITS CLINICAL USEFULNESS. S. Imakita. Department of Radiology, National Cardiovascular Center, Suita-shi, Osaka

It has been recognized that MRI is useful for detecting cerebral infarction. We reported that T2-weighted image was useful for detecting infarcted areas. We evaluated the contrast enhancement with Gd-DTPA and its clinical usefulness. Fifteen patients with cerebral infarction were studied 24 times using 1.5 tesla superconducting MRI unit (SIEMENS, MAGNETOM H15) with spin-echo pulse sequence. Spin-echo (SE) axial images were obtained with SE(2000/30,90) and SE(400-500/30). Initially, images were obtained with SE(2000/30,90) followed immediately by SE(400-500/30). After these baseline sequences were obtained, each patient was intravenously administered 0.1-0.15 mmol/kg of Gd-DTPA. Imaging was resumed 5 minutes after injection of Gd-DTPA; images were sequentially obtained mainly with SE(400-500/30).

In 2 cases aged 4 hrs and 27 months after onset of the disease, there was no enhancement with Gd-DTPA. There was faint enhancement in 2 cases aged about 24 hrs and marked enhancement in 20 cases aged 1 week to 1 month. Most cases demonstrated gradual increase of signal intensity after injection of Gd-DTPA, but some cases demonstrated relatively rapid wash-out of Gd-DTPA. Compared with contrast CT, MRI using Gd-DTPA demonstrated more obvious enhance-

ment of infarcted areas. In the case of multiple cerebral infarction, MRI using Gd-DTPA could differentiate fresh focus from old one, because of its obvious enhancement. MRI using Gd-DTPA showed similar pattern of enhancement to contrast CT, though the former demonstrated infarcted areas more obviously than the latter. From the animal experiment of acute cerebral ischemia using Gd-DTPA, MacNamara et al. concluded that the change of signal intensity of enhanced infarcted areas was caused by the state of blood brain barrier breakdown, collateral circulation, the compression of the capillary bed by vasogenic edema and so forth. In our clinical study, marked enhancement was recognized in subacute stage. From this fact, it was suggested that the development of collateral circulation and reduction of edema greatly affected the positive effect of contrast enhancement with Gd-DTPA.

In cerebral infarction, Gd-DTPA was useful for detecting fresh focus, and it was suggested that Gd-DTPA had a supplementary role in evaluating the dynamics of circulation.