

17

AN EXPERIENCE WITH NEWLY DEVICED PEDIATRIC ECT BED.

I. Ohwaki, M. Kobayashi, A. Fujii, A. Kojima, H. Ishida and K. Ishii. Tokyo Metropolitan Kiyose Childrens Hospital and Kitasato University.

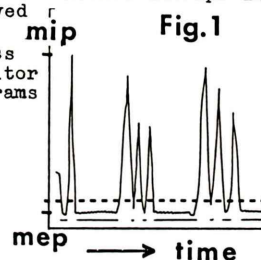
Adult instruments are usually used for pediatric experimentation. To obtain good results in infants and children, however there are many drawbacks. In SPECT examination using rotation-type gamma camera, the size of normal bed is so wide for children. The efficiency is not satisfactory. We made an ECT bed which was 20cm wide, and had 7cm smaller radius than that of the normal bed, and was attached an instrument for fixing the children. Using this new SPECT bed, we could get better SPECT image and shorten the time of the examination.

18

BREATHING OBSERVATION MONITOR FOR LIVER SCINTIGRAM.

T. Horibe, H. Horibe. Nagoya University Hospital Branch, Aichi. Y. Hidaka. Aichi Diagnostic Foundation, Aichi. T. Seko, H. Matsuoka. Asahirousai Hospital, Aichi. Y. Yano. Shimadzu, Aichi.

Abdominal scintiscan has some problems due to the motion artifact induced by breath-natured shift of abdominal viscera. And the instrument also worked well by using it as a patient's breathing observation monitor and we hereby report what we studied through the experiment mentioned above. Patient's breathing have been monitored through air-bag detector and have been transduced to electric signal (out put max 1 V). Out put signal level were divided into 100 steps and it was planned to be able take the trigger as in Fig. 1. In trigger level 150 mV, the liver shadow and the contour of the liver become more clear further more the distribution of radio-active isotope in liver could be observed more clearly. We will discuss the usefulness of the breathing monitor of the liver scintigrams in this paper.



19

IMPROVEMENTS AND APPLICATIONS OF HUMAN GAMMA CAMERA. H. Takano and M. Kaneko. Dept. of Dental Radiology, Higashi-Nippon-Gakuen Univ. Ishikari-Tobetsu, Hokkaido.

For the purpose of applying a human gamma camera to small animals such as rats or mice, simple and easy improvements were brought on a pinhole collimator, for example a small pinholed lead block (the pinhole was 1.5mm in diameter) was attached to the inside of a human pinhole collimator.

In basic experiments using Tc-99m sodium pertechnetate, a small circled hot images of at least 1.0mm in diameter could be shown clearly. And two slender tubes (outer diameter was about 0.9mm), which were laid at intervals of 2.0mm, could be distinguished.

Furthermore, bone scintigraphy, salivary gland scintigraphy and thyroid scintigraphy in rats and mice were attempted using this collimator improved. Clear images of all were obtained.

In addition, the experiments using the radionuclide emitted higher energy gamma rays were attempted.

20

THE EXAMINATION OF GLYCINE-1-¹³C-CHOLATE BREATH TEST USING INFRARED ANALYZER-CLINICAL APPLICATION.

N. Nakagawa, T. Suzuki, H. Ohara, N. Yukitake, S. Takahashi and K. Someya. St. Marianna Univ. School of Medicine, Kawasaki. Y. Sasaki. Gumma Univ, Maebashi.

The ¹³C-breath test is useful for clinical diagnosis of detecting some malabsorption syndromes. In the condition of bacterial over growth, administered glycine-1-¹³C-choleate are decoujugated 1-¹³C-Glycine in the intestine and it flow out to ¹³CO₂ Expired air after absorbed and metabolized. This time, we bring this test to a 53 years old female patient who was diagnosed Progressive Systemic Sclerosis (P.S.S.) with Sjögren's syndrome, had chife complains of constipation and dysuria, manifested anemia, hypoalbuminemia and hypocholesterinemia. During fasting time, we measured the ¹³CO₂ in expired air after administered glycine-1-¹³C-choleate 310mg at 30min. interval. The ¹³CO₂ expired curve after administered of ¹³C-compound demonstrated flat line. Clinical symptom and laboratory data of this patient was indicated bacterial over growth in alimentary tract. But we could not detect bacterial over growth in this case. This result may be due to the problem of expired air collection and the hypokinesia of the alimentary tract in this patient.