

67

THE MEASUREMENT OF SEQUENTIAL CHANGES IN CEREBRAL BLOOD FLOW AND OXYGEN METABOLISM WITH VARIOUS INTERVENTIONS USING O-15 LABELED GASES. S.Tanda, Y.Yonekura, M.Senda, N.Tamaki, K.Nishimura, H.Saji, T.Fujita, J.Konishi, A.Kobayashi, W.Taki, M.Ishikawa, Y.Yonekawa, H.Handa, and K.Torizuka. Kyoto University Medical School, Kyoto.

The purpose of this study is to evaluate the feasibility to measure sequential changes in cerebral blood flow (CBF) and oxygen metabolism (CMRO₂) following various loadings by positron CT (PCT). Functional images of CBF and CMRO₂ were obtained using continuous inhalation of O-15 labeled CO₂ and O₂. In the cases with hydrocephalus after subarachnoid hemorrhage, the spinal drainage of CSF resulted in the rapid changes in depressed CBF and CMRO₂ with more prominent increase of CMRO₂. The changes in CBF and CMRO₂ were studied with drip infusion of 10% glycerol solution. Glycerol loading showed the rapid increase of depressed CBF and CMRO₂, while normal CMRO₂ was unchanged. In the cases with cerebrovascular disease, the changes in CBF and CMRO₂ were studied with inhalation of 5% CO₂. CO₂ loading showed the increase in CBF, while poor regional increase was observed in "moyamoya" disease, which indicated impaired vascular response to the elevation of plasma CO₂.

Our preliminary work suggested the potential usefulness of sequential PCT to study the changes in CBF and CMRO₂ against various interventions.

69

REGIONAL BRAIN WORKS UNDER SENSORY DEPRIVED AWAKE CONDITION. A STUDY USING HIGH RESOLUTION HEADTOME III AND F-18 -FDG. K.Uemura, K.Tazaki*, T.Ogawa, F.Shishido, T.Yamaguchi, A.Inugami, K.Tagawa. Research Institute for Brain & Blood Vessels-AKITA, Tohoku University, School of Medicine*.

In the physiological condition, regional brain works are always coupled to the regional cerebral blood flow and the regional energy metabolism. For evaluation of the regional brain work under sensory stimulation using this principle, a strict control study, i.e. the PET study under the sensory deprived awake condition is essential. We have been carried out the study using a high resolution Headtome III (FWHM=6.5 mm) and F-18-fluorodeoxyglucose on three normal volunteers. A EEG was also recorded on the each subject during the 18-FDG accumulation in the brain tissue.

Generally, under noise and light of the examination room, regional glucose metabolism of the brain was distributed almost homogeneously and slightly increased in the primary sensory cortices. On the other hand, under the sensory deprived awake condition, significant decrease of glucose metabolism was found in the temporo-parieto-occipital regions, the thalamus and the cerebellum, and increased metabolism was recognized in the frontal cortex and the gyrus cinguli. The functional morphology of these findings and correlation with sensory stimulation will be discussed.

68

HUMAN CEREBRAL C-11-GLUCOSE METABOLISM DURING SLEEP. K.Uchida, N.Okudaira*, T.Ashitaka, Y.Yamashiro, K.Kawata, H.Nukada, Y.Fukushima, S.Torii*, T.Suzuki** and M.Iio**.

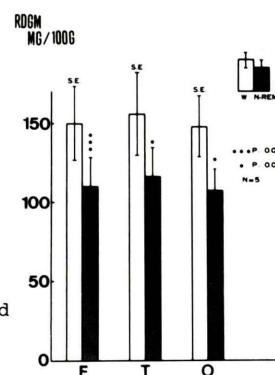
2nd Dept. of Int. Med., *Dept. of Physiol., Toho University School of Medicine and

** Nakano National Chest Hospital in Tokyo.

To investigate the cerebral glucose metabolism during wakefulness and sleep, five healthy males were administered C-11-glucose solution orally, or through the duodenal tube. Positron emission tomography was done concurrently with polysomnography. For the measurements of the regional distribution of the glycolytic metabolites (RDGM), blood samples were drawn and counted the C-11 activity.

Result: A significant reduction of the RDGM during non rapid eye movement (NREM) sleep in the frontal, temporal and occipital cortices were, 26.4, 25.5 and 27.8% respectively, compared to the wakefulness state (Fig).

Conclusion: Human cerebral RDGM significantly decreased during NREM sleep than that of during wake state.



70

REGIONAL CEREBRAL BLOOD FLOW AND OXYGEN UTILIZATION IN ALZHEIMER DISEASE DETERMINED BY THE O-15 STEADY STATE TECHNIQUE. H.Shinotoh, M.Kawamura, T.Yamasaki, Y.Tateno, K.Suzuki, K.Tamata, M.Kuchiki, K.Kodama, S.Tamachi. National Institute of Radiological Sciences, Chiba University School of Medicine, Matsudo Municipal Hospital, Chiba.

Alzheimer disease is characterized by relatively rapid progression and frequent manifestation of neuropsychological abnormalities. To study the correlation of clinical features with regional cerebral metabolic alterations in Alzheimer disease, we studied three cases of Alzheimer disease using the O-15 Steady State Technique and compared with two cases of vascular dementia and five young normals. All three cases of Alzheimer disease showed constructional apraxia, visuospatial disorientation and dressing apraxia but none of the cases of vascular dementia showed them. Two cases of Alzheimer disease showed marked parallel decrease of rCBF and rCMRO₂ of bilateral frontal and temporoparietal association cortex with relative sparing of primary sensorimotor cortex, basal ganglia, thalamus and occipital lobe. One rapidly progressive case showed general decrease of rCBF and rCMRO₂. One of the cases of vascular dementia showed focal and asymmetrical decrease of rCBF and rCMRO₂. Further studies are needed to determine regional metabolic alteration in Alzheimer disease in various stages.