

《原 著》

Place of Ga-67 scans to assess relapse in patients with esophageal carcinoma

Makoto KONDO*, Shigeru KOSUDA*, Atsushi KUBO*, Minoru UEMATSU*,
Noriko OHIGASHI*, Hidekazu MASAKI** and Shozo HASHIMOTO*

*From the Department of Radiology, Keio University School of Medicine

**Present Address: The Department of Radiology, National Children's Hospital

ABSTRACT This study evaluated the role of Ga-67 scans to detect relapse after curative therapy in patients with esophageal carcinoma. Of 37 patients, 30 died subsequently: 19 patients had histological confirmation of relapse, and the other 11 patients showed strong evidence of relapse on clinical evaluation until death. Of the 30 patients who died, 21 had abnormal Ga-67 scans predicting the presence of relapse. Of 16 patients with negative Ga-67 scans, seven patients were alive without evidence of relapse for more than six months after Ga-67 scanning. Most of the relapses were clinically evident, and survival of the patients who relapsed was short. Effort to detect relapse in earlier stages may increase the number of false positives. Although the machine used for this study was scintiscanner and the number of the patients was relatively small, routine use of Ga-67 scans for following up treated esophageal carcinoma patients may be not cost-effective.

Introduction

After curative therapy of esophageal carcinoma, it is often difficult to prove relapse noninvasively; relapse tends to occur in the mediastinum and/or upper abdomen, where physical and x-ray examinations are frequently invalid (1), and previous surgical reconstruction using the stomach or colon may make Ba examination unreliable.

Ga-67 scans are useful for initial evaluation of patients with esophageal carcinoma (2-4). Thus, we undertook the study to see whether Ga-67 scans can contribute to evaluation of the post-treatment status in patients with esophageal carcinoma.

Materials and Methods

A total of 41 patients after curative therapy for esophageal carcinoma was entered to this study.

Patients with progressive or persistent tumors after radiotherapy alone were not included. Subsequently, four patients were excluded from the study; two died of intercurrent disease without autopsy, and two were lost to follow-up. Of the other 37 patients, 25 were treated with pre-operative radiotherapy and surgery, seven with radiation alone, and five with surgery alone. Post-treatment follow-up examinations included physical examinations, laboratory studies, chest x-ray and Ba examination. Oral FT-207 was given for 17 patients after surgery and/or radiation.

Anterior and posterior scans of the neck, chest and upper abdomen were obtained 48-72 hours after administration of 2 mCi (74 MBq) of Ga-67 citrate. Scanning was done with a Toshiba dual-probe rectilinear scanner with 12.7 cm NaI crystals, using medium-energy collimators (focal depth: 10 cm). Our previous experience with untreated esophageal carcinoma patients showed that Ga-67 uptake equal to or more than that of the liver had very few false positives concerning detection of extraesophageal spread and metastases. Therefore, in this study, Ga-67 uptake equal to or more than that of the liver was defined as positive.

受付: 57年5月25日

最終稿受付: 57年8月3日

別刷請求先: 新宿区信濃町35 (〒160)

慶応義塾大学医学部放射線科

近 藤 誠

Table 1 Ga-67 scans in 37 treated patients with esophageal carcinoma

Ga-67 finding	19 patients with histologically confirmed relapse	11 patients with relapse without histological confirmation	7 patients alive and well
Positive	14 [#]	7 [†]	0
Negative	5	4	7

[#] A total of 17 sites: 8 in the mediastinum, 3 in the lung, 3 in the bone, one in the hilum, one in the upper abdomen, and one in the chest wall.

[†] A total of 10 sites: 3 in the lung, 2 in the mediastinum, 2 in the upper abdomen, one in the hilum, one in the supraclavicular region, and one in the bone.

Results

Of the 37 patients, 21 had positive Ga-67 scans. Of the 37 patients, 30 died; 19 had histological confirmation of relapse, including 15 with autopsy and four with biopsy; 11 died without histological confirmation of relapse. Clinically, the causes of death in these 11 patients were those of relapsed esophageal carcinoma, having progressively increasing cervical, supraclavicular and/or mediastinal tumors, increasing coin lesions on chest x-ray, bone destruction, etc. Therefore, assumption was made for the 11 patients to have relapse at the time of Ga-67 scanning. The other seven patients were alive with no evidence of relapse for more than six months after Ga-67 scanning. They were thought to have no relapse at the time of Ga-67 scanning, considering a progressive nature of relapsed esophageal carcinoma, if present.

Of the 19 patients with histologically verified relapse, 14 had positive Ga-67 scans for a total of 17 sites (Table 1). These all sites were proved to have relapsed tumors histologically. Most of these tumors were also clinically evident by coin lesions on chest x-ray, mediastinal widening, recurrent laryngeal nerve palsy, passage obstruction, bone pain, bone destruction, and/or superficial tumors. Of the 17 sites with Ga-67 positivity, only two were not clinically suspected; one at the upper abdomen, and one at the middle mediastinum (Fig. 1). Of five patients with histologically proved relapse and negative Ga-67 scans, all were strongly suspected to have relapse based on clinical findings, like appearance of recurrent laryngeal nerve palsy, bloody sputa, increasing abdominal pains, or progressive emaciation.

Of the 11 patients died without autopsy, seven patients showed positive Ga-67 scans in a total of

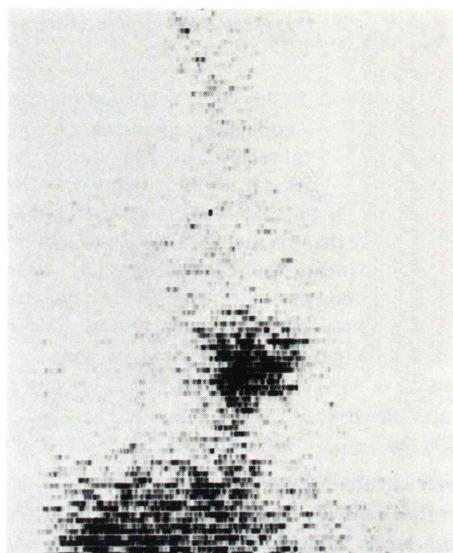


Fig. 1 A case treated with radiation and surgery. Ga-67 uptake shows recurrence in the middle mediastinum, which was not suspected before Ga-67 scans.

10 sites. Of these 10 sites, all were strongly suggestive of having relapse based on clinical findings. The other four patients had negative Ga-67 scans despite of having signs of relapse such as increasing supraclavicular or cervical hard fixed tumors, or recurrent laryngeal nerve palsy.

Of the seven patients alive and well for more than six months after Ga-67 scanning, none showed positive findings on Ga-67 scans. Although having some complaints at the time of Ga-67 scanning, these seven patients were less symptomatic than those who died; one developed supraclavicular lymph nodes, which were subsequently found due to tuberculosis, and six complained of vague and not site specific symptoms such as

Table 2 Survival before and after Ga-67 scans

Group of patients	No. of patients	Period between treatment and Ga-67 scans (Mo)		Survival after Ga-67 scans (Mo)	
		Mean	Median	Mean	Median
Died of relapse (histologically confirmed)	19	10.1	9	4.0	3
Died of relapse (histologically not confirmed)	11	12.0	6	3.5	2
Alive and well	7	14.7	17	15.0	18

appetite loss, general fatigue, etc.

Survival of patients of each group is listed in Table 2. There are no observed differences between patients who died with or without histological verification. Only one patient of both groups lived more than one year. In contrast, four of seven patients who were alive and well were followed for more than 18 months.

Discussion

In this study, positive Ga-67 scans appeared in 14 of 19 patients who relapsed and with histological confirmation, giving a sensitivity of 74%. Combining patients without histological verification, 21 of 30 patients who died showed positive Ga-67 scans (sensitivity: 70%). Since all seven patients considered to have no relapse did not show positive Ga-67 scans, a specificity is 100%. The modest sensitivity with high specificity to detect lesions was also noted in untreated patients with esophageal carcinoma (2, 3), possibly because of using strict criteria that Ga-67 uptake equal to or more than that of the liver was denfied as positive.

From this study, however, it was not concluded that Ga-67 scans were of value to detect relapse, since only two of 19 patients with histological verification had Ga-67 uptake at the sites which were not suspected to have tumors based on routine examinations and symptoms. Moreover, all patients who relapsed had progressively deteriorated, and few lived more than one year after Ga-67 scanning. Since there are no effective treatment methods in patients with relapsed esophageal carcinoma, it is of little significance to detect relapse at such stages.

Since Ga-67 readily accumulates in the bones while the mediastinum often shows diffusely increased activity, only an apparent localized increase in activity was interpreted as a positive result. In order to detect relapse using Ga-67 scans in early stages and in an asymptomatic phase, it may be necessary to change the criteria to interpret equivocal accumulation as a positive. However, effort to detect less advanced tumors may increase the number of false positives. Since the machine used for this study was a rectiscanner and the number of the patients was relatively small, further study using a gamma camera may be warranted. Ga-67 scans should be obtained frequently in order to detect relapse in an asymptomatic phase, while Ga-67 scans cost very high. Moreover, it is not clear whether early detection of relapse of esophageal carcinoma will salvage patients who relapse. Routine use of Ga-67 scans for following up treated patients with esophageal carcinoma may not be cost-effective.

Since the sensitivity and specificity of Ga-67 scans to predict relapse, and the effectiveness of salvage therapy after relapse may vary according to sites of origin and types of histology (5), values of Ga-67 scans after therapy of other tumors should be tested further.

References

- 1) Yrjänä J: The posterior tracheal band and recurrent esophageal carcinoma. *Radiology* **136**: 615–618, 1980
- 2) Kondo M, Hashimoto S, Kubo A, et al: ⁶⁷Ga scanning in the evaluation of esophageal carcinoma. *Radiology* **131**: 723–726, 1979
- 3) Kondo M, Ando N, Kosuda S, et al: Ga-67 scan in patients with intrathoracic esophageal carcinoma

- planned for surgery. Cancer **49**: 1031-1034, 1982
4) Pearlman AW: Gallium imaging in cancer of the esophagus. Clin Nucl Med **8**: 380-383, 1981
5) Brown ML, O'Donnell JB, Thrall JH, et al:

Gallium-67 scintigraphy in untreated and treated non-Hodgkin lymphomas. J Nucl Med **19**: 875-879, 1978

要 旨

食道癌の再燃と Ga-67 スキャンの役割

近藤 誠* 小須田 茂* 久保 敦司* 植松 稔*
大東 紀子* 正木 英一** 橋本 省三*

* 慶応義塾大学医学部放射線科 ** 現 国立小児病院放射線科

根治治療後の食道癌症例において Ga-67 スキャンを施行し、寄与を調べた。37例中30例は後に死亡し、組織学的にもしくは臨床的に死因は食道癌の再燃によると考えられた。30の死亡例のうち、21例は再燃部位を示唆する Ga-67 の異常集積像を示した。Ga-67 スキャンで異常の見つからなかった16例中7例は Ga-67 スキャン後6か月以上再燃の徴なく健存である。

再燃部位のほとんどは他の臨床検査手段によって明らかであり、再発患者の生存期間は短い。

より早期に再燃を発見しようとする努力は、無病誤診率をも上昇させるかもしれない。

本研究で使用した機械はシンチスキャナーで、症例数も限られているが、Ga-67 スキャンを食道癌症例の経過観察にルーチンに使用するのには、費用・効果比から見て有益ではないと思われた。

Key words: Radionuclide Scan, Gallium-67 Citrate, Esophageal Carcinoma.