《原　著》

Adrenal Scintigraphy Using ^{123}I Labeled 6β-Iodomethyl-19-Norcholest-5(10)-EN-3β-OL(NCL-6-^{123}I)

I. KAMOI*, Y. OSHIUMI*, Y. TATENO**, F. SHISHIDO**, T. IDO**, K. SUZUKI**, T. IRIE**, K. FUKUSHI**, C. NAKAYAMA*, K. MATSUURA*, T. ITOH***, H. OGAWA***, M. MAEDA**** and M. KOJIMA****

Abstract NCL-6-^{123}I was used as an adrenal imaging agent for four patients, in each of whom the adrenal glands were clearly imaged. Scintigraphy was performed 48–72 hours after the intravenous injection of NCL-6-^{123}I. In this series, useful informations of adrenal glands were obtained in a short interval. The absorbed radiation dose using NCL-6-^{123}I is far less than that with NCL-6-^{131}I. NCL-6-^{123}I is therefore considered a potential adrenal scanning agent for a future clinical use.

I. Introduction

^{131}I-6β-Iodomethyl-19-norcholest-5 (10)-en - 3β-ol (NCL-6-^{131}I), first synthesized by Kojimaet al,[1,2] has been widely used clinically as an adrenal scanning agent because of its chemical stability and dense accumulation in the adrenal glands[3,4,5,6]. However any such ^{131}I-labeled adrenal ascanning agent incurs considerable patient radiation exposure[7,8,9]. ^{123}I, a gamma emitter with a shorter half life (13.3 hrs), is considered more suitable. Von Schuching et al.[10] experimentally evaluated the applicability of ^{123}I to adrenal scanning, but its clinical use has not yet been reported.

Using ^{123}I†, we composed NCL-6-^{123}I using the method of Kojima et al.[1,2]. This labeling method is superior to the method of Sarkar et al.[4], not only as to chemical purity and stability of the product, but also in simplicity of technique.

This is a report of our clinical experience with for patients for whom we performed NCL-6--^{123}I adrenal scanning.

II. Materials and Methods

^{123}I was obtained by the ^{127}I (p,5n) ^{123}Xe→^{123}I reaction[11,12] for which protons were accelerated to 50–60 MeV. NCL-6-^{123}I (2.8 mCi/m*l*) thus resulted from the isotopic iodide exchange reaction of NCL-6-^{123}I in an aceton-acetonitril solution.

Adrenal scintigraphy was performed in 4 cases consisting of 2 cases with primary aldosteronism, one of hypertension, and a case with renal mass, with the patient prone, obtaining posterior views at 24, 48, and 72 hrs after the intravenous injection of 6–7 mCi NCL-6-^{123}I (120μCi/Kg) (Table 1). To promote excretion of the scanning agent from the digestive and biliary tracts, the patient ingested a laxative (Magcorol 200 m*l*) and two egg yolks the night of the injection and 24 hrs thereafter.

To suppress thyroid uptake of the radionuclide, Lugol's solution was administered on each of the 3 days prior to examination. Images were obtained using a gamma camera with a parallel hole collimator for medium energy*. Counting ratios of the adrenals and the lumbar spine, excluding background, were measured by a medical mini-

* Faculty of Medicine, Kyushu University, Fukuoka
** Clinical Division, National Institute of Radiological Science, Chiba
*** Daiichi Radioisotopes Laboratories Ltd., Tokyo
**** Faculty of Pharmaceutical Sciences, Kyushu University, Fukuoka

受付: 54年10月 1 日
最終稿受付: 54年12月17日

Reprint address: I. KAMOI, Department of Radiology, Faculty of Medicine, Kyushu University, Maidashi 3-1-1, Higashi-ku, Fukuoka 812, Japan

This study was funded by Japanese Ministry of Education

† Produced in the National Institute of Radiological Science (Chiba, JAPAN) (11, 12)

* GCA-102: Thoshiba

Presented by Medical*Online

Table 1 Results of Data Analysis in Four Patients Using NCL-6-^{123}I

Case	Diagnosis	Counting Ratios*					
		24 hrs.		48 hrs.		72 hrs.	
		R.	L.	R.	L.	R.	L.
I	Primary Aldosteronism Postoperative state of Lt adenectomy due to adenoma	2.7	—	3.0	—	3.2	—
II	Hypertension, Essential	1.3	1.4	1.4	1.4	—	—
III	Lt. Renal Cyst	2.5	0.9	4.4	1.7	3.8	1.3
IV	Primary Aldosteronism Rt. Adrenal Adenoma Surgically proven	2.4	0.8	—	—	4.5	1.7

$$* \quad \frac{\text{Net Count of Adrenal}}{\text{Net Count of Lumbar Spine}} = \text{Counting Ratio}$$

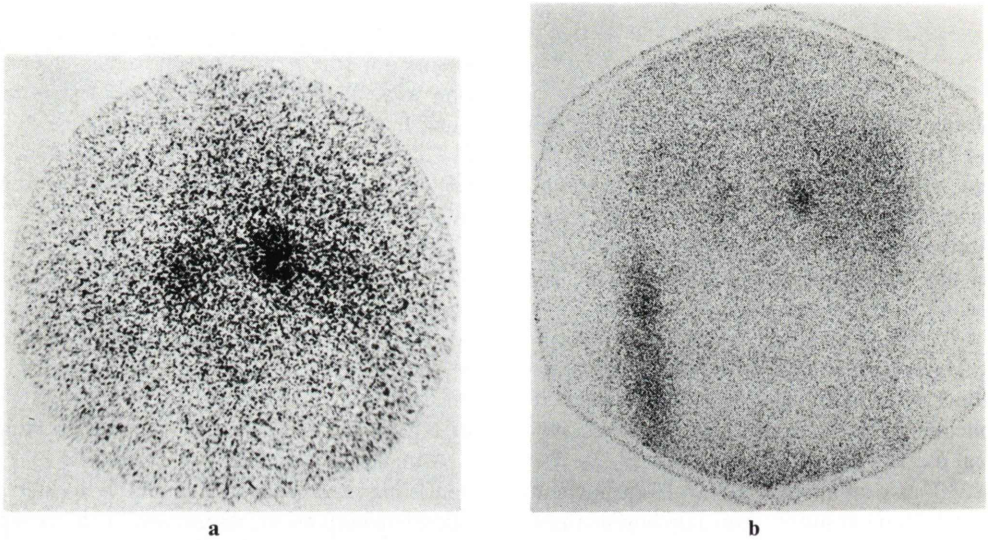

a b

Fig. 1 Case IV, Posterior view
(a): The adrenal images by gamma camera of Toshiba-102 using NCL-6-^{131}I 7 days after injection demonstrated a higher concentration in the right adrenal than that in the contralateral.
(b): The adrenal images by gamma camera of Searle-LFOV using NCL-6-^{123}I 72 hrs after injection.
The Right adrenal adenoma is well visualized using both techniques. At operation, the adenoma was about 1 cmϕ in size.

computer**.

III. Results

The adrenal images using NCL-6-^{123}I compared favorably with those obtained using ^{131}I (Fig. 1).

** TOSBAC 40: Toshiba

The right adrenal uptake of case IV using NCL-6-^{123}I was higher than the left, the right adrenal gland could be diagnosed abnormally high. Surgically adrenocortical adenoma with 1 cm in size was proved in the right adrenal gland. In spite of the short half-life of ^{123}I, clear adrenal images

Presented by Medical*Online

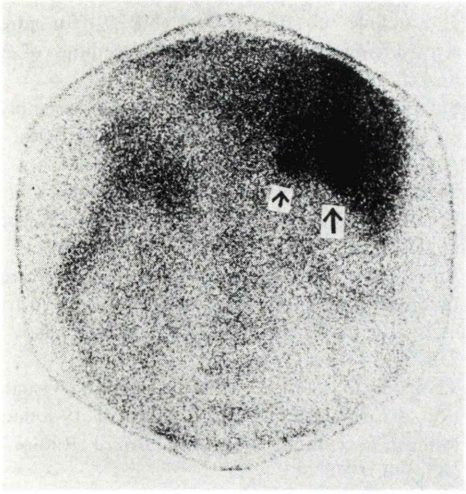

Fig. 2 Case I: Postoperative left adrenal adenoma, the right adrenal and gall bladder are visualized in the posterior view 24 hrs after injection.
Arrow head: Right adrenal
Arrow: Gallder bladder

were obtained, even 72 hrs post-injection. However it is very difficult to visualize the adrenals well when the background level is high. As shown is Table 1, the counting ratio of the adrenals to the lumbar spine varies with time lapse post-injection. The ratios at 48 and 72 hrs were higher than those at 24 hrs. The scintigraphy should therefore be performed more than 24 hrs after injection.

The uptake was relatively low in normal adrenals of case II & III, but higher in cases with primary aldosteronism (Case I & IV). In case I, residual gland of the right was diagnosed as a slightly higher uptake than that of normal subjects scintigraphically. However a final evaluation of the residual right adrenal gland due to adenoma or post surgical hyperfunctioning state has not been fully studied. The image of the gall bladder is superimposed on that of the liver, but the activity in the gall bladder decreases each day. Bearing this in mind, the right adrenal image will not be mistaken for that of the gall bladder (Fig. 2).

IV. Discussion

Because of its dense accumulation in the adrenal glands[1,3,4] NCL-6-^{131}I has been regarded as a good adrenal scanning agent. However, the resulting absorbed radiation dose to the adrenals is estimated to be 25–57 rad/mCi[9]. The estimated dose from NCL-6-^{123}I is 1.3 rad/mCi[13]. It is obvious that NCL-6-^{123}I is definitely advantageous in reducing the absorbed dose, as well as in capable of obtaining clinically useful adrenal images within 72 hrs. On the contrary, the short physical half-life of ^{123}I results in the disadvantage of loss of considerable radioactivity during the labeling process.

We succeeded in preparing NCL-6-^{123}I of high radiochemical purity (2.8 mCi/m*l*) quickly enough for our purposes. The NCL-6-^{123}I thus obtained had a purity of 99.9%[11,12], and its radioactive impurity (other than ^{125}-I)was considered extremely low[12,15,16]. The contamination by iodine radioisotopes of longer half-lives pointed out by some investigators[17,18] was thought to be neglihible as to absorbed radiation dose in our cases.

The metabolism of NCL-6-^{123}I being the same as that of NCL-6-^{131}I, distinct adrenal images were obtained. The scanning time was 48–72 hrs post injection as opposed to 6–8 days with the conventional methods using NCL-6-^{131}I or ^{131}I-19-Iodocholesterol. In this investigation, we used 200 m*l* Magcorol as a laxative and egg yolks for rapid excretion from the digestive and biliary tracts. However, based on the images we obtained, we agree with Thompson et al.[14] that some a more laxative is necessary for effective removal of the radionuclide.

From evaluating scintigraphic findings in the present cases, a correct diagnosis was obtained in case IV surgically, and also case II and III were diagnosed as unremarkable for adrenal glands. These 2 cases were considered as no adrenacortical disorders in final clinical diagnosis.

Judging from findings in these cases, NCL-6-^{123}I can be considered to have a potential usefullness as a radiopharmaceutical for adrenal scintigraphy for a future clinical use.

The authors are grateful to Dr. Walter J. Russell of the Radiation Effects Research Foundation, Hiroshima for his advice and for editing this manuscript.

References

1) Kojima M, Maeda M, Ogawa H, et al: New Adrenal-Scanning Agent. J Nucl Med **16**: 666–668, 1975
2) Maeda M, Kojima M, Ogawa H, et al: Homoal-

Presented by Medical*Online

lylic Rearrangement of 19-Iodocholest-5-en-3β-ol. New Adrenal Scanning Agents. Steroids **26**: 241–250, 1975

3) Couch MW and Williams CW: Comparison of 19-Iodocholesterol and 6-Iodomethyl-norcholesterol as Adrenal Scanning Agents. J Nucl Med **18**: 724–727, 1977
4) Sarker SF, Beierwaltes WH, Ice RD, et al: A new and superior adrenal scanning agent, NP-59. J Nucl Med **16**: 1038–1042, 1975
5) Kamoi I, Watanabe K, Nakayama C, et al: Clinical studies on adrenal scintigraphy. Nippon Acta Radiol **36**: 933–1005, 1976
6) Matsuura K, Kamoi I, Watanabe K, et al.: Adrenal Scintigraphy Using ^{131}I-Adosterol. Radioisotopes **24**: 780–785, 1975
7) Kirschner AS, Ice RD, and Beierwaltes WH: Radiation dosimetry of ^{131}I-19-iodocholesterol. Steroids **16**: 317–328, 1970
8) Ice RD, Kircos LT, Coffey JL, et al: Radiation dosimetry of ^{131}I-6-Iodomethyl-norcholesterol. J Nucl Med, Proceedings of 23rd annual meeting 540, 1976
9) Carey JE, Thrall JH and Freitas JE, et al: Absorbed dose to the human adrenals from iodomethylnorcholesterol (I-131) NP-59: Concise communication. J Nucl Med **20**: 60–62, 1979
10) von Schuching S and Wellman HW: Development and initial evaluation of ^{123}I labeled 6β-Iodomethyl-19-norcholest-5 (10)-en-3β-ol (NP 59) for adrenal scinti-imaging. J Nucl Med, Proceedings of 24th annual meeting **18**: 600, 1977
11) Suzuki K, Iwata R: A Multi-Target Assembly in an Irradiation with High Energy Particles. Int Appl Radiat Isot **28**: 663–665, 1977
12) Saegusa K, Arimizu N, Uchiyama G, et al: Clinical Uses of I-123 Produced by ^{127}I (p, 5n) ^{123}I Reaction in JIRS. Jap J Nucl Med **15**: 751–754, 1978
13) Brookeman VA: Radiation Dosimetry of Adrenal Imaging Agents 19-Iodocholesterol and 6-Iodomethylnorcholesterol. Int Appl Radiat, Isot **29**: 277–279, 1978
14) Thomson DM, Dovey P and Davis JB: Visualization of abnormal adrenal uptake of 19-iodocholesterol in Conn's syndrome. Brit J Radiol **51**: 545–546, 1978
15) Fusco MA, Peek NF, Jungerman JA, et al: Production of carrier-free ^{123}I-using the ^{127}I (p, 5n) ^{123}Xe reaction. J Nucl Med **13**: 729–732, 1972
16) Guillaume M, Lambrecht RM and Wolf AP: Cyclotron Production of ^{123}Xe and High Purity ^{123}I: A comparison of Tellurim Targets: Int J Appl Radiat Isot **26**: 703–707, 1975
17) James AE, Wagner HN, Cooke RE, ed.: Pediatric Nuclear Medicine Chap. **10**: 399–409, 1974
18) MIRD, Dose Estimate Report, No. 7: J Nucl Med **16**: 1214–1217, 1975

Presented by Medical*Online

要　旨

^{123}I 標識 6β-Iodomethyl-19-Norcholest-5(10)-EN-3β-OL(NCL-6-^{123}I) による副腎シンチグラフィの臨床評価

鴨井　逸馬*　鴛海　良彦*　舘野　之男*　宍戸　文男**
井戸　達雄**　鈴木　和年**　入江　俊章**　福士　清**
仲山　親*　松浦　啓一*　伊藤　隆之***　小川　弘***
前田　稔****　小島　正治****

*九州大学医学部放射線科学教室　**放射線医学総合研究所
***第一ラジオアイソトープ研究所　****九州大学薬学部放射性薬品学教室

6β-Iodomethyl-19-Norcholest-5(10)-EN-3β-OL (NCL-6)に小島[1)2)]らの方法を用い，放医研製[11)12)] ^{123}I による標識を行った NCL-6-^{123}I を得た．

NCL-6-^{123}I を用い臨床例4例に副腎シンチグラフィを行い，静脈注射より48時間より72時間後に良好な副腎シンチグラムが得られた．

シンチ所見を臨床的最終診断と比較することにより分析を行ない，臨床的有用な情報を得た．従来用いられている ^{131}I 標識-NCL に比し被曝線量も軽減出来，今後用いられるべき副腎シンチグラフィ用放射性医薬品であると考える．

Key words: Adrenal Scintigraphy, Iodine 123, NCL-6-^{123}I

Presented by Medical*Online