Annals of Nuclear Medicine Vol. 7, No. 4, 269–272, 1993

Demonstration of primary tracheobronchial amyloidosis by ^{99m}Tc-HMDP bone SPECT

Shoji YOSHIDA,* Toru SUEMATSU,* Tadashi KOIZUMI,*
Tomofumi MOTOHARA,* Kayoko OOBAYASHI,* Yoshiki TAKADA,*
Hiroyuki YAMAMOTO** and Terumasa SASHIKATA***

*Department of Radiology, **Department of Pulmonary Medicine and
***Department of Pathology, Hyogo Medical Center for Adults, Hyogo, Japan

A case of primary tracheobronchial amyloidosis is reported. A 61-year-old man presented with a 2-year history of intermittent hemoptysis. Chest X-ray and CT scanning showed tracheobronchial thickening. Bronchoscopic examination revealed diffuse tracheobronchial narrowing, and tracheobronchial biopsy detected amyloid deposits. Both ^{99m}Tc-HMDP planar and SPECT images were obtained in this patient. Coronal SPECT images revealed more precisely that the activity was not in the thoracic cage but in the bilateral hilar region. Localization of the amyloid deposits could be better determined on SPECT images than on planar images.

Key words: primary tracheobronchial amyloidosis, bone scan, SPECT, ^{99m}Tc-HMDP

INTRODUCTION

SINCE VAN ANTWERP et al.[1] described a case of ^{99m}Tc-diphosphonate uptake in biopsy-proven amyloid deposits in the hip and shoulder joints in a patient with multiple myeloma, bone seeking radiopharmaceuticals have been known to localize in amyloid deposits of various organs.[2–5]

Pulmonary amyloidosis is classified into tracheobronchial and parenchymal types according to the site of the amyloid deposition.[6] We describe a patient with tracheobronchial amyloidosis, in whom SPECT demonstrated localized ^{99m}Tc-HMDP deposition. To our knowledge, this is the first reported case of SPECT demonstration of pulmonary amyloidosis.

CASE REPORT

The patient was a 61-year-old man with a 2-year history of intermittent hemoptysis. Physical examination revealed only slight rales in both lung fields. Biochemical tests were unremarkable and Bence-Jones proteinuria was not detected. There were no amyloid deposits in the gastrointestinal tract, and no malignancy was detected. Lung function tests revealed slight obstructive disturbance (VC, 3,130 m*l*; $FEV_{1.0\%}$, 64%; and DLco, 22.76 m*l*/min/Hg).

Chest tomograms and CT scans (Figs. 1, 2a and 2b) revealed irregular thickening of the walls of the trachea and main bronchi, with narrowing of the trachea and right main bronchus, calcified bronchial walls were observed in both the hilar lobar and segmental bronchi. There were no significant changes in the lung fields.

Bronchoscopy revealed diffuse narrowing, irregular wall thickening, and mucosal redness of the trachea, main bronchi, and bilateral lobar bronchi (Fig. 3a).

Bronchial biopsy was performed at the bifurcation of the trachea. Microscopy with Diron staining showed marked submucosal amyloid depostion (Fig. 3b).

Bone scintigraphy was performed 3 hours after intravenous injection of 740 MBq of ^{99m}Tc-HMDP. Both whole body scanning and SPECT were performed. Anterior and posterior whole body scans revealed unusual activity in the thorax, but it was

Received November 25, 1992, revision accepted April 19, 1993.

For reprints contact: Shoji Yoshida, M.D., Department of Pathology, Hyogo Medical Center for Adults, 13–70 Kitaooji-cho, Akashi-shi, Hyogo 673, JAPAN.

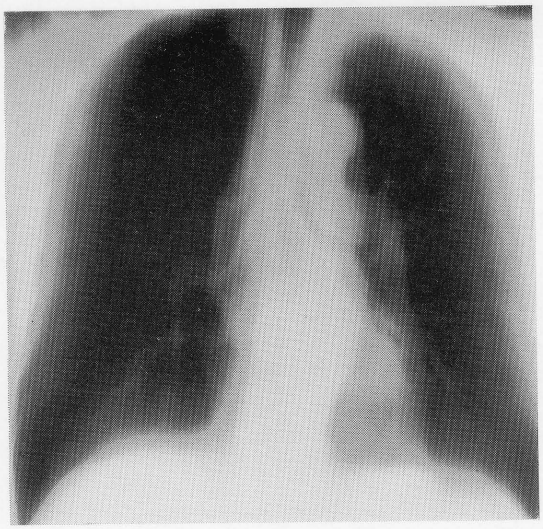

Fig. 1 X-ray tomogram (10 cm) shows irregular wall of the trachea, main bronchi and lobar bronchi with narrowing.

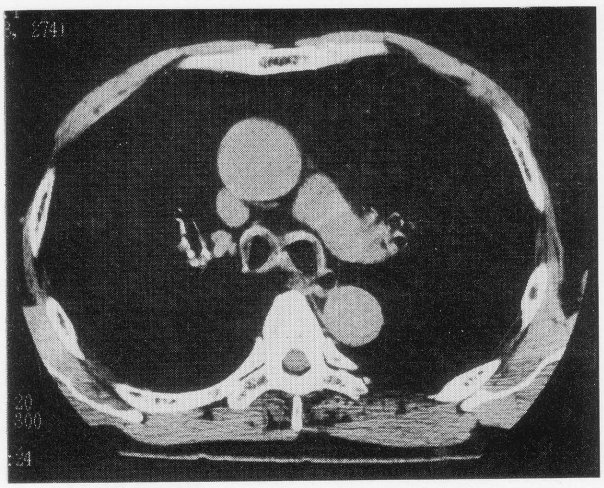

Fig. 2a CT image at the carina level shows wall thinkening of both main bronchi and calcified wall of right hilar lobar bronchus.

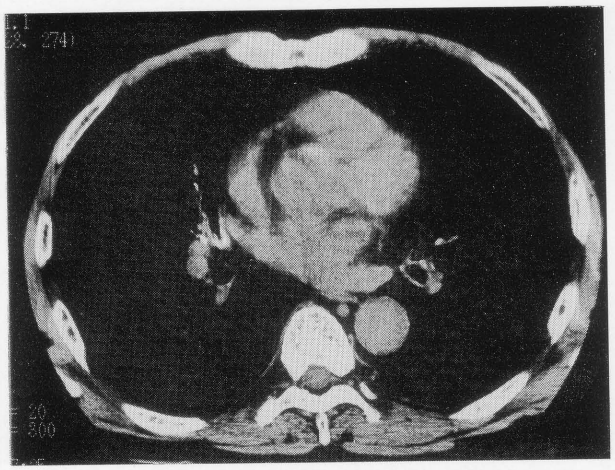

2b CT image at the hilar lobar bronchus level reveals calcified wall of both hilar lobar or segmental bronchi.

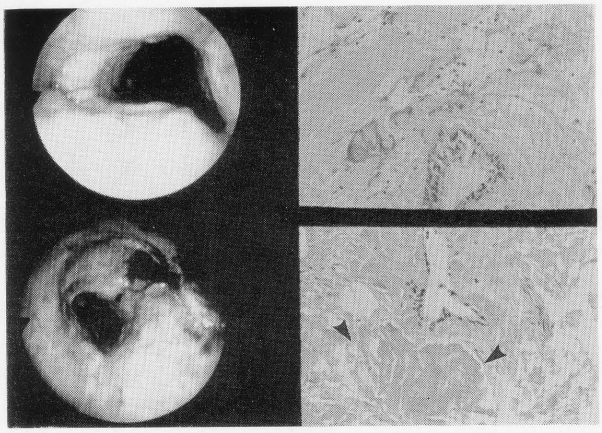

Fig. 3 **a** left side **b** right side
a Bronchoscopy reveals diffuse narrowing, irregular wall thickening, and mucosal redness of the trachea and main bronchi.
b Microscopy with Diron staining shows marked submucosal amyloid deposition (arrowheads).

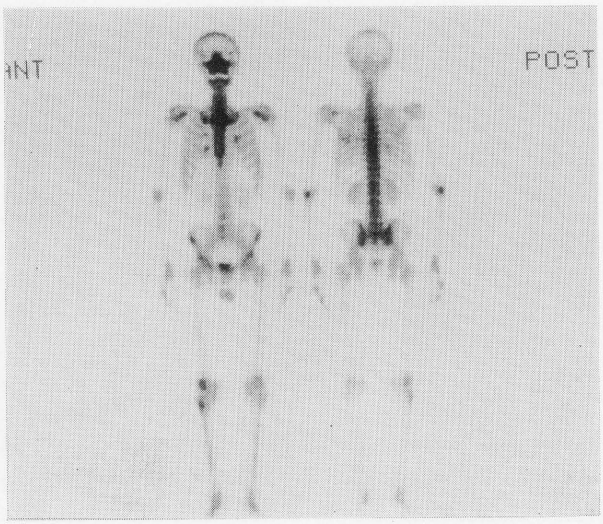

Fig. 4 Anterior and posterior whole body scans reveal unusual activity in the thorax, but it is difficult to determine whether the activity is in the lung or the costal cartilages.

difficult to determine whether the activity was in the lung or the costal cartilages (Fig. 4). No other abnormal uptake was demonstrated.

Transaxial SPECT images verified that the abnormal ^{99m}Tc-HMDP uptake in the thorax was in the bilateral hilar regions (Fig. 5). Coronal SPECT images revealed more precisely that the activity was in the bilateral hilar lobar bronchi. The activity in the trachea and bilateral main bronchi was not well delineated (Fig. 6). No other abnormal intrapulmonary activity was seen in the SPECT studies. The abnormal ^{99m}Tc-HMDP uptake was compatible with the sites of calcified wall of the hilar lobar bronchi on CT images.

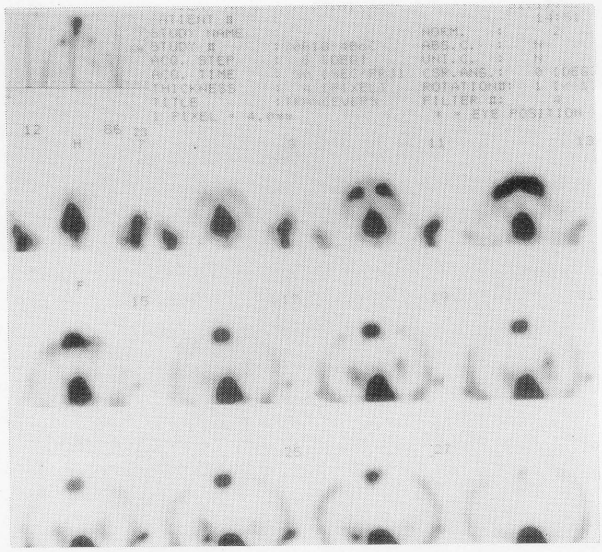

Fig. 5 Transaxial SPECT images verify that the abnormal ^{99m}Tc-HMDP uptake in the thorax is in the bilateral hilar regions.

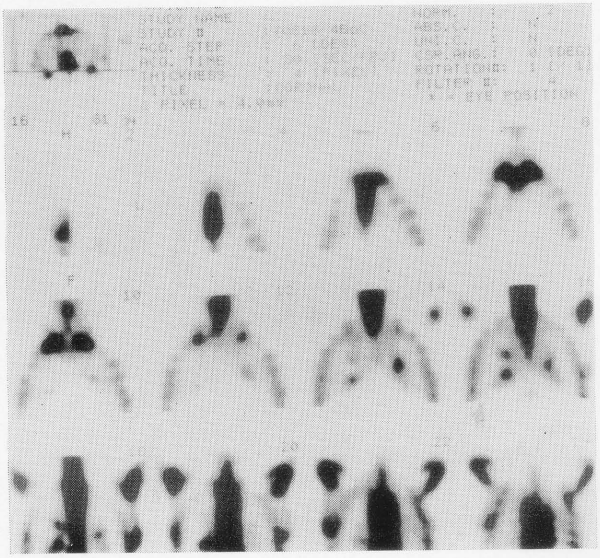

Fig. 6 Coronal SPECT images reveal more precisely that the activity is in the bilateral hilar lobar bronchi. The activity in the trachea and main bronchi are not prominent.

DISCUSSION

In this patient, tracheobronchial biopsy revealed amyloid deposition in the submucosal tissue. Amyloidosis is generally diagnosed by the detection of typical amorphous eosinophillic extracellular material with green birefrigence under a polarizing microscope after Congo red staining. The Diron staining method used in this case was a histochemical stain. Other examinations, including endoscopy, abdominal CT, and rectal biopsy, ruled out multiple myeloma, rheumatoid arthritis, and malignancy as causes of the amyloid deposition. This patient was thus classified as having primary amyloidosis. Primary amyloidosis of the lung was classified by Spencer[8,7] as follows: 1) localized deposits in the bronchi, 2) multiple or diffuse bronchial deposits, 3) localized or multiple parenchymal deposits, and 4) diffuse parenchymal amyloid infiltration of the alveolar walls and pulmonary blood vessels. In this case, there were no abnormalities in either lung field, so type 2 with multiple or diffuse bronchial deposits could be considered as the diagnostic bone scintigraphy showed unusual accumulation of the bone scanning tracer in the bronchial amyloid deposits.

In 1975, Van Antwerp et al.[5] described a multiple myeloma patient with ^{99m}Tc-diphosphonate uptake in biopsy-proven amyloid deposits of the hip and shoulder joints. The mechanism of bone tracer uptake in amyloid deposits is not clear, but it seems to be calcium-dependent and attributable to high calcium content of amyloid-infiltrated tissues. This hypothesis is supported by the experimental work of Silverstein et al.[9] in which increasing tissue retention of ^{99m}Tc Sn diphosphonate correlated with the calcium content of the tissue analyzed. In addition, Yood et al.[10] demonstrated an average calcium content 37 times greater in amyloid-infiltrated livers than in normal ones. Another proposed mechanism[11] attributes the high uptake of technetium pyrophosphate in amyloid deposits to transchelation of ^{99m}Tc atoms from ^{99m}Tc-PYP to the abnormal amyloid protein. There have been some previous reports[12] about the deposition of bone scan tracers in the lungs with planar image data being demonstrated. However, no SPECT study of primary tracheobronchial amyloid deposition had been performed previously. Compared to the planar images, transaxial or coronal SPECT images could more precisely identify the position of the amyloid depositions in the bilateral hilar regions.

On CT images, neither bilateral hilar lymphadenopathy nor calcified lymphnodes were observed. The ^{99m}Tc-HMDP uptake in the hilar region is supposed to be the calcified hilar bronchial wall, which was verified on CT images. The uptake of ^{99m}Tc-HMDP in the trachea and main bronchus are not so marked as the activity in the hilar lobar bronchi.

REFERENCES

1. Van Antwerp JD, Mara REO, Pitt MJ, et al: Technetium-99m-diphosphonate accumulation in amyloid. *J Nucl Med* 16: 238–240, 1975
2. Vanek JA, Cook SA, Bukowski RM: Hepatic uptake of ^{99m}Tc-labelled diphosphonate in amyloidosis, case report. *J Nucl Med* 18: 1086–1088, 1977
3. Mallellan GL, Stewart JH, Balachandran S: Localiza-

tion of Tc-99m-MDP in amyloidosis of the breast. *Clin Nucl Med* 6: 579–580, 1981
4. Falk RH, Lee VW, Rubenew A, et al: Sensitivity of technetium 99m-pyrophosphate scintigraphy in diagnosing cardiac amyloidosis. *Am J Cardiol* 51: 826–830, 1983
5. Lee VW, Caldenone AG, Falk RH: Amyloidosis of heart and liver: comparison of Tc-99m-Pyrophosphate and Tc-99m-Methylene Diphosphonate for detection. *Radiology* 148: 239–242, 1983
6. Cordier JF, Lorie R, Brune J: Amyloidosis of the lower respiratory tract. *Chest* 90: 827–831, 1986
7. Wakasa K, Sakurai M, Koezuka I, et al: Primary traceobronchial amyloidosis. A case report and review of reported cases. *Acta Pathol Jpn* 34: 145–152, 1984
8. Spencer H: *Pathology of the lung*, 3rd ed. Pergamon Press, pp. 675–680 1977
9. Silverstein EF, Tofe AJ, et al: Distribution of Tc-99m-diphosphonate and free Tc-99m-Pertechnetate in selected soft and hard tissues. *J Nucl Med* 16: 58–61, 1975
10. Yood R, Skinner A, Cohen AS, et al: Soft tissue uptake of bone seeking radionuclide in amyloidosis. *J Rheumatol* 8: 760–766, 1981
11. Buja LM, Tofe AJ, Kulkarni PV, et al: Sites and mechanism of localization of Tc-99m-phosphorous radiopharmaceuticals in acute myocardial infarcts and other tissue. *J Clin Invest* 60: 724–740, 1977
12. Zwas ST, Shipilberg O, Huszar M, et al: Isolated ectopic lung uptake of technetium 99m methylene diphosphonate on bone scintigraphy in primary amyloidosis. *Eur J Nucl Med* 17: 282–285, 1990