Annals of Nuclear Medicine Vol. 6, No. 3, 203–206, 1992

Demonstration of inguinal hernia by means of peritoneal ^{99m}Tc-MAA scintigraphy with a load produced by standing in a patient treated by continuous ambulatory peritoneal dialysis

Kazuyoshi SUGA,* Takafumi KANEKO,* Kazuya NISHIGAUCHI,* Kyoko SOEJIMA,* Hiromoto UTSUMI** and Norimasa YAMADA**

*Department of Radiology, Yamaguchi University School of Medicine
**Department of Radiology, Yamaguchi University Hospital

A 45-year-old man receiving continuous ambulatory peritoneal dialysis developed scrotal swelling and edema which was aggravated in the standing position. Physical examination failed to find inguinal hernia and although ultrasonography revealed the patent had processus vaginalias, it failed to prove its continuity to the peritesticular space of the tunica vaginalis. Peritoneal scintigraphy with intraperitoneal instillation of ^{99m}Tc-Macroaggregated albumin followed by standing clearly demonstrated the connection. The use of the standing load makes possible faster visualization of a positive finding and more accurate diagnosis than examination in the supine position.

Key words: continuous ambulatory peritoneal dialysis, ^{99m}Tc-MAA, peritoneal scintigraphy, inguinal hernia

INTRODUCTION

CONTINUOUS AMBULATORY PERITONEAL DIALYSIS (CAPD) offers several advantages over hemodialysis for patients with end-stage renal disease.[1] However, several complications have been observed, including pericatheter leaks of dialysate, and abdominal wall and diaphragmatic leaks.[2–5] As a relatively infrequent complication, inguinal hernias are also associated with CAPD.[4–6] We detected leakage of dialysate fluid into an inguinal hernia by peritoneal scintigraphy with ^{99m}Tc-Macroaggregated albumin (^{99m}Tc-MAA) with a load produced by standing. This paper describes the superiority of this procedure for demonstrating the connection between the peritoneal cavity and the peritesticular space of the tunica vaginalis.

Received March 4, 1992, revision accepted April 8, 1992.

For reprints contact: Kazuyoshi Suga, M.D., Department of Radiology, Yamaguchi University School of Medicine 1144 Kogushi, Ube 755, Japan.

CASE REPORT

The patient was a 45-yr-old male with end stage renal disease of unknown etiology. He had started hemodialysis 19 years previously, at the age of 27. Following renal transplantation 17 years ago, he did not receive hemodialysis for 8 years thereafter. However, 6 years ago he restarted hemodialysis, with intermittent CAPD, for chronic renal rejection. He has received only CAPD for the last 3 years. On 7 August, 1990 he was admitted for uremic lung with bronchopneumonia and treated with CAPD and antibiotics. From the second day of CAPD, a chest radiogram showed the uremic lung to be improved. However, he noted right hemilateral scrotal swelling, which was increased in the standing position. Physical examinstion revealed right scrotal hydrocele, but indirect inguinal hernia could not be palpated. There was neither external catheter leakage, nor edema of the abdominal wall. Although an ultrasonogram of the scrotal area could visualize the patent processus vaginalis containing pooling fluid and the dilated peritesticular space of the tunica vaginalis, no evidence of continuity between them was found (Fig. 1).

Peritoneal scintigraphy with ^{99m}Tc-MAA was performed on a large field-of-view scintillation camera (Toshiba 901-A) set at the 140-keV photopeak and 20% window, utilizing a low-energy, all purpose collimator. A 111 MBq (3 mCi) dose of ^{99m}Tc-MAA was instilled intraperitoneally via the dialysis catheter (Tenckhoff catheter). Anterior views in the supine position were obtained over the abdomen and pelvis, including the genital area, at 10 and 20 minutes. A protrusion indicating intraperitoneal ^{99m}Tc-MAA activity was observed in the right lower abdomen. However, no tracer activity in the inguinal and scrotal regions was found (Fig. 2). Subsequently, an anterior view in the standing position was obtained. Immediately after standing, the tracer movement in the right lateral inguinal region extending in a tract like fashion was observed (Fig. 3-A). Furthermore, 15 minutes after standing, a ring-like distribution of tracer activity was found in the ipsilateral scrotum with a central defect clearly visible (Fig. 3-B). These findings were considered to reveal tracer transferability from the patent processus to the peritesticular space of the tunica vaginalis and the connection between them.

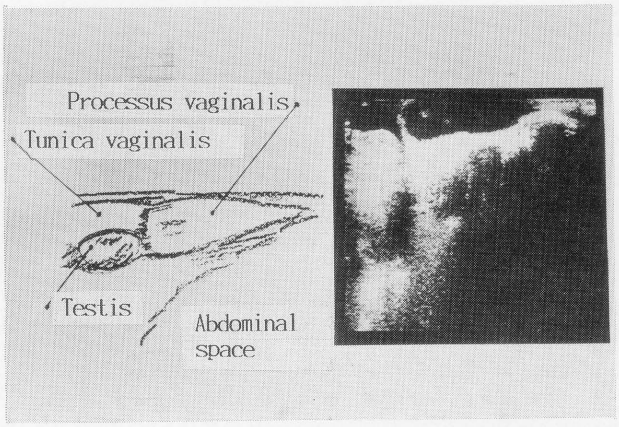

Fig. 1 Schematic presentation of ultrasonographic finding of scrotal region. Ultrasonography of the scrotal area demonstrated the patent processus vaginalis containing pooling-fluid and the peritesticular space of the tunica vaginalis and a septal structure between them. However, no evidence of continuity between them was found.

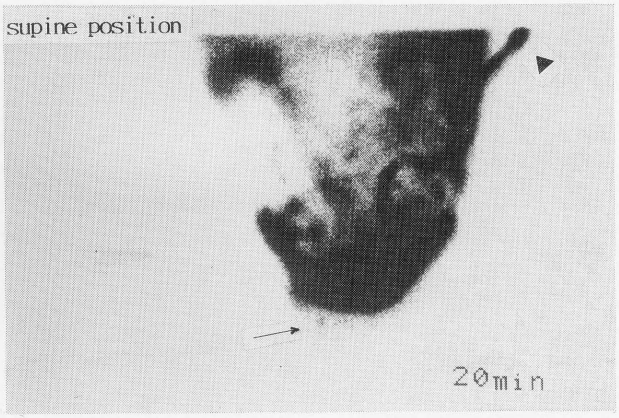

Fig. 2 Peritoneal scintigraphy 20 minutes after the instilling of ^{99m}Tc-MAA intraperitoneally via the dialysis catheter (Tenckhoff catheter, ▲) in the supine position. A protruded portion of intraperitoneal activity was observed in the right lower abdomen (→). However, no tracer activity was found in the inguinal and scrotum region.

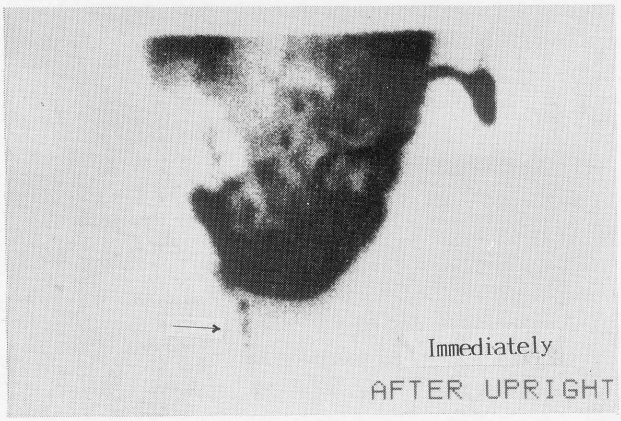

A

B

Fig. 3 Anterior view in the standing position obtained subsequently. Immediately after standing (Fig. 3-A), the movement of tracer activity in the right lateral inguinal region extending in a tract like fashion was observed (→). Furthermore at 15 minutes after standing (Fig. 3-B), ring-like tracer activity distribution was found in the ipsilateral scrotum with the central defect clearly visible (→). These findings indicated tracer transferability from the patent processus vaginalis to the peritesticular space of the tunica vaginalis and the connection between them.

For the continuous swelling of the right scrotum, right inguinal herniorrhaphy was performed on 28, August. Continuity between the intraperitoneal space, the patent processus vaginalis and the peritesticular space of the tunica vaginalis was observed at surgery.

DISCUSSION

CAPD has been used as a safe and effective mode of treatment in the management of end-stage renal failure.[1] As complications, ventral and inguinal hernias are associated with CAPD, mainly because of the increased intraperitoneal pressure, and the incidence of both hernias ranges from 2.7–25% in patients receiving CAPD.[2–6] Scrotal edema (or swelling) or genital edema is a relatively infrequent complication of inguinal hernias in which fluid may accumulate in the cavity of tunica vaginalis by way of a patent processus vaginalis, as well as from extravasation (leakage) of dialysate beneath Scarpa's fascia in patients with umbilical or ventral hernia.[4] In the latter cases a small peritoneal rent is responsible for the extravasation of dialysate into the sacral tissue planes. We must distinguish these different mechanisms by which genital edema or swelling occurs. However, there are cases in which it is difficult to establish the cause of the edema by physical examination.[4,7]

A number of different diagnostic procedures have been employed to determine the exact causes, including intraperitoneal instillation of methylene blue dye, contrast catheterography, peritoneography and contrast enhanced CT.[4,7] However, abdominal pelvic scintigraphy after intraperitoneal instillation of ^{99m}Tc-labeled colloid has been found to be a very useful diagnostic procedure to distinguish inguinal hernia from other causes of scrotal swelling and it is accurate, readily available, easy to perform and dose not cause any discomfort or morbidity.[6–8] Furthermore, radionuclide studies can provide continuous monitoring until a positive finding is obtained.

While most of these studies have reported the use of ^{99m}Tc-labeled colloid,[6–8] Spadaro et al.[9] used ^{99m}Tc-MAA as in the present patient. ^{99m}Tc-MAA contains aggregated albumin in which the particles are 10–90 μm in size, with a distribution consisting of approximately 90% within the 10–60 μm range, therefore the use of ^{99m}Tc-MAA is suitable for demonstrating the communication between the cavities through pores larger than in size than this radiopharmaceutical. On the other hand, ^{99m}Tc-Sn-colloid (one of the ^{99m}Tc-labeled colloids) contains colloids of a size providing approximately 85% distribution within the 0.4–5 μm range. Consequently, when a transfer of ^{99m}Tc-Sn-coloid from the abdominal space to another cavity is observed, the possibility that the transfer is caused by the lymphatic uptake of this agent must be considered.[6,9] In addition, in our patient peritoneal scintigraphy was performed with a load produced by standing. A standing load provided a rapid movement into the peritesticular cavity of the tunica vaginalis by way of the patent processus vaginalis, and the connection between them was proved clearly at only 15 minutes after application of the load. Walker et al.[6] performed peritoneal scintigraphy with ^{99m}Tc-labeled albumin colloid in the supine position in two patients with an inguinal hernia and the tracer activity in the cavity of the tunica vaginalis was demonstrated as in our patient. However, it took 2 hours to demonstrate after the postintraperitoneal instillation of the tracer. Compared with the supine position, our procedure using a load afforded a short examination time for obtaining a positive result.

The dialysate induced a chronic increase in intra-abdominal pressure from 1 to 21 times as high as generally found in normal subjects.[4] Furthermore, Twardowski et al.[10] reported that the mean intra-abdominal pressure increased by 2.7 cm of water per liter of intraperitoneal volume in the upright position and intraabdominal pressure measured at the inguinal level was approximately 30 cm higher than at the xiphoid, resulting in 38 to 40 cm of water pressure at a 2 liter intraperitoneal volume. This high pressure would introduce rapid movement of the tracer into the peritesticular cavity of the tunica vaginalis. Valsalva's manuever will be useful for increasing the pressure in the patent processus vaginalis.[4] In the standing position, this procedure also can be easily introduced when positive findings cannot be obtained.

CONCLUSIONS

Peritoneal scintigraphy by means of ^{99m}Tc-MAA with a load produced by standing was performed in a patient with scrotal swelling, following CAPD, but without clinical findings of inguinal hernia. A patent processus vaginalis was demonstrated by a rapid and clear movement of tracer activity in the lateral inguinal region, extending in a tract like fashion into the ipsilateral scrotum. Moreover, the connection between the patent processus vaginalis and the peritesticular space of the tunica vaginalis was clearly visualized. Peritoneal scintigraphy with a load produced by standing has the advantage of demonstrating a positive finding within a short period.

REFERENCES

1. Popovich RP, Moncrief JW, Nolph KD, et al: Con-

tinuous ambulatory peritoneal dialysis. *Ann Intern Med* 88: 449–456, 1978
2. Brown MW, Hamilton DNH, Junor BJR: Surgical complications in patients on continuous ambulatory peritoneal dialysis. *J R Coll Surg Edinb* 28: 141–146, 1983
3. Chan MK, Baillod RA, Tanner A: Abdominal hernias in patients receiving continuous ambulatory peritoneal dialysis. *Br Med J* 283: 826, 1981
4. Wetherington GM, Leapman SB, Robison RJ, et al: Abdominal wall and inguinal hernia in continuous ambulatory peritoneal dialysis patients. *Am J Surg* 150: 357–360, 1985
5. Cooper JC, Nicholls AJ Simms JM, et al: Genital-oedema in patients treated by continuous ambulatory peritoneal dialysis: an unusual presentation of inguinal hernia. *British Med J* 286: 1923–1924, 1983
6. Walker JV, Fisf MB: Scintigraphic detection of abdominal wall and diaphragmatic peritoneal leaks in patients on continuous ambulatory peritoneal dialysis. *J Nucl Med* 29: 1596–1602, 1988
7. Kopecky RT, Frymoyer PA, Witanowski LS, et al: Complications of continuous ambulatory peritoneal dialysis; diagnostic value of peritoneal scintigraphy. *Am J Kidneys Diseases* 10: 123–132, 1987
8. Ducassou D, Vuillemin L, Wone C, et al: Intraperitoneal injection of technetium 99m sulfur colloid in visualization of a peritoneo-vaginalis connection. *J Nucl Med* 25: 68–69, 1984
9. Spadaro JJ, Thakur V, Nolph KD: Technetium-99m-labelled macroaggregated albumin in demonstration of trans-diaphragmatic leakage of dialysate in peritoneal dialysis. *Am J Nephrol* 2: 36–38, 1982
10. Twardowski ZJ, Prowant BJ, Nolph KD, et al: High volume, low frequency continuous ambulatory peritoneal dialysis. *Kidney Int* 23: 64–70, 1983