Annals of Nuclear Medicine Vol. 4, No. 2, 59–65, 1990

Evaluation of viral myocarditis in children by radionuclide method

Yasuaki KAWAMURA,* Takeshi MORISHITA,* Junichi YAMAZAKI,* Ichio OKUZUMI,*
Manabu WAKAKURA,* Toshinori MUTO,* Tsutomu SAJI,**
Hiroyuki MATSUURA**, Norio MATSUO** and Yoshimasa YABE***

*The First Department of Internal Medicine, Toho University School of Medicine
**The First Department of Pediatrics, Toho University School of Medicine
***Cardiovascular Diagnostic Center, Toho University School of Medicine

Evaluation of viral myocarditis is essential for the clinician to assess the prognosis. In this study, Tl-201 myocardial scintigraphy and Tc-99m gated cardiac blood pool scan were performed in 16 patients with myocarditis diagnosed by clinical symptoms and laboratory findings and these nuclear medicine techniques were followed up for 5 years.

Exercise Tl-201 scintigraphy using a bicycle ergometer was performed in 8 patients by SPECT imaging. There were mild to severe persistent defects found in all cases (100%), but pressure rate products showed normal response. The Tl-201 defect ratio improved gradually, but did not change significantly. In the resting Tl-201 image one of 16 patients showed severe multifocal defects.

LVEF increased significantly from 1 year to 5 years after onset, while RVEF measured by gated blood pool scans showed slight increases 3 years to 5 years after diagnosis. It was concluded that myocardial perfusion improved only incompletely. Cardiac function (LVEF and RVEF) improved gradually, and pressure rate products were normal. Myocarditis should therefore be followed up in order to assess the prognosis; moreover, the relationship of myocarditis to dilated cardiomyopathy needs to be further studied.

Key words: viral myocarditis, Tl-201 myocardial scintigraphy, Tc-99m gated blood pool scan

INTRODUCTION

A diagnosis of myocarditis based on the radionuclide technique is more difficult than that of ischemic heart disease because patterns of inflammatory cell infiltration, myocardial cells, interstitial edema and necrosis in the former are not as uniform as in the latter. The use of radiopharmaceuticals to detect myocarditis had been reported and includes Tl-201,[1–4] Tc-99m-PYP,[4–6] In-111-WBC,[7] and Ga-67-citrate.[8,9] While studying the various mechanisms involved in myocarditis, such as the mechanisms of myocardial blood flow, myocardial necrosis, the development of inflammation, and cell infiltration accompanying the inflammation, efforts are also being made to identify the severity of myocarditis and the affected area. Recently, an interesting report has been published on the application of In-111-Antimyosin to human myocarditis using monoclonal antibodies.[10]

However, it is still not easy to make an exact diagnosis of myocarditis, even employing immunobiochemical methods using virus antibody titer and pathological methods such as myocardial biopsy. It is also difficult to identify the clinical symptoms accompanying myocarditis, which range from cold-like symptoms to a serious, deadly form of arrhythmia. Moreover, consideration has recently been given to the relationship of dilated cardiomyopathy to myocarditis. In particular, there have appeared many reports on myocarditis developing in childhood, emphasizing the necessity of long-term follow-up in both the pediatric and internal medicine field.

Received November 30, 1988, revision accepted February 14, 1990.

For reprints contact: Yasuaki Kawamura, Otaku Omori-nishi 6–11–1, Tokyo 143, JAPAN.

We studied myocardial perfusion and cardiac function in children with myocarditis, for a relatively long period using thallium myocardial scintigrams and Tc-99m human serum albumin (HSA) blood pool scintigrams.

SUBJECTS AND METHODS

The subjects were 16 patients diagnosed as having myocarditis from the results of biochemical (increase in serum CPK and CRP), immunological (increase in viral titer) and coronary angiography (including cardiac muscle biopsy). Myocarditis developed at age 8.1±3.3 (mean±1 SD), and the male/female ratio was 8:8. These patients underwent hematological tests as well as cardiac catheterization and myocardial biopsies.

1) Tl-201 myocardial scintigraphy

a) Myocardial scintigraphy at rest

Tl-201, at a dose of 55.5–74 MBq (1.5–2 mCi), was administered to the patients intravenously. Ten minutes after intravenous injection, anterior (ANT), left anterior-oblique (LAO 45°), and left lateral (L-LAT) projections were scintiphotographed with a Searl's LFOV gamma camera, with a low-energy, high-resolution parallel hole collimator. The acquisition data were then analyzed with a Shimadzu Corporation Scintipac 1200 computer. Each projection was stored as a 64×64 matrix in a dedicated computer, in preset counts were taken (10 min), and data collected from the photos were recorded in the list mode.

Tl-201 defect score: In order to better study myocardial blood flow, we prepared a Tl defect scoring system, thereby allowing us to make semi-quantitative comparisons between a total of 6 segments, as shown in Fig. 1, namely, the anterolateral (AL) segment, photographed by ANT projection, the septal (SEP) and posterolateral (PL) segments photographed by LAO 45° projection, and the anterior (ANT), apical (Api) and posterior segments (POST) photographed by L-LAT projection. Tl uptake was divided into four grades: 0 (normal), +1 (mildly reduced), +2 (moderately reduced), and +3 (severely reduced), and the total number of points was regarded as the Tl defect score. Scintigrams were examined by three observers with more than five years' experience in cardiac nuclear medicine, and the mean of these three evaluations was used as the value for each segment.

b) Exercise Tl-201 myocardial scintigraphy

While observing the disease, exercise myocardial scintigraphy was conducted on 8 patients, with a bicycle ergometer. We continuously performed scintigraphy for 3 minutes, in increases of 25-watt work loads with an EDC bicycle ergometer, until the symptom limit was reached. Redistribution SPECT images were then photographed with a Siemens' ZLC 7500 γ-camera, immediately and 3 hours after injection, and the images were analyzed with a Shimadzu Scintipac 2400 computer.

2) Gated cardiac blood pool scintigraphy

Tc-99m-human serum albumin (HSA) 555–740 MBq (15–20 mCi), was injected into the right antecubital vein at an LAO 45° projection, and cardiac output (CO) at the time of the first pass, and left and right ventricular ejection fractions (LVEF, RVEF) at equilibrium, were analyzed by means of the above-mentioned computer system.

RESULTS

Cardiac catheterization was performed on 11 of 16 patients with myocarditis (69%), and it was possible to carry out biopsy in 10 of the 16 (63%). A significant increase in the virus antibody titer was observed in 9 of the 16 patients (56%), the most notable of the viruses being of the Coxsackie virus B group, influenza virus, rubella and rubeola. In 7 of the patients (44%), CPK values were observed to have increased more than 100 IU/m*l* (normal value: lower than 80 IU/m*l*) due to myocarditis, while in 6 (38%), CRP levels had increased to more than

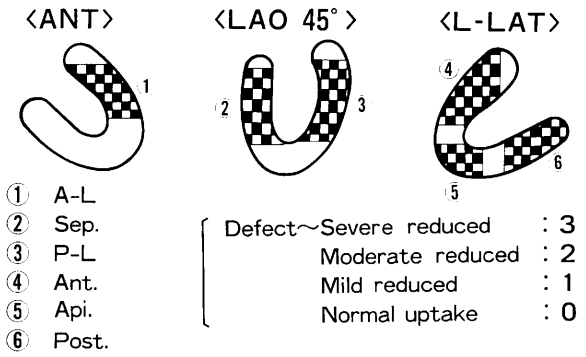

Fig. 1 ^{201}Tl defect score in three projections.

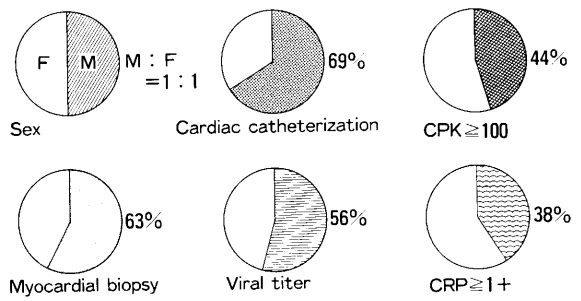

Fig. 2 Patients profile in 16 acute myocarditis (average onset age 8.1 year).

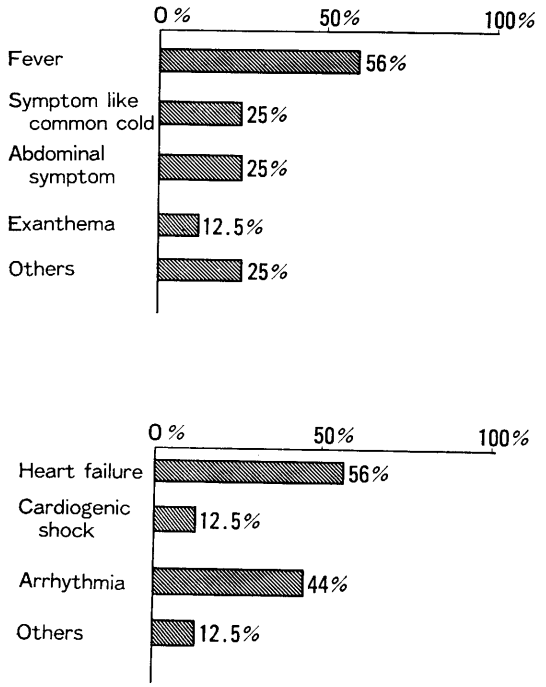

Fig. 3 General symptom (upper) and cardiac symptom (lower) associated with acute myocarditis.

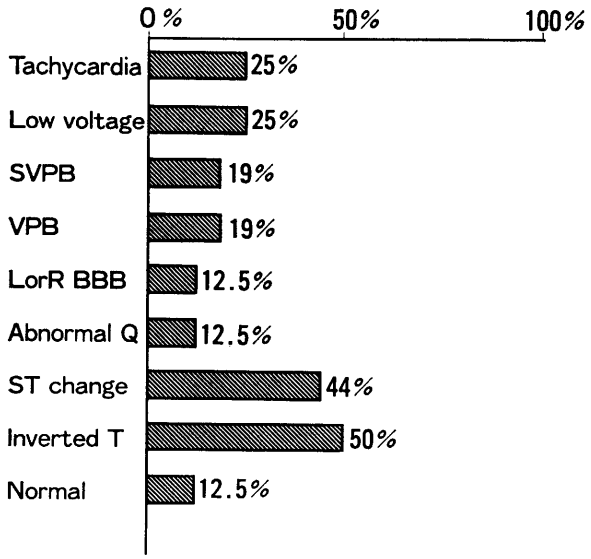

Fig. 4 EKG abnormalities associated with acute myocarditis.

1+due to inflammation (Fig. 2). As for initial symptoms, 9 of the 16 patients (56%) had a fever, 4 (25%) showed cold-like symptoms, 4 (25%) had abdominal symptoms, and 2 (12.5%) had eruptions. Cardiac symptoms also were noted: 9 (56%) showed heart failure, 7 (44%) arrhythmia, and 2 (12.5%) shock (Fig. 3). As for ECG changes during the acute stage, ST changes (both elevation and depression) were observed in 7 patients (44%), T-wave reversal was seen in 8 (50%), followed by tachycardia in 4 (25%), low electric potential in 4 (25%), supraventricular arrhythmia in 3 (19%), ventricular arrhythmia in 3 (19%), bundle branch block in 2 (12.5%), and abnormal Q-waves in 2 (12.5%) (Fig. 4).

1) Changes in cardiac function

Using Tc-99m-HSA, we observed LVEF (left ventricular ejection fractions) after the passage of 0, 3, 6, months, and 1, 2, 3, 4 and 5 years after diagnosis. The mean LVEF values were, 50.4±4.9%, 51.6±5.1%, 57.4±9.4%, 58.8±5.9%, 57.1±5.3%, 58.8±12.0%, 57.0±8.9% and 55.3±6.7%, respectively (n=16). As these figures show, more significant remissions occurred after 1 to 5 years than just after the onset of the disease ($p<0.05$). On the other hand, a significant increase ($p<0.05$) in RVEF (right ventricular ejection fraction) was noted to occur 3 years to 5 years after onset. The mean RVEF values after the passage of 0, 3, 6 months 1, 2, 3, 4 and 5 years were 37.1±10.9%, 32.7±11.4%, 34.7±5.1%, 33.2±3.7%, 33.2±3.7%, 33.6±8.0%, 43.2±14.1%, 35.1±3.3% and 44.0±12.9%, respectively (n=16) (Fig. 5).

2) Tl-201 defect score

We performed Tl-201 myocardial scintigraphy at the same time as cardiac function examination, and the Tl-201 defect score values obtained from planar images photographed in three projections after the passage of 0, 3, 6 months and 1, 2, 3, 4 and 5 years were 1.3±1.9, 1.2±1.1, 1.2±1.1, 1.0±0.9, 0.8±1.0, 1.2±0.3, 1.0±0.6 and 1.0±0.8, respectively. These values show no significant decrease during the passage of time from onset to 5 years later.

Case report

Figure 7a shows electrocardiograms of a female patient taken at 11 years, 10 months old, at the same time as Tl myocardial images were photographed just after the onset of the disease. Negative T-waves in the ECG V_{1-3} became normal immediately after the onset of the disease, and images (Fig. 7b) showing Tl defects (white arrows) in AL (ANT), PL (LAO 45°), and ANT (L-LAT) segments, were gradually improved.

3) *Exercise Tl-201 myocardial scintigram*

With a bicycle ergometer, exercise myocardial scintigraphy was performed on 8 patients and the change in the pressure rate products (PRP) was from 9,406.3±3,607.1 before exercise to 26,125.5±5,454.3 at maximal exercise ($p<0.001$). In all 8 patients, exercise was discontinued (end point: 10.4±0.6 min) because of leg fatigue, and a comparison of SPECT images revealed persistent defects in 8 out of 8 (100%). There was, however no redistributed image seen.

Figure 8 features an exercise myocardial scin-

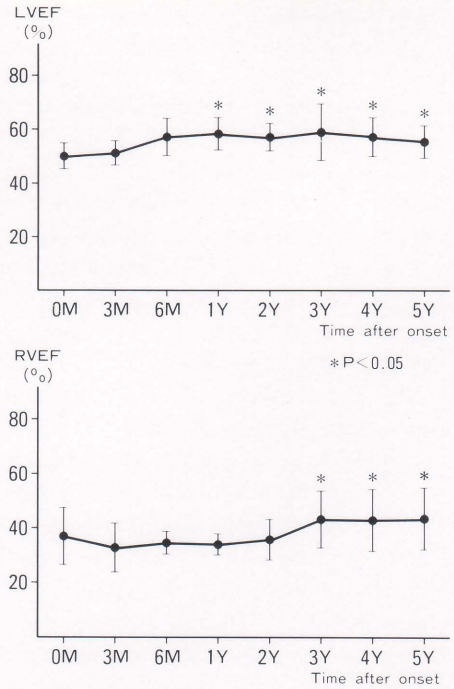

Fig. 5 Changes in LVEF (upper) and RVEF (lower) in patients with acute myocarditis.

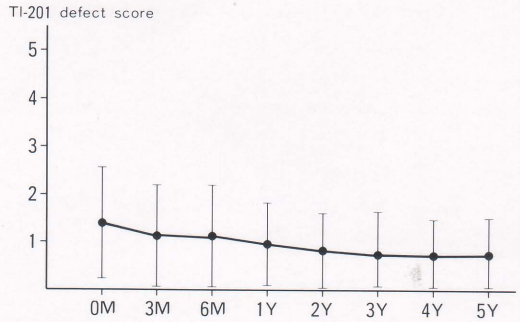

Fig. 6 Changes in ^{201}Tl defect score in patients with acute myocarditis.

tigram showing SPECT images in a 16-year-old female patient. There were persistent defects in anterior areas in coronal and sagittal views.

DISCUSSION

Results of weekly observations of the course of myocarditis and prognostic evaluations for the disease by means of ECG and ultrasound have often been reported, but, from the nuclear medicine point of view, long-term observations of myocarditis have never yet been reported, even though the acute stage of the disease is sometimes evaluated by means of Tl-201-Cl, Tc-99m-PYP, Ga-67-citrate, and In-111-WBC, and cardiac function is often measured by the Tc-99m gated blood pool scan.



Fig. 7a ECG changes of 11 year old myocarditis show V^{1-3} depressed T wave.

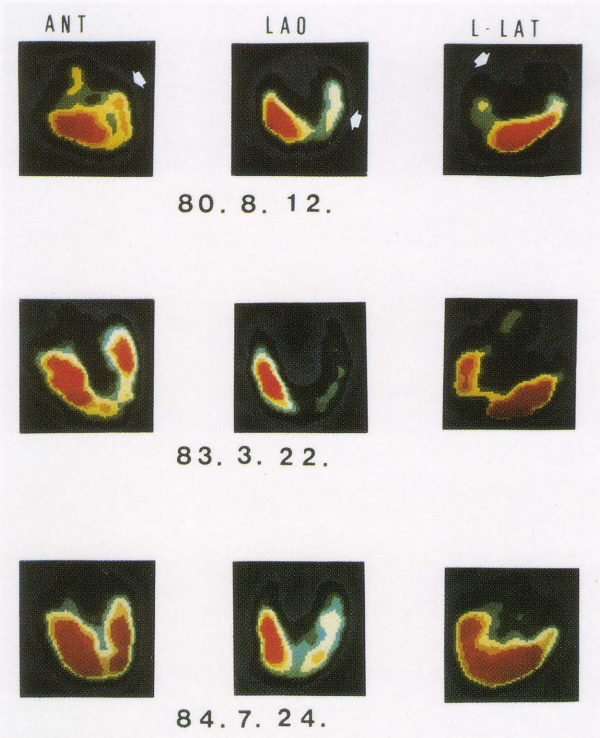

Fig. 7b ^{201}Tl planar images at rest show that anterior lateral defects are improved (white arrows).

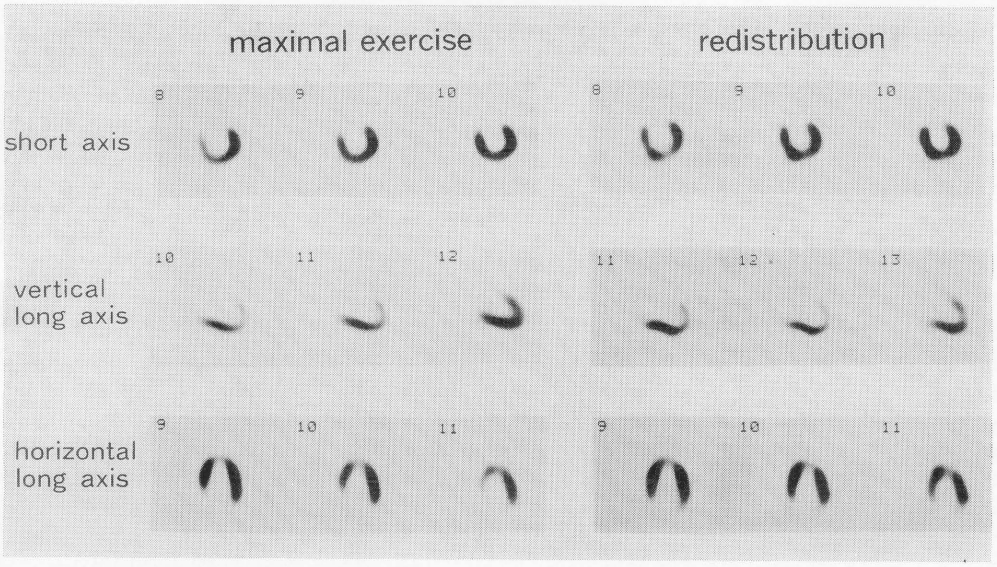

Fig. 8 Exercise ^{201}Tl myocardial SPECT images show anterior persistent defect in patients with 16 year old myocarditis.

The main changes commonly found in the ECG[11,12] are ST-T abnormalities, pseudo-infarction patterns of Q-waves, and various arrhythmias. At the chronic stage of the disease, ST-T abnormalities usually improve gradually. Regarding ultrasonic studies,[13–20] hypokinesis of left ventricular wall motion, enlargement of the right ventricle, and hypertrophy of the ventricular septum have all been reported. Hypertrophy of the ventricular septum is reported to return to normal after passage of the acute stage.

Das et al., specializing in nuclear medicine, have reported on long-term accumulation of Tc-99m-PYP as an expression of inflammatory reaction during the acute stage. They conclude that this is the result of secondary dystrophic calcification due to myocarditis. Further, accumulation images due to Ga-67-citrate, In-111-antimyosin, and perfusion defects due to Tl-201 have also been reported.

(*1*) *Tl-201 myocardial scintigraphy*

Long-term Tl-201 myocardial scintigraphy with planar images revealed that defect images did not completely return to normal, although they were slowly on the mend with part of them existing as focal defects. SPECT images performed during exercise stress tests with a bicycle ergometer did not show redistribution, so that the images found were of persistent defects. This is considered to be due to the development of inflammation and edema during the acute stage and to fibrosis in convalescence as a result of a radionuclide technique. In connection with these findings, Schachne,[1] Tamaki[2] et al. reported that local myocardial cell injury accompanying myocarditis can be linked to small vasculitis and/or focal/multi-focal fibrosis accompanying interstitial lymphocyte infiltration. They therefore assert that local myocardial cell injury becomes a transmural myocardial infarction, resulting in the development of Tl defect images.[21,22] Among the patients on whom we performed coronary angiography, none showed significant stenotic lesions, leading us to deny the existence of infarction in relatively large coronary arteries; however, there is no denying that micro-level infarctions existed. Meanwhile, one of the cases showed patchy defect images in wide-ranging areas and decreases in LVEF and RVEF, and one of the 16 images obtained was similar to that of dilated cardiomyopathy. According to Kawai's report,[23] patients with idiopathic dilated cardiomyopathy showed a high viral titer of Cox B, while the experimental report of Matsumori et al.[24] demonstrated the occurrence of congestive heart failure due to EMC virus infection. Furthermore, Chi-Zung et al.[25] reported a high incidence of myocarditis, which was inferred from myocardial biopsy findings in DCM, while O'Connell et al.[8] report that Ga scintigraphy was useful for ascertaining DCM, which was demonstrated to be myocarditis as a result of biopsy. Thus, there is a strong possibility of an incidence of transitional forms of myocarditis and idiopathic cardiomyopathy. It is therefore necessary to continue follow-up studies.

(*2*) *Tc-99m-HSA gated blood pool scanning*

With regard to cardiac function evaluations with Tc-99m-HSA, LVEF and RVEF decreased during the acute stage. At the chronic stage, LVEF and RVEF were gradually restored to normal as the Tl-201 defect score is improved. This recovery,

however, was slow, and no significant recovery from the onset to 5 years could be obtained. It was inferred from this that cardiac function can continue to decrease for a long period even in children with myocarditis. In exercise stress tests conducted by Das et al.[4] with Tc-99m-RBC, there were no significant differences in the LVEF concentration at rest among subjects and a control group, but when an exercise test was performed, a decrease in cardiac function reserve occurred. It is natural that cardiac function reserves should decrease, given the wide-ranging damage to the myocardium in cases of myocarditis.

Last, but not least, long-term examination of myocardial blood flow and cardiac function in patients with myocarditis is considered to be meaningful, judging from the fact that biochemical changes take place only during the acute stage and that pathological diagnosis can be uncertain, depending on the areas from which biopsy specimens are taken. We, therefore, considered it useful to carry out such examinations, including studies on the relationship between myocarditis and dilated cardiomyopathy once a year from the onset to adulthood.

ACKNOWLEDGEMENTS

We gratefully acknowledge the cooperation of nuclear medicine technologists. We also thank Miss Hisayo Sado for her secretarial work.

Abbreviations

Tc-99m-PYP: Tc-99m-pyrophosphate
Tc-99m-RBC: Tc-99m-red blood cell
LVEF: left ventricular ejection fraction
RVEF: right ventricular ejection fraction

REFERENCES

1. Schachne JS, Stowers SA, Swett, JR DD, Alexander J: Thallium perfusion imaging in myocarditis. *Connecticut Med* 47: 759–761, 1983
2. Tamaki N, Yonekura Y, Kadota K, Kambara H, Torizuka K: Thallium-201 myocardial perfusion imaging in myocarditis. *Clin Nucl Med* 10: 562–566, 1985
3. Wells RG, Ruskin JA, Sty JR: Myocardial imaging Coxsackie myocarditis. *Clin Nucl Med* 11: 661–662, 1986
4. Das SK, Brady TJ, Thrall JH, Pitt B: Cardiac function in patients with prior myocarditis. *J Nucl Med* 21: 689–693, 19qq
5. Ahmad M, Dubiel JP: Tc-99m pyrophosphate myocardial imaging in perimyocarditis. *J Nucl Med* 22: 452–454, 1981
6. Mitsutake A, Nakamura M, Inoh T, Kikuchi Y, Takeshita A, Fujimi S: Intense, persistent myocardial avid technetium-99m-pyrophosphate scintigraphy in acute myocarditis. *Am Heart J* 101: 683–684, 1981
7. Williamson MR, Williamson SL, Seibert JJ: Indium-111 leukocyte scanning localization for detecting early myocarditis in Kawasaki Disease. *AJR* 146: 255–256, 1986
8. O'Connell JB, Henkin RE, Robinson JA, Subramanian R, Scanlon PJ, Gunnar RM: Gallium-67 imaging in patients with dilated cardiomyopathy and biopsy-proven myocarditis. *Circulation* 70: 58–62, 1984
9. Jacobs JC, Rosen JM, Szen IS: Hyme myocarditis diagnosed by gallium scan. *J Pediatrics* 105: 950–952, 1984
10. Khaw BA, Yasuda T, Moore R, Gold HK, Fallon JT, Leinbach RC, Strauss HW, Haber E: In-111-monoclonal antimyosin and Tc-99m pyropshophate imaging in reflowed hearts. *Circulation (Abstr)* 70: II-273, 1984
11. Take M, Sekiguchi M, Hiroe M, Hirosawa K: Long-term follow-up of electrocardiographic findings in patients with acute myocarditis proven by endomyocardial biopsy. *Jpn Circ J* 46: 1227–1234, 1982
12. Marquard C, Schamroth L: An electrocardiographic study of viral myocarditis. *Heart & Lung* 15: 208–210, 1986
13. Nieminen MS, Heikkila J, Karjalainen J: Echocardiography in acute infectious myocarditis. *Am J Cardiol* 53: 1331–1337, 1984
14. Weinhouse E, Wandermann K, Sofer S, Gussarsky Y, Gueron M: Viral myocarditis stimulating dilated cardiomyopathy in early childhood. *Br Heart J* 56: 94–97, 1986
15. Ikaheimo MJ, Takkuren JT: Echocardiography in acute infectious myocarditis. *Chest* 89: 100–102, 1986
16. Kondo M, Takahashi M, Shimono Y, Fujiwara H, Miyazaki S, Matsuda T: Reversible asymmetric septal hypertrophy in acute myocarditis. *Jpn Circulation J* 47: 1304–1309, 1983
17. Hayakawa M, Inoh T, Yokota Y, Kawanishi H, Matsumoto K, Kumaki T, Fukuzaki H: A long-term follow-up study of acute viral and idiopathic myocarditis. *Jpn Circulation J* 47: 1304–1309, 1983
18. Oda T, Hamamoto K, Morinaga H: Left ventricular hypertrophy in non-rheumatic myocarditis in children. *Jpn Circulation J* 46: 1235–1238,1982
19. Hayakawa M, Inoh T, Yokota Y, Kawanishi H, Kumaki T, Takarada A, Seo T, Fukuzaki H: A long term follow up study of acute myocarditis an electrocardiographic and echocardiographic study. *Jpn Circulation J* 48: 1362–1367, 1984
20. Liao PK, Seward JB, Hagler DJ, Driscoll DJ: Acute myocarditis associated with transient marked myocardial thickening and complete atrioventricular block. *Clin Cardiol* 7: 365–362, 1984
21. Woods JD, Nimmo MJ, Mackay-Scollay EM: Acute transmural myocardial infarction associated with active Coxsackie virus B infection. *Amer Heart J* 89: 283–287, 1975
22. Saffitz JE, Schwartz DJ, Southworth W, Murphree S, Rodriguez ER, Ferrans VJ, Roberts WC: Coxa-

ackie viral myocarditis causing transmural right and left ventricular infarction without coronary narrowing. *Am J Cardiol* 52: 644–647, 1983
23. Kawai C: Idiopathic cardiomyopathy. A study on the infectious-immune theory as a cause of the disease. *Jpn Circulation J* 35: 765–770, 1971
24. Matsumori A, Kawai C: An experimental model for congestive heart failure after encephalomyocarditis virus myocarditis in mice. *Circulation* 65: 1230–1235, 1982
25. Zee-Cheng C-S, Tsai CC, Palmer DC, Codd JE, Pennington G, Williams GA: High incidence of myocarditis by endomyocardial biopsy in patients with idiopathic congestive cardiomyopathy. *Am Coll Cardiol* 3: 63–70, 1984