

## Accumulation of Tc-99m-HMPAO-labeled leukocytes in cutaneous lesions of Henoch-Schonlein purpura

T.T. Ha PHAN and Riemer H.J.A. SLART

*Department of Nuclear Medicine & Molecular Imaging, University Medical Center Groningen, The Netherlands*

A 70-year-old man with complicated cruris fracture, treated with an arthrodesis and skin transplantation, complained about persistent pain of the right ankle and skin rashes. Bone and leukocyte scintigraphy were performed because osteomyelitis was suspected. Bone scintigraphy showed abnormal uptake in the ankle. Leukocyte scintigraphy showed only multiple hot spots in the soft tissue. A cutaneous biopsy specimen revealed Henoch-Schonlein vasculitis.

**Key words:** leukocytoclastic vasculitis, Henoch Schonlein, bone scan, Tc-99m-HMPAO

### INTRODUCTION

HENOCH-SCHONLEIN PURPURA (HSP) is the most common forms of vasculitis in children and is less common in adults. The clinical classic of tetrad symptoms includes cutaneous purpura (classically distributed on lower extremities and buttocks), arthralgia/arthritis, abdominal pain and renal disease (nephritis). Henoch-Schonlein purpura is characterized by IgA-deposition in the blood vessel walls. HSP in adults is often difficult to distinguish clinically from other kinds of systemic vasculitis such as hypersensitivity vasculitis. The etiology of HSP is unclear. HSP usually shows self-limited course in children, but disease activity is more severe and difficult to treat in adults. NSAIDs, corticosteroids and immunosuppressive therapy can be used in the case of complications. The overall prognosis is good. Long-term morbidity depends on renal involvement.<sup>1-6</sup>

### CASE REPORT

A 70-year-old man with a complicated communitive fracture of the distal tibia and fibula (cruis fracture) was treated with an arthrodesis of the right upper joint of the

ankle and skin transplantation. The postoperative course was complicated by persistent wound infection that was successfully treated by wound debridement and antibiotics. A few months later this patient was referred to our department for Tc-99m-MDP bone scintigraphy and Tc-99m-HMPAO-labeled leukocyte scintigraphy because of persistent pain and suspicion of osteomyelitis of the right ankle. He also complained about skin rashes on his extremities and trunk. Physical examination revealed erythematous papules, plaques and purpura on the extremities and trunk. Laboratory tests showed only a slight increase of C-reactive protein (CRP), low hemoglobin (Hb) but no leukocytosis and negative serology tests. Urine-analysis revealed erythrocyturia and proteinuria, but normal renal function.

Bone scintigraphy showed increased uptake in the right ankle. Leukocyte scintigraphy showed no increased uptake in the right ankle, but showed multiple abnormal hot spots in the soft tissue. A biopsy specimen of the cutaneous lesion revealed leukocytoclastic vasculitis associated with IgA deposition, representing Henoch-Schonlein vasculitis. There were no clinical and biochemical signs of infection induced vasculitis or systemic vasculitis. Due to the favorable clinical course and the normal renal function in this patient a wait-and-see policy is justified.

### DISCUSSION

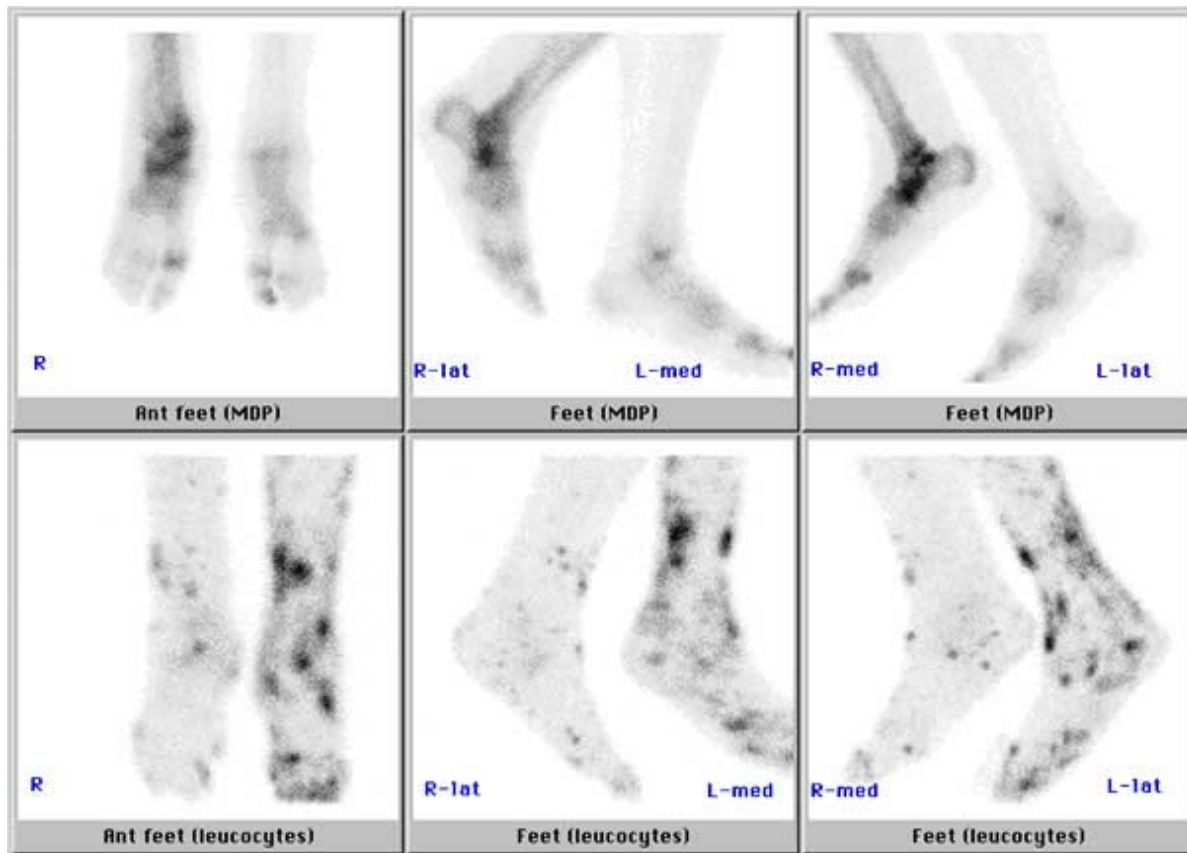
Although the etiology of HSP is unknown, many factors seem to play a role in its pathogenesis, including genetic, environmental and many antigens (e.g. bacterial, viral,

---

Received May 8, 2006, revision accepted July 19, 2006.

For reprint contact: T. T. Ha Phan, M.D., University Medical Center Groningen, Hanzplein 1, Department of Nuclear Medicine and Molecular Imaging, P.O. Box 30.001, 9700 RB Groningen, THE NETHERLANDS.

E-mail: t.t.h.phan@nucl.umcg.nl



**Fig. 1** *Upper row:* Anterior and lateral views of Tc-99m-MDP labeled bone scan showed diffusely increased uptake in the right ankle. Bone scintigraphy is highly sensitive but specificity is lower for the assessment of bone disorders. Therefore, osteomyelitis could not be ruled out in this case. *Lower row:* Anterior and lateral views of Tc-99m-HMPAO-labeled leukocyte scan showed normal uptake in the right ankle compared with the bone scan. In this case osteomyelitis of the right ankle had been ruled out. However, multiple hot spots were visualized in the soft tissue located at the cutaneous lesions on the patient's extremities.

drugs, food-related, vaccination, and insect bites components) factors.<sup>7-12</sup>

In the present case, pain in the ankle joint and skin rashes on the extremities and trunk were present after a postoperative course complicated by persistent wound infection, which was successfully treated with antibiotics. The diagnosis of HSP was confirmed by the histologic feature of IgA deposition in and around the vessel walls in the skin biopsy specimen. This indicated that HSP may be a post-infectious and/or drugs immune-mediated vasculitis in this patient. For this patient no treatment was indicated due to the favorable clinical course with normal renal function and good prognosis.

Nuclear imaging had been described before by several authors in the case of suspicion of HSP in scrotal or testicular area to assess local perfusion and to rule out other causes, e.g. testicular torsion, which requires an other therapeutic approach.<sup>13-15</sup> Our case report showed that the combination of bone and leukocyte scintigraphy

was helpful to rule out osteomyelitis, but that the leukocyte scintigraphy provided additional information about the soft tissue which required further investigation in this patient. Biopsy of the cutaneous lesions revealed inflammation of the small blood vessels, accompanied by IgA deposition. So the uptake mechanism of leukocytes could be associated with an active inflammatory condition in this case.

Leukocyte scintigraphy has been described as a useful diagnostic tool in the diagnosis of systemic vasculitis, in assessing disease activity and delineating the extent of known systemic vasculitis. The degree of accumulation depends on the influx of leukocytes at the affected area. The underlying uptake mechanism could be explained by inflammation, (bacterial) infection, or immune-mediated condition.<sup>16-18</sup>

## REFERENCES

1. Freiman A. Dermacase. Henoch-Schonlein. *Can Fam Physician* 2005; 51: 511–512.
2. Gonzalez-Gay MA, Garcia-Porrúa C, Pujol RM. Clinical approach to cutaneous vasculitis. *Curr Opin Rheumatol* 2005; 17: 56–61.
3. Gedalia A. Henoch-Schonlein purpura. *Curr Opin Rheumatol* 2004; 6: 195–202.
4. Watts RA, Scott DGI. Epidemiology of the vasculitis. *Curr Opin Rheumatol* 2003; 15: 11–16.
5. Garcia-Porrúa C, Calvino MC, Llorca J, Couselo JM, Gonzalez-Gay MA. Henoch-Schonlein purpura in children and adults: clinical differences in a defined population. *Semin Arthritis Rheum* 2002; 32: 149–156.
6. Watts RA, Lane S, Scott DGI. What is known about the epidemiology of the vasculitis? *Best Pract Res Clin Rheumatol* 2005; 19: 191–207.
7. Trapani S, Michela A, Grisolia F, Resti M, Chiappini E, Falcini F, et al. Henoch Schonlein purpura in childhood: Epidemiological and clinical analysis of 150 cases over a 5-year period and review of literature. *Semin Arthritis Rheum* 2005; 35: 143–153.
8. Cassidy JT, Petty RE. Leukocytoclastic vasculitis. In: *Textbook of Pediatric Rheumatology*. Churchill Livingstone, 2001: 569–574.
9. Dillon MJ. Childhood vasculitis. *Lupus* 1998; 7: 259–265.
10. Lahita RG. Influence of age on Henoch Schonlein. *Lancet* 1997; 350: 1116–1117.
11. Amoli MM, Calvino MC, Garcia-Porrúa C, Llorca J, Ollier WE, Gonzalez-Gay MA. Interleukin 1beta gene polymorphism association with severe renal manifestations and renal sequelae in Henoch-Schonlein purpura. *J Rheumatol* 2004; 31: 295–298.
12. Amoli MM, Calvino MC, Garcia-Porrúa C, Ollier WE, Gonzalez-Gay MA. Lack of association between endothelial nitric oxide synthase polymorphisms and Henoch-Schonlein purpura. *J Rheumatol* 2004; 31: 299–301.
13. Huang LH, Yeung CY, Shyur SD, Lee HC, Huang FY, Wang NL. Diagnosis of Henoch-Schonlein purpura by sonography and radionuclear scanning in a child presenting with bilateral acute scrotum. *J Microbiol Immunol Infect* 2004; 37: 192–195.
14. O'Brien WM, O'Connor KP, Horan JJ, Egli DF, Gibbons MD. Acute scrotal swelling in Henoch-Schonlein syndrome: evaluation with testicular scanning. *Urology* 1993; 41: 366–368.
15. Melloul MM, Garty BZ. Radionuclide scrotal imaging in anaphylactoid purpura. *Clin Nucl Med* 1993; 18: 298–301.
16. Fink AM, Miles KA, Wraight EP. Indium-111 labelled leucocyte uptake in aortitis. *Clinical Radiology* 1994; 49: 863–866.
17. Reuter H, Wraight EP, Qasim FJ, Lockwood CM. Management of systemic vasculitis: contribution of scintigraphic imaging to evaluation of disease activity and classification. *QJM* 1995; 88: 509–516.
18. Wraight EP, Llewelyn MB, Lockwood CM. <sup>111</sup>Indium leucocyte imaging in systemic vasculitis. *Nucl Med Commun* 1990; 11: 201–202.