

Megaureter visualization on Tc-99m DMSA scintigraphy

Şeyda TÜRKÖLMEZ, Derya ÖRS and Meliha KORKMAZ

Department of Nuclear Medicine, Ankara Training and Research Hospital, Ankara, Turkey

We present a patient with left-sided obstructed megaureter secondary to neuropathic bladder. He was referred for technetium-99m dimercaptosuccinic acid (^{99m}Tc -DMSA) renal cortical scintigraphy to evaluate renal cortical function. Images obtained 4 hr after injection showed significant activity in the dilated left ureter. When the ureter is visualized on DMSA scan, obstructive megaureter should be considered in the differential diagnosis.

Key words: megaureter, Tc-99m DMSA scintigraphy, obstruction

INTRODUCTION

Technetium-99m dimercaptosuccinic acid (^{99m}Tc -DMSA) scintigraphy is predominantly performed to assess the renal sequelae of urinary tract infection. It is most commonly performed for the evaluation of chronic renal scars, although it is also undertaken in the assessment of acute pyelonephritis. It provides information about the size, number, position and overall morphology of the kidney.^{1,2} In this case, the DMSA study showed the accumulation of radioactivity in the ureter. When the ureter is visualized on DMSA scan, obstructive megaureter should be considered in the differential diagnosis.

CASE REPORT

A 15-year-old boy with a history of recurrent urinary tract infections was referred for ^{99m}Tc -DMSA renal cortical scintigraphy. In the past, he had undergone repair of meningomyelocele. Physical examination and laboratory studies including serum hemoglobin, electrolytes, coagulation profile and creatinine, were normal. Urinalysis, microscopy and culture were negative. His urodynamic study showed hyperreflexia and hypocompliant bladder. The diagnosis was left-sided obstructed megaureter secondary to neuropathic bladder. Abdomino-pelvic ultrasound revealed grade II–III pelvicalyceal dilatation on the

left side and dilated left ureter. The intravenous urography demonstrated dilatation of the pelvicalyceal system of the left kidney, dilatation and tortuosity of the left ureter and sharp cutoff at the ureterovesical junction. There was no reflux on voiding cystourethrography.

Three mCi (111 MBq) ^{99m}Tc -DMSA was injected intravenously after the quality control measurements. Four hr after intravenous administration of DMSA, a planar scintigraphy was performed using a single-head gamma camera, equipped with a low energy all-purpose parallel hole collimator. ^{99m}Tc -DMSA scan demonstrated almost equal cortical function bilaterally. Dilated left ureter was visualized.

DISCUSSION

The term megaureter simply means a large ureter, although a ureter >5 mm in diameter should be considered abnormal in childhood.^{3,4} A megaureter refers to an expanded or widened ureter that does not function normally. It can be due to different underlying abnormalities. Megaureters have been divided into three major groups: refluxing, obstructive, non-refluxing and non-obstructive. Each of these major categories may then be subdivided into a primary and secondary group. Secondary obstructed megaureter might result from functional ureteral obstruction associated with elevated bladder pressures secondary to neuropathic bladder that impedes ureteral emptying.⁵

In normal kidneys ^{99m}Tc -DMSA scintigraphy shows a pattern of tracer distribution reflecting the morphology of the renal cortex. No tracer uptake is seen in the pelvicalyceal system or in the ureter.⁸ ^{99m}Tc -DMSA is excreted in the

Received September 13, 2004, revision accepted January 26, 2005.

For reprint contact: Şeyda Türkölmez, M.D., Fırat Cad, Fırat Apt, 186/20, Beysukent, Ankara, TURKEY.

E-mail: sturkolmez@yahoo.com

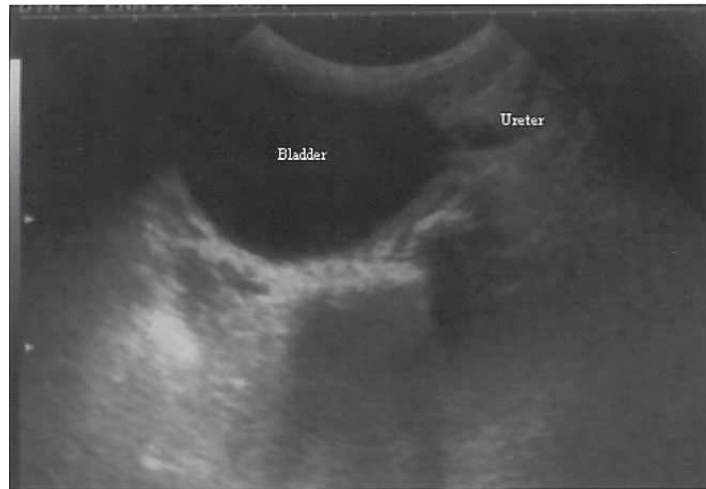


Fig. 1 Ultrasound scan shows a longitudinal view of a megaureter.

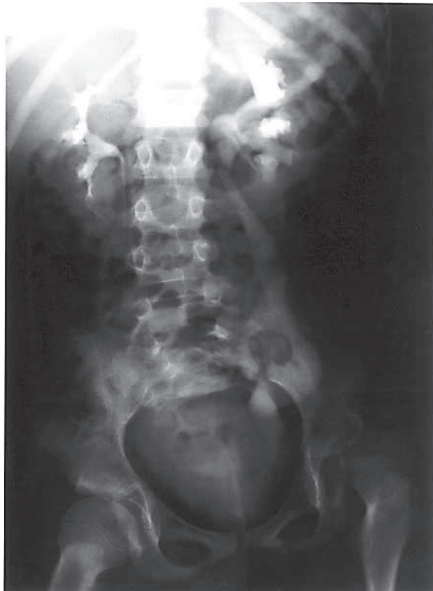

Fig. 2 Intravenous urography shows dilatation of the pelvicalyceal system of the left kidney, dilatation and tortuosity of the left ureter and sharp cutoff at the ureterovesical junction.

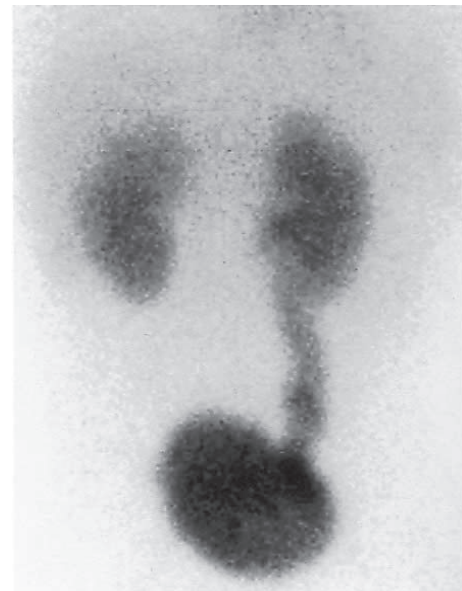

Fig. 3 ^{99m}Tc -DMSA scan (anterior projection) demonstrates almost equal cortical function bilaterally. Dilated left ureter is visualized.

urine in an unchanged form and 8–17% of the injected dose is excreted in the urine by the end of the second hour.⁶ This fact needs to be considered when interpreting scans with possible reflux or obstruction.⁹

In the current case, the dilated ureter was visualized due to significant activity accumulation in the ureter. ^{99m}Tc -DTPA (diethylenetriamine pentaacetic acid) or MAG3 (mercaptoacetyltriglycine) renal dynamic scintigraphy

had not been performed prior to DMSA scintigraphy. So, there was no possibility of retaining DTPA or MAG3 in the dilated ureter and of being fused into the DMSA image. To our knowledge this is the first report on the visualization of hydroureter on DMSA scintigraphy. When the ureter is visualized on DMSA scan in a patient without reflux, obstructive megaureter should be considered in the differential diagnosis.

REFERENCES

1. Goldraich NP, Goldraich IH. Update on DMSA renal scanning in children with urinary tract infection. *Pediatric Nephrol* 1995; 9: 221–226.
2. Murray IPC, Ell PJ (eds). *Nuclear Medicine in Clinical Diagnosis and Treatment*. 1st edition. Churchill Livingstone, 1994: 193–369.
3. Cussen LJ. The morphology of congenital dilatation of the ureter: intrinsic ureteral lesions. *Aust NZ J Syrg* 1971; 41: 185–194.
4. Hellstrom M, Hjalmas K, Jacobsson B, Jodal U, Oden A, et al. Normal ureteral diameter in infancy and childhood. *Acta Radiol* 1985; 26: 433–439.
5. Smith ED, Cussen LJ, Glenn J. Report of working party to establish an international nomenclature for the large ureter. In Bergsma D, Duckett JW (eds): *Birth Defects. Original Articles Series* 1977; 13 (5): 3–6.
6. Enlander D, Weber PM, dos Remedios LV. Renal cortical imaging in 35 patients: Superior quality with Tc-99m DMSA. *J Nucl Med* 1974; 15: 743–748.
7. Taylor A Jr. Quantification of renal function with static imaging agents. *Semin Nucl Med* 1982; 7: 330–344.
8. Handmaker H, Young BW, Lowenstein JM. Clinical experience with Tc-99m-DMSA, a new renal imaging agent. *J Nucl Med* 1973; 16: 23.
9. Wu F, Snow B, Taylor A. Potential Pitfalls of DMSA Scintigraphy in Patients with Ureteral Duplication. *J Nucl Med* 1986; 27: 1154–1156.