

## Diagnostic I-131 scintigraphy in patients with differentiated thyroid cancer: no additional value of higher scan dose

Thi T.H. PHAN,\*\* Karin M. van TOL,\* Thera P. LINKS,\* D. Albertus PIERS,\*\*  
Elisabeth G.E. de VRIES,\*\*\* Robin P.F. DULLAART\* and Pieter L. JAGER\*\*

\*Department of Endocrinology, \*\*Department of Nuclear Medicine and \*\*\*Department of Medical Oncology,  
University Hospital Groningen, The Netherlands

**Objective:** After initial treatment with total thyroidectomy and radioiodine ablation, most follow-up protocols for patients with differentiated thyroid carcinoma contain cyclic diagnostic I-131 imaging and serum thyroglobulin measurements. The applied diagnostic I-131 doses vary between 37 and 370 MBq. The aim of this study was to determine the yield of a diagnostic scan with 370 MBq I-131 in patients with a negative diagnostic scan with 74 MBq I-131. **Methods:** Retrospective evaluation of 158 patients who received a high-dose diagnostic scan with 370 MBq I-131 because of a negative low-dose diagnostic scan with 74 MBq I-131. Special attention was paid to the patients with positive high-dose diagnostic scanning and undetectable serum thyroglobulin levels after thyroid hormone withdrawal. **Results:** In 127 (80%) of patients the 370 MBq I-131 scan was negative, just like the preceding low-dose scan. In 31 (20%) of patients abnormal uptake was present on the 370 MBq diagnostic scan. In 19 of these 31 patients serum thyroglobulin was undetectable. In 15/19 the high-dose diagnostic scan proved either false positive or demonstrated clinically irrelevant minor ablation rests. In only four patients (2.5%) did the high-dose diagnostic scans reveal possibly relevant uptake caused by residual differentiated thyroid cancer. **Conclusion:** In 98% of patients a 370 MBq dose of I-131 for diagnostic WBS had no additional value. The combination of a low-dose diagnostic I-131 scan using only 74 MBq combined with a serum Tg level measurement proved sufficient for correct clinical decision making regarding whether the patient requires additional I-131 therapy.

**Key words:** differentiated thyroid carcinoma, diagnostic I-131 scanning, thyroglobulin, follow-up protocol

### INTRODUCTION

POST-SURGICAL TREATMENT of patients with differentiated thyroid cancer consists of ablation of residual thyroid tissue, followed by cyclic treatments with I-131 until a complete remission has been achieved.<sup>1</sup> Usually the response of a previous treatment with I-131 is evaluated by performing I-131 whole-body scintigraphy (WBS) and

measuring serum thyroglobulin levels (Tg).<sup>1,2</sup> These two response parameters are obtained after bringing the patient to a hypothyroid state by thyroid hormone withdrawal. Complete remission is considered to be present when diagnostic I-131 scanning does not show uptake and Tg-off is undetectable. Although these overall principles are present in nearly all follow-up algorithms, considerable variations exist in the interval between treatment cycles, the diagnostic I-131 dose administered, the interval between administration and scan, the use of the Tg level during thyroid hormone suppression treatment (Tg-on) versus after thyroid hormone withdrawal (Tg-off), and the therapeutic I-131 dose, given to patients who have not reached a complete remission.

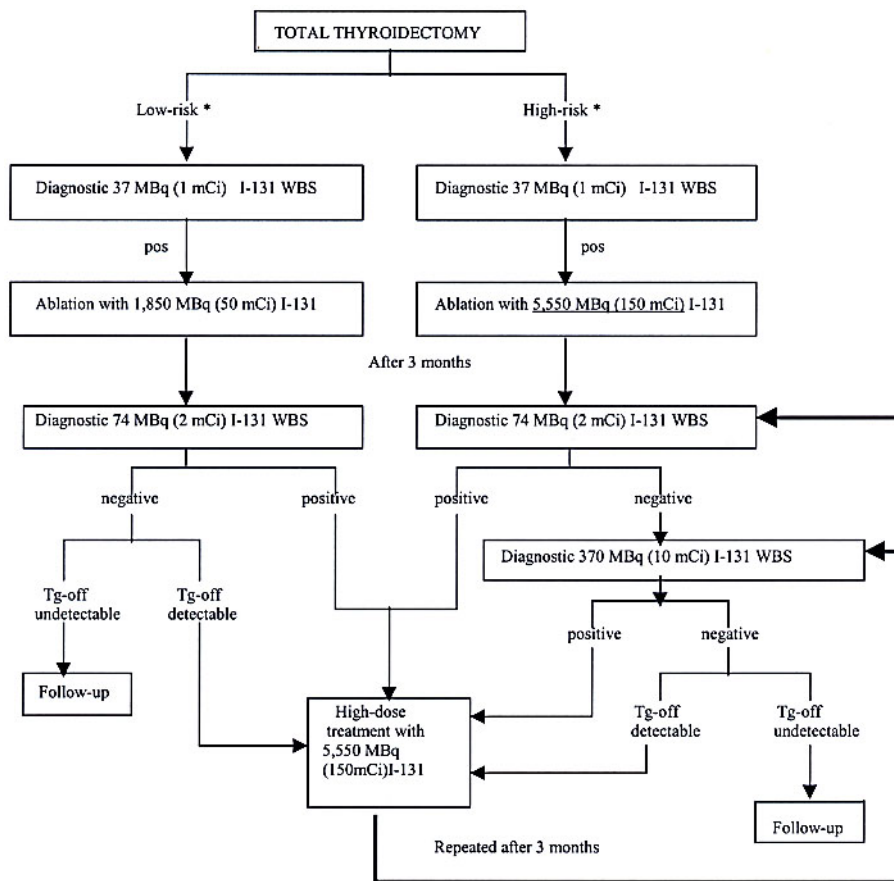
In this paper we focus on the magnitude of the radioactive I-131 dose used for diagnostic scintigraphy, which

Received April 12, 2004, revision accepted July 12, 2004.

For reprint contact: P.L. Jager, Ph.D., M.D., Department of Nuclear Medicine, University Hospital Groningen, P.O. Box 30.001, 9700 RB Groningen, THE NETHERLANDS.

E-mail: P.L.Jager@nucl.azg.nl

**Grant:** Supported by a grant from “De Vereniging voor Academische Ziekenhuizen”, The Netherlands.



\* Explanation low-risk and high-risk see text.

**Fig. 1** Treatment protocol.

varies between 37 and 370 MBq (1–10 mCi) in most centers. Doses below 37 MBq (1 mCi) are generally considered inadequate for accurate visualization of residual thyroid tissue because of poor counting statistics.<sup>3</sup> Higher amounts of I-131 generate better signal-to-noise ratios, which improves lesion detectability.<sup>4,5</sup> The increase in detectability with higher I-131 doses, is further illustrated by the fact that post-treatment scintigraphy is generally regarded as the gold standard for the visualization of residual thyroid tissue. It is, however, impractical and unnecessary to treat every patient with high-dose I-131 in order to obtain a posttherapy WBS for diagnostic purposes.

To allow optimal determination as to whether a patient is in complete remission or requires additional I-131 therapy we applied a two step approach in diagnostic I-131 imaging. In this approach, a 74 MBq (2 mCi) diagnostic dose was administered, followed by a second diagnostic dose of 370 MBq (10 mCi) when the first WBS (acquired after 3 days) did not show abnormal uptake. This method has been used in high-risk patients for many years, because we were unsure whether the first scintigram after 74 MBq (2 mCi) dose was sufficiently reliable

to stop further I-131 treatments in the case of a normal scan. The purpose of this retrospective evaluation was to determine the yield of this high-dose I-131 diagnostic scan in patients with a negative low-dose I-131 diagnostic scan, and compare the results with Tg measurements.

## PATIENTS AND METHODS

### Patients

The Departments of Endocrinology and Nuclear Medicine of the University Hospital Groningen are the major referral center for thyroid cancer patients in the northern part of the Netherlands. All patients treated with I-131 between 1978 and 2000, who underwent both a 74 MBq (2 mCi) and a subsequent 370 MBq (10 mCi) diagnostic WBS, were included in this analysis. Low-risk patients were defined as patients younger than 40 years, with T0–T3 tumors, no lymph node metastases in case of a follicular carcinoma or Hürthle cell carcinoma and absence of distant metastases. High-risk patients were defined as patients over 40 years in age, with extrathyroidal cancer, or lymph node metastases in case of a follicular carcinoma or a Hürthle cell carcinoma, or with distant metastases at

presentation. Through chart review, pathological, clinical and imaging data were collected with respect to treatment and follow-up.

#### *Diagnostic and treatment protocol*

Initial treatment of patients with differentiated thyroid carcinoma consisted of (near-) total thyroidectomy followed by a neck dissection in case of lymph node metastases. Ablation of residual thyroid tissue was performed 4–6 weeks later, while withholding thyroid hormone therapy. One week before ablation patients consumed a low iodine diet. Performing diagnostic I-131 WBS before ablation therapy remains a controversial issue. In this retrospective evaluation pre-ablative diagnostic I-131 WBS after 37 MBq (1 mCi) was performed in all patients. Patients with positive pre-ablative diagnostic scans were subsequently treated/ablated with 1,850 MBq (50 mCi) or 5,550 MBq (150 mCi) I-131.

Low-risk patients underwent ablation using 1,850 MBq (50 mCi) I-131 (Fig. 1), and high-risk patients received 5,550 MBq (150 mCi) I-131. Completeness of ablation was checked 3 months after ablation during hypothyroidism with a diagnostic 74 MBq (2 mCi) I-131 dose followed by a WBS 72 hours later. In case of a negative diagnostic 74 MBq (2 mCi) I-131 WBS, a diagnostic 370 MBq (10 mCi) I-131 dose was administered the same day, followed by a second diagnostic WBS after 72 hours. In case of a positive 74 MBq (2 mCi) or 370 MBq (10 mCi) I-131 diagnostic WBS, treatment with a fixed dose of 5,550 MBq (150 mCi) I-131 followed the next day. A posttreatment WBS was obtained 10 days after the high-dose treatment (Fig. 1). The interval between ablation and subsequent other I-131 treatment cycles was scheduled to be 3 months. After a negative 74 MBq (2 mCi) I-131 WBS and a positive 370 MBq (10 mCi) I-131 WBS further diagnostic evaluation was always performed with a 370 MBq (10 mCi) I-131 WBS. All studied patients therefore underwent only once a 74 MBq (2 mCi) as well as a 370 MBq (10 mCi) I-131 WBS sequence.

Between treatment cycles, patients were on triiodothyronine (75–100 µg/day) suppression therapy. Triiodothyronine was stopped 2 weeks before the diagnostic procedure. During the last week of this period patients consumed a low iodine diet. Tg-off and thyroid stimulating hormone (TSH) levels were measured the same day the diagnostic I-131 dose for WBS was administered during hypothyroidism. Tg levels were measured using a commercial radioimmunoassay (CisBio International, Gif-sur-Yvette, France) with a lower detection limit of 1.5 ng/ml, results being available after 1 wk. Serum TSH was measured by a chemoluminescent immunoassay (Amersham, Little Chalfont, UK) with a normal range of 0.3–5.0 mU/l. Apart from these measurements during hypothyroidism, Tg-on and TSH were also measured during thyroid hormone suppression therapy, at an outpatient visit in between I-131 treatment cycles.

**Table 1** Clinical characteristics of the patients with differentiated thyroid carcinoma, who underwent the two-step approach

| Patient population  |                     |
|---------------------|---------------------|
| Gender              |                     |
| Male (n/%)          | 51 (32%)            |
| Female (n/%)        | 107 (68%)           |
| Age (years, median) | 49 (range 16–82)    |
| Histology           |                     |
| Papillary (n/%)     | 110 (70%)           |
| Follicular (n/%)    | 37 (23%)            |
| Hürthle (n/%)       | 11 (7%)             |
| Stage               |                     |
| T0–T3* (n/%)        | 114 (73%)           |
| T4* (n/%)           | 33 (21%)            |
| N0 (n/%)            | 96 (60%)            |
| N1 (n/%)            | 62 (40%)            |
| M0 (n/%)            | 148 (94%)           |
| M1 (n/%)            | 10 (6%)             |
| TSH (mU/l, median)  | 53.9 (range 12–200) |

\*In 11 patients no data of the initial tumor size was available.

Patients were considered to be in complete remission when the diagnostic or posttherapy I-131 WBS was negative combined with an undetectable serum Tg-off during TSH stimulation after thyroid hormone withdrawal.

#### *Radioiodine scanning and interpretation*

Whole-body scintigraphy was performed 3 days after oral administration of 74 MBq (2 mCi) I-131 using single or double headed gamma cameras (Siemens Orbiter, DIACAM or Multispect2-Hoffman Estates, IL) equipped with high energy collimators. Ten minute adjacent spot views were obtained from the skull level until the upper legs. All images were read by 1 or 2 experienced nuclear medicine physicians. Abnormal uptake was considered to significantly deviate from the well known normal distribution of radioiodine in thyroidectomized patients.<sup>6</sup>

#### *Statistical analysis*

Statistical analysis was performed using SPSS 10.0 software (SPSS, Inc., Chicago, Ill.). Data were expressed as median and ranges.

## RESULTS

During the study period 158 patients underwent both a 74 MBq (2 mCi) and a 370 MBq (10 mCi) I-131 diagnostic WBS. As a consequence of the treatment protocol all 74 MBq (2 mCi) I-131 diagnostic WBS had been negative. Patient characteristics are listed in Table 1. Median follow-up after the diagnostic scans was 5.5 years (range: 2 months–17 years).

A negative 370 MBq (10 mCi) I-131 WBS was found in 127 (80%) of patients (Table 2). Tg-off was undetectable in 75 of these, and these patients were considered in

**Table 2** Distribution of patients divided by results of the 370 MBq (10 mCi) I-131 WBS and serum Tg-off measurements of the total patient population of 158 patients

|                                     | Total number of patients | Detectable Tg-off | Undetectable Tg-off |
|-------------------------------------|--------------------------|-------------------|---------------------|
| Positive 370 MBq (10 mCi) I-131 WBS | 31                       | 12 (7.6%)         | 19 (12.0%)          |
| Negative 370 MBq (10 mCi) I-131 WBS | 127                      | 52 (32.9%)        | 75 (47.5%)          |

**Table 3** Details of the 19 patients with a negative 74 MBq (2 mCi) I-131 WBS, a positive 370 MBq (10 mCi) I-131 WBS and an undetectable Tg-off

| Patient no. | Sex | Age | Hist | TNM   | TSH   | 370 MBq (10 mCi) I-131 WBS | Posttherapy WBS          | Cum I-131 MBq (mCi) | Additional I-131 therapy                                      | Follow-up in months* | Outcome                                     |
|-------------|-----|-----|------|-------|-------|----------------------------|--------------------------|---------------------|---|----------------------|---|
| 1           | F   | 57  | FTC  | 2-0-0 | 43.7  | Thyroid bed                | No uptake                | 5,550 (150)         | No additional treatment                                       | 76                   | CR  |
| 2           | F   | 64  | PTC  | 2-0-0 | 43.0  | Thyroid bed                | No uptake                | 5,550 (150)         | No additional treatment                                       | 20                   | CR  |
| 3           | F   | 31  | PTC  | 2-0-0 | 44.8  | Thyroid bed                | No uptake                | 7,400 (200)         | No additional treatment                                       | 144                  | CR  |
| 4           | M   | 58  | PTC  | 2-0-0 | 91.0  | Neck                       | No uptake                | 5,550 (150)         | No additional treatment                                       | 23                   | CR  |
| 5           | F   | 45  | FTC  | 2-0-0 | 28.3  | Mediastinum                | No uptake                | 5,550 (150)         | No additional treatment                                       | 35                   | CR  |
| 6           | M   | 73  | FTC  | 2-0-0 | 40.3  | Mediastinum                | No uptake                | 1,850 (50)          | No additional treatment                                       | 4                    | CR  |
| 7           | M   | 57  | FTC  | 3-0-0 | 35.4  | Abdomen                    | No uptake                | 5,550 (150)         | No additional treatment                                       | 43                   | CR  |
| 8           | M   | 35  | PTC  | 2-0-0 | 98.0  | Thyroid bed                | Thyroid bed              | 1,850 (50)          | Next diagnostic WBS negative                                  | 169                  | CR  |
| 9           | F   | 38  | PTC  | 2-1-0 | 34.3  | Thyroid bed                | Thyroid bed              | 7,400 (200)         | Next diagnostic WBS negative                                  | 95                   | CR  |
| 10          | M   | 45  | FTC  | 3-0-0 | NA    | Thyroid bed                | Thyroid bed              | 7,400 (200)         | Next diagnostic WBS negative                                  | 135                  | CR  |
| 11          | F   | 52  | PTC  | 2-1-0 | 37.9  | Thyroid bed                | Thyroid bed              | 1,850 (50)          | Next diagnostic WBS negative                                  | 108                  | CR  |
| 12          | F   | 49  | PTC  | 3-0-0 | 51.8  | Thyroid bed                | Thyroid bed              | 1,850 (50)          | Negative diagnostic WBS after additional high-dose dose I-131 | 80                   | CR  |
| 13          | F   | 47  | PTC  | x-1-0 | 49.0  | Thyroid bed                | Thyroid bed              | 5,550 (150)         | Negative diagnostic WBS after additional high-dose dose I-131 | 128                  | CR  |
| 14          | F   | 24  | FTC  | 2-0-0 | 104.3 | Thyroid bed                | Thyroid bed              | 2,590 (70)          | Negative diagnostic WBS after additional high-dose dose I-131 | 123                  | CR  |
| 15          | F   | 42  | PTC  | 2-1-0 | 46.5  | Thyroid bed                | Thyroid bed              | 1,850 (50)          | Negative diagnostic WBS after additional high-dose dose I-131 | 108                  | CR  |
| 16          | M   | 40  | FTC  | 2-0-0 | 64.5  | Thyroid bed                | Thyroid bed, mediastinum | 5,550 (150)         | Negative diagnostic WBS after additional high-dose dose I-131 | 46                   | CR  |
| 17          | F   | 40  | FTC  | 3-0-0 | 40.4  | Neck                       | Neck                     | 1,850 (50)          | Negative diagnostic WBS after additional high-dose dose I-131 | 103                  | CR  |
| 18          | F   | 70  | PTC  | 4-1-0 | 12.6  | Neck                       | Neck                     | 5,550 (150)         | Persisting uptake in neck on subsequent posttherapy WBS       | 4                    | Died of I-131 negative pulmonary metastases |
| 19          | F   | 28  | PTC  | 4-1-1 | 95.0  | Neck                       | Neck                     | 11,100 (300)        | Persisting uptake in neck on subsequent posttherapy WBS       | 2                    | Scheduled for neck dissection               |

M = male, F = female, Hist = histology, PTC = papillary thyroid carcinoma, FTC = follicular thyroid carcinoma, TNM = TNM classification, NA = not available, Cum I-131 = cumulative doses of I-131 in MBq (mCi), \* = follow-up in months after the diagnostic 370 MBq (10 mCi) I-131 WBS, CR = complete remission

complete remission and were not further treated. However, despite the negative 370 MBq (10 mCi) I-131 scan, the remaining 52 patients had detectable Tg-off levels and these patients received additional treatment with 5,550

MBq (150 mCi) I-131.

A positive 370 MBq (10 mCi) I-131 WBS was found in 31 (20%) of patients. These patients were treated the following day with high-dose I-131 (Table 2). Tg-off was

detectable in 12 of these 31 patients, and post treatment scans were also positive. However, 19 patients with a positive 370 MBq (10 mCi) WBS had an undetectable Tg-off level. Because omission of the 370 MBq (10 mCi) could have important drawbacks for this subgroup, the characteristics of these 19 patients were studied in greater detail and are presented in Table 3. Median follow-up in this subgroup was 6.7 years (range: 2 months–11.9 years).

In seven of the 19 patients with a positive 370 MBq (10 mCi) I-131 diagnostic WBS and an undetectable Tg-off, posttreatment WBS was negative (Table 3, patient numbers 1–7). The positive 370 MBq (10 mCi) diagnostic scans in these seven patients were considered false positive readings. Because of the undetectable Tg-off and negative posttherapy WBS, these seven patients did not receive further treatment cycles and were considered to be in complete remission. This remained so until the end of the observation period.

In eight of the 19 patients with a positive 370 MBq (10 mCi) I-131 diagnostic WBS and an undetectable Tg-off, the only location of iodine accumulation was in the thyroid bed itself (Table 3, patient numbers 8–15). Four of them had a negative 370 MBq (10 mCi) I-131 diagnostic WBS in the next treatment cycle 3 months later and four had a positive 370 MBq (10 mCi) I-131 diagnostic WBS again in the next treatment cycle. After additional treatment with 5,550 MBq (150 mCi), the 370 MBq (10 mCi) WBS in the next cycle became negative. Serum Tg-off and Tg-on remained undetectable until the end of observation. No Tg-antibodies could be detected in these cases. These eight patients were considered to be in complete remission after the last negative diagnostic WBS. The fact that uptake was visible only in the thyroid bed was presumably the result of incomplete ablation of normal thyroid tissue instead of residual thyroid carcinoma tissue.

In only four of the 19 patients with a positive 370 MBq (10 mCi) I-131 diagnostic WBS and negative Tg-off, radioiodine uptake outside the thyroid was present (Table 3, patient numbers 16–19). These four patients received a high-dose treatment with 5,550 MBq (150 mCi) I-131. In two patients the diagnostic WBS of the next cycle turned out to be negative and they were considered to be in complete remission. In the other two patients, uptake in the neck persisted, but evidence for persistent disease was already found by other diagnostic procedures. One patient had I-131 negative pulmonary metastases on a chest X-ray and additional I-131 therapy was discontinued, and the other patient had enlarged cervical lymph nodes on an MRI and was scheduled for a neck dissection. These two latter patients probably had less functional differentiated thyroid tumors, because of the loss of the capacity to secrete Tg and a diminished ability to accumulate I-131.

## DISCUSSION

It is clear from this study that scintigraphy with a radioac-

tive dose as low as 74 MBq (2 mCi) I-131 is sufficient for correct clinical decision making with regards to further radioiodine treatment, when combined with Tg-off measurements. Higher dose of 370 MBq (10 mCi) for WBS after a negative 74 MBq (2 mCi) WBS produced positive results in only 20% of patients. In combination with Tg-off data this yield is further reduced to 12%, most of which appeared due to false positive scan interpretations due to equivocal minor abnormalities or minor amounts of residual normal thyroid tissue after ablation. Nowadays, it is believed that residual normal thyroid tissue is not a matter of concern for the outcome and prognosis of patients with differentiated thyroid cancer, and that these patients do not require additional radioiodine.<sup>7</sup> Most physicians in other treatment centers not using the two step approach, would have considered these 19 (12%) patients in complete remission after ablation and the first follow-up diagnostic I-131 WBS. In theory this might have harmed these patients, because they had a positive high-dose diagnostic scan. However, in 15 of 19 patients a complete remission was achieved during the next treatment cycle, and follow-up in this subgroup was unremarkable. Omitting radioiodine treatment in these 15 patients would probably have been the correct decision.

As a final result, in only four patients, 2.5% of the whole group of 158 patients, possibly relevant uptake at the high-dose diagnostic WBS, would have been left untreated if the high-dose diagnostic WBS had not been performed. However, in two of these four patients it was unclear whether the high-dose diagnostic I-131 in fact contributed to clinical decision making, because evidence for persistent disease had already been found by other diagnostic procedures. In the other two patients uptake disappeared after an additional high-dose of I-131. It can be argued that these two latter patients, with undetectable serum Tg-off and negative low-dose diagnostic imaging, have only very limited disease not affecting their life expectancy. In 98% of the patients the 370 MBq (10 mCi) I-131 diagnostic WBS turned out to have no additional value. The combination of a low-dose diagnostic I-131 WBS with 74 MBq (2 mCi) and a serum Tg-off level measurement was in these patients sufficient for correct clinical decision making regarding whether the patient requires additional I-131 therapy. Therefore, the yield of a high-dose diagnostic WBS appeared to be too low to justify application in patients with differentiated thyroid carcinoma and negative low-dose diagnostic WBS.

These results contradict with the generally better detectability of residual thyroid tissue with higher I-131 scanning doses.<sup>4,5</sup> However, a possible disadvantage of higher diagnostic scanning doses is that they might adversely affect further therapy. The applied diagnostic I-131 dose could impair the ability of the residual thyroid carcinoma tissue to accumulate the subsequent applied high-dose I-131 dose.<sup>8</sup> This phenomenon is termed 'stunning.'<sup>9</sup> The degree of stunning probably depends on the



absorbed radiation dose, which varies with the administered diagnostic I-131 dose and the time between the diagnostic and therapeutic I-131 dose. Some authors demonstrated that stunning was not seen with diagnostic I-131 doses of 185 MBq (5 mCi) or lower,<sup>9,10</sup> whereas stunning was frequently observed after a diagnostic dose of 370 MBq (10 mCi) I-131.<sup>8</sup> There is also evidence that a short time interval between the administration of the diagnostic and therapeutic I-131 dose may diminish the effect of stunning.<sup>10</sup> Most authors who have described stunning administered the therapeutic I-131 dose several days after the completion of the diagnostic I-131 scan.<sup>8,11–13</sup> Stunning is not seen when the therapeutic dose is administered within several hours.<sup>10</sup> Finally, the time interval between the administration of a high-dose of I-131 and the performance of a posttherapy WBS may influence the observation of stunning.<sup>9,14</sup> A longer time interval allows more time for soft-tissue clearance of I-131, which results in a higher sensitivity of the posttherapy WBS. In the study of Waxman et al. who demonstrated the higher sensitivity of high-dose diagnostic I-131 of 370 MBq (10 mCi) compared to the lower dose of 74 MBq (2 mCi), no stunning was seen at the posttherapy WBS, performed 5–10 days after doses of 1,110–3,700 MBq (30–100 mCi) I-131.<sup>4</sup> In our study we used a rather short interval (1 day) between the diagnostic WBS and the administration of the therapeutic I-131 dose and a long interval (10 days) between the therapeutic I-131 dose and the posttherapy WBS. Stunning is therefore unlikely to have confounded our results. This is further illustrated by the 31 patients treated with high-dose radioiodine after the 370 MBq (10 mCi) dose. In theory the uptake of the treatment dose could have been diminished due to stunning. This might have indeed generated the negative posttreatment scans in 7 of 31 patients. However, the final outcome of treatment was not different in this subgroup as compared to all patients treated at our institution between 1978 and 2000 (10-yr subgroup survival 85% versus 87% for entire group,  $p = 0.64$ ). Even if stunning had confounded these results, the effect would have been quite small and not affected the final outcome in our cohort.

In conclusion, our original fear that a low dose of 74 MBq (2 mCi) I-131 for WBS was too low on which to base treatment decisions proved incorrect. The yield of a higher diagnostic radioactive dose of 370 MBq (10 mCi) proved to be too low, when combined with Tg-off measurements.

## REFERENCES

- Schlumberger MJ. Papillary and follicular thyroid carcinoma. *New Engl J Med* 1998; 338: 297–306.
- Mazzaferrri EL, Kloos RT. Current approaches to primary therapy for papillary and follicular thyroid cancer. *J Clin Endocrinol Metab* 2001; 86: 1447–1463.
- Nemac J, Rohling S, Zamrazil V, Pohunkova D. Comparison of the distribution of diagnostic and thyroablative I-131 in the evaluation of differentiated thyroid cancers. *J Nucl Med* 1979; 20: 92–97.
- Waxman A, Ramanna L, Chapman N, Chapman D, Brachman M, Tanasescu D, et al. The significance of I-131 scan dose in patients with thyroid cancer: Determination of ablation: Concise communication. *J Nucl Med* 1981; 22: 861–865.
- Ramanna L, Waxman AD, Brachman MB, Tanasescu DE, Chapman N, Braunstein G. Treatment rationale in thyroid carcinoma: effect of scan dose. *Clin Nucl Med* 1985; 10: 687–689.
- Sherman SI, Tielens ET, Sostre S, Wharam MD, Ladenson PW. Clinical utility of post-treatment radioiodine scans in the management of patients with thyroid carcinoma. *J Clin Endocrinol Metab* 1994; 78: 629–634.
- Greenler DP, Klein HA. The scope of false-positive iodine-131 images in thyroid carcinoma. *Clin Nucl Med* 1989; 14: 111–117.
- Park HM, Perkins OW, Edmondson JW, Shnute RB, Manatunga A. Influence of diagnostic radioiodines on the uptake of ablative dose of iodine-131. *Thyroid* 1994; 4: 49–54.
- Pacini F, Lippi F, Formica N, Elisei R, Anelli S, Ceccarelli C, et al. Therapeutic doses of iodine-131 reveal undiagnosed metastases in thyroid cancer patients with detectable serum thyroglobulin levels. *J Nucl Med* 1987; 28: 1888–1891.
- Cholewinski SP, Yoo KS, Klieger PS, O'Mara RE. Absence of thyroid stunning after diagnostic whole-body scanning with 185 MBq <sup>131</sup>I. *J Nucl Med* 2000; 41: 1198–1202.
- Jeevanram RK, Shah DH, Sharma SM, Ganatra RD. Influence of initial large dose on subsequent uptake of therapeutic radioiodine in thyroid cancer patients. *Nucl Med Biol* 1986; 13: 277–279.
- Muratet JP, Dacer A, Minier JF, Larra F. Influence of scanning doses of iodine-131 on subsequent first ablative treatment outcome in patients operated on for differentiated thyroid carcinoma. *J Nucl Med* 1998; 39: 1546–1550.
- Legar FA, Izembart M, Dagousset F, Barritault L, Baillet G, Chevalier A, et al. Decreased uptake of therapeutic doses of iodine-131 after 185-MBq iodine-131 diagnostic imaging for thyroid remnants in differentiated thyroid carcinoma. *J Nucl Med* 1998; 25: 242–246.
- Morris LF, Waxman AD, Braunstein GD. The nonimpact of thyroid stunning: remnant ablation rates in <sup>131</sup>I-scanned and non-scanned individuals. *J Clin Endocrinol Metab* 2001; 86: 3507–3511.
- Cailleux AF, Baudin E, Travagli JP, Ricard M, Schlumberger M. Is diagnostic iodine-131 scanning useful after total thyroid ablation for differentiated thyroid cancer? *J Clin Endocrinol Metab* 2000; 85: 175–178.
- Ozata M, Suzuki S, Miyamoto T, Liu RT, Fierro-Renoy F, DeGroot LJ. Serum thyroglobulin in the follow-up of patients with treated differentiated thyroid cancer. *J Clin Endocrinol Metab* 1994; 79: 98–105.
- Pacini F, Agate L, Elisei R, Capezone M, Ceccarelli C, Lippi F, et al. Outcome of differentiated thyroid cancer with detectable serum Tg and negative diagnostic <sup>131</sup>I whole body scan: Comparison of patients treated with high <sup>131</sup>I activities versus untreated patients. *J Clin Endocrinol Metab* 2001; 86: 4092–4097.