

A simple method for the detection of abnormal brain regions in Alzheimer's disease patients using [¹¹C]MP4A: Comparison with [¹²³I]IMP SPECT

Tsuneyoshi Ota,^{*1,2} Hitoshi Shinotoh,^{*1,3} Kiyoshi Fukushi,^{*1} Shin-ichiro Nagatsuka,^{*1,4} Hiroki Namba,^{*5} Masaomi Iyo,^{*6} Akiyo Aotsuka,^{*1,7} Noriko Tanaka,^{*1,8} Koichi Sato,^{*1,6} Tetsuya Shiraiishi,^{*1,6} Shuji Tanada,^{*1} Heii Arai^{*2} and Toshiaki Irie^{*1}

^{*1}Department of Medical Imaging, National Institute of Radiological Sciences

^{*2}Department of Psychiatry, Juntendo University School of Medicine

^{*3}Asahi Hospital for Neurological Diseases

^{*4}ADME/TOX Research Institute, Daiichi Pure Chemical Co., Ltd.

^{*5}Department of Neurosurgery, Hamamatsu University School of Medicine

^{*6}Department of Psychiatry, Chiba University School of Medicine

^{*7}Department of Neurology, Chiba University School of Medicine

^{*8}Department of Neurosurgery, Tokyo Women's Medical College Daini Hospital

We have developed a radiolabeled lipophilic acetylcholine analogue, *N*-[¹¹C]methylpiperidin-4-yl acetate ([¹¹C]MP4A) to measure brain acetylcholinesterase (AChE) activity by positron emission tomography (PET) *in vivo*. Aiming to develop a new SPECT tracer similar to MP4A, we first proposed a simple method for diagnosing Alzheimer's disease (AD) using [¹¹C]MP4A PET. We performed [¹¹C]MP4A PET and *N*-isopropyl [¹²³I]iodoamphetamine ([¹²³I]IMP) SPECT in 13 patients with AD and in 17 normal controls (NC). We calculated the ratio of radioactivity of the cortical region of interest (ROI) to that of the cerebellum measured with [¹¹C]MP4A PET (MP4A ratio) and the ratio of regional cerebral blood flow (rCBF) to that of the cerebellum measured with [¹²³I]IMP SPECT (IMP ratio). Eleven cortical ROIs were placed in the frontal, sensorimotor, temporal, parietal, and occipital cortices in both hemispheres and in the posterior cingulate cortex, and *z*-score was calculated in each ROI in patients with AD compared with NC. When the *z*-score was 2 or more in a ROI, it was defined as a positive ROI. When a patient had 3 or more positive ROIs, the patient was diagnosed as having AD. The reduction in the MP4A ratio was greater than that in the IMP ratio in all cortical ROIs except for in the right parietal cortex and cingulate cortex in patients with AD. MP4A ratio method showed 92% sensitivity and the IMP ratio method 69% sensitivity for the diagnosis of AD. These results encourage us to develop a new SPECT tracer similar to MP4A for the diagnosis of AD.

Key words: [¹¹C]MP4A PET, [¹²³I]IMP SPECT, comparison, Alzheimer's disease, simple ratio analysis

INTRODUCTION

DEGENERATION of the ascending cholinergic system is well known in Alzheimer's disease (AD). Neurochemical analysis of postmortem AD brains has repeatedly shown reduction in cortical acetylcholinesterase (AChE) as well as choline acetyltransferase (ChAT).^{1–3} We developed a radiolabeled lipophilic acetylcholine analogue, *N*-[¹¹C]methylpiperidin-4-yl acetate ([¹¹C]MP4A), which

Received October 6, 2003, revision accepted January 15, 2004.

For reprint contact: Toshiaki Irie, Ph.D., Section of Radiopharmaceuticals and Radiopharmacology, Department of Medical Imaging, National Institute of Radiological Sciences, 4–9–1 Anagawa, Inage-ku, Chiba 263–8555, JAPAN.

E-mail: t_irie@nirs.go.jp

enables measurement of regional brain AChE activity in living humans by positron emission tomography (PET) and three-compartment analysis with non-linear least squares (NLLS) analysis.⁴ Furthermore, we have developed some simplified means of analysis without the use of an arterial input function, such as shape analysis⁵ and reference tissue-based linear least squares analysis (RLLS).⁶ With these methods, we have shown widespread reduction of AChE activity in the cerebral cortex in patients with AD. *N*-[¹¹C]methylpiperidin-4-yl propionate ([¹¹C]MP4P), a sister compound of [¹¹C]MP4A, has also been used as a PET radiotracer for pathophysiological studies of AD.^{7,8} The successful use of these techniques for the detection of cholinergic abnormalities in dementias prompted us to develop similar radiotracers for single photon emission computed tomography (SPECT),⁹ because SPECT is more widely available than PET. Before the development of such SPECT radiotracers, however, here we compared the diagnostic efficiency of [¹¹C]MP4A PET and *N*-isopropyl [¹²³I]iodoamphetamine ([¹²³I]IMP) SPECT. Since SPECT scanners cannot perform fast dynamic scans, we performed a simple ratio analysis, the simple measurement of the ratio of cortical to cerebellum [¹¹C]MP4A radioactivity at 30 to 40 min after [¹¹C]MP4A injection, in order to compare the results with that in the SPECT study.

METHOD

Subjects

We studied 13 patients with AD (age 64.4 ± 7.4 , range 52–80; 6 men and 7 women) who fulfilled the criteria for probable AD by the National Institute of Neurological and Communicative Disorders and Stroke-Alzheimer's Disease and Related Disorders Association (NINCDS-ADRDA).¹⁰ The mean Mini-Mental State Examination (MMSE)¹¹ score was 17.5 ± 2.8 in AD patients. Seventeen age-matched healthy subjects (age 62.6 ± 12.5 , range 43–89; 11 men and 6 women, MMSE score 29.2 ± 1.1) participated in this study as normal controls (NC).

All studies were given prior approval by the Ethics and Radiation Safety Committees of the National Institute of Radiological Sciences, Chiba, Japan. Written informed consent was obtained from all participants and/or their close family members prior to the study.

[¹¹C]MP4A PET

PET scans were performed under resting condition with the patients' eyes closed and head immobilized by a resinous plate held between the teeth using a Siemens EXACT 47 scanner (Siemens/CTI, Knoxville, TN). The details of the procedure were previously reported.¹² After a 10-min transmission scan, [¹¹C]MP4A (555–740 MBq) was injected into the right cubital vein. Arterial blood was withdrawn from a catheter placed in the left radial artery at the predetermined interval for 15 min. Starting at the

time of injection, 35 sequential frames were acquired dynamically over a period of 40 min. All emission scans were reconstructed using a Hanning filter with cut-off intensity of 0.5 (cycle/projection ray). The spatial resolution was 9 mm × 9 mm × 6 mm full width at half maximum after reconstruction. Regions of interest (ROIs) were manually determined in the bilateral superior frontal, sensorimotor, temporal, parietal and occipital cortices, and in the posterior cingulate cortex and the cerebellum on both hemispheres with reference to the corresponding MRI. For the quantification of AChE activity, a three-compartment model was applied. The three compartments consisted of an arterial blood compartment and two cerebral tissue compartments representing unmetabolized and metabolized radiotracer. The rate constant K_1 represents the rate of penetration of the tracer into the brain, k_2 represents the rate of tracer washout and k_3 represents the rate of hydrolysis of [¹¹C]MP4A by AChE (an index of AChE activity). These three rate constants were determined by fitting brain theoretical curves to observed brain PET data using a weighted non-linear least squares (NLLS) analysis.^{4,12} In addition to quantitative analysis of brain AChE activity, a simple ratio analysis was also performed to compare the results with that in the SPECT study. The radioactivity ratio of a target to the cerebellum (mean value of both hemispheres) 30 to 40 min after injection was calculated in each cortical ROI (MP4A ratio).

[¹²³I]IMP SPECT

Within 2 weeks of the PET study, all subjects underwent [¹²³I]IMP SPECT at the Chiba Cancer Center. The rCBF in the brain was quantified by a microsphere model analysis.^{13,14} Subjects were positioned supine on a couch in a quiet environment with their eyes covered. Each subject's head was positioned using positioning lasers in the head-holder. A cannula was inserted in the right dorsalis pedis artery for continuous blood sampling. Patients were injected intravenously with 222 MBq of [¹²³I]IMP (Nihon Medi-Physics, Nishinomiya, Hyogo) over 10–15 sec, and continuous sampling of arterial blood was performed for 5 min after the initiation of the IMP injection. SPECT images were obtained with a three-head rotating gamma-camera (GCA 9300A; Toshiba, Tokyo) with a high resolution fan beam collimator. The first data acquisition was started 4 min after IMP injection and continued for 2 min ("super-early" images) with two returns of pendulous rotation at an angle of 120 degrees, and the second data acquisition was from 25 to 50 min after IMP injection ("early" images). ROIs were placed manually in the same brain regions as those in the previous PET study by the same investigator (H.N.). Since the head position of the patients did not change between the two SPECT scans, the ROIs were determined in the "early" SPECT images, which had much better image quality than the "super-early" images, and were then applied to both the "super-early" and "early" images for

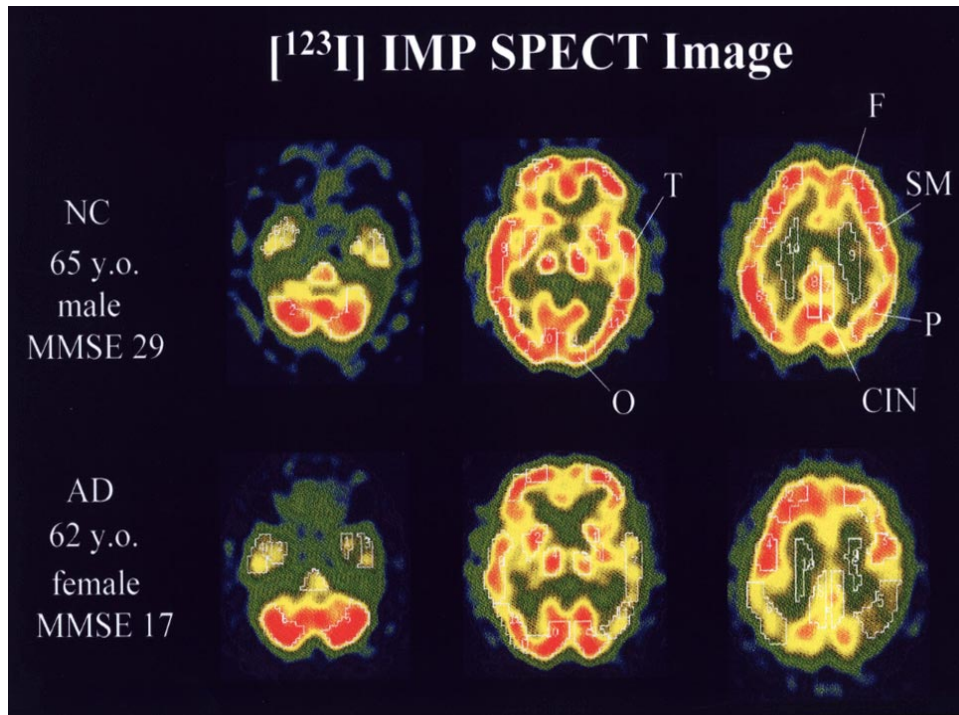


Fig. 1 Typical [^{123}I]IMP SPECT image (“early” images) in a normal subject (*top*) and a patient with AD (*bottom*). There is a relatively large reduction in the temporoparietal cortices and posterior cingulate cortex in patients with AD. The abbreviations of region names are as follows: F (superior frontal cortex), SM (sensorimotor cortex), T (temporal cortex), P (parietal cortex), OC (occipital cortex), CIN (posterior cingulate cortex).

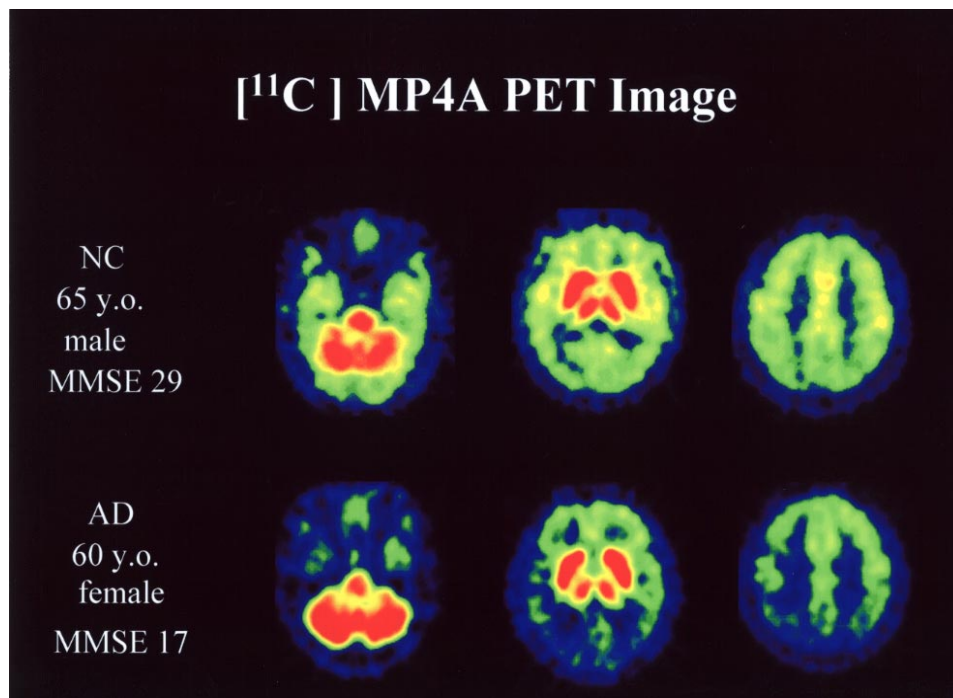


Fig. 2 Typical [^{11}C]MP4A images in a patient with AD and a normal subject. PET brain images of the radioactivity distribution in brains obtained 20–40 min after injection of [^{11}C]MP4A image (late image) in a normal subject (*top*) and a patient with AD (*bottom*). The accumulation of radioactivity reflects not only regional AChE activity but also rCBF. The [^{11}C]MP4A image showed a more pronounced and extensive reduction than the [^{123}I]IMP SPECT image especially in the bilateral temporal and occipital cortices.

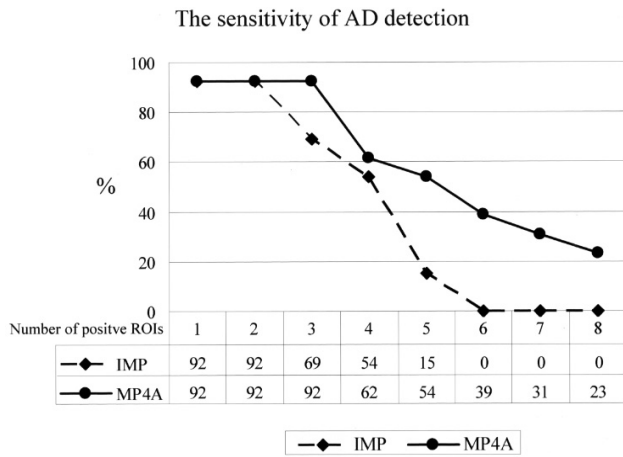


Fig. 3 Relationship between the sensitivity of AD detection and the number of positive ROIs. Based on the sensitivity to detect 3 positive ROIs, the diagnosis of AD was 69% with the IMP ratio, and 92% with the MP4A ratio.

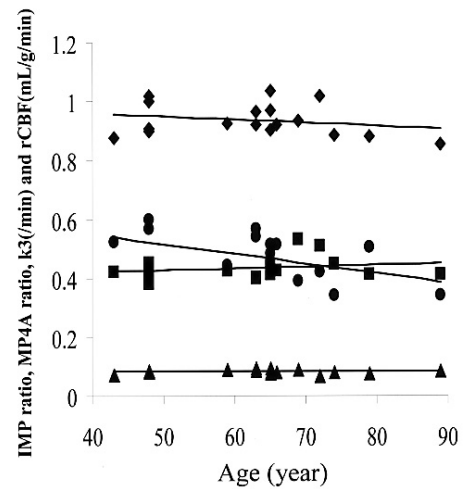


Fig. 4 The age effect on IMP ratio, MP4A ratio, k_3 values and rCBF. Correlation coefficients of mean cortical IMP ratio, MP4A ratio, k_3 values and rCBF with age in the normal controls were 0.24 (n.s.), 0.19 (n.s.), 0.01 (n.s.) and 0.54 ($p < 0.05$), respectively. Closed diamonds indicate IMP ratio, closed squares MP4A ratio, closed triangles k_3 values (/min) and closed circles rCBF (ml/g/min).

Table 1 Values for target/cerebellum ratio of MP4A and IMP and reduction in 13 patients with AD

ROI	NC			AD			
	Mean	SD	COV (%)	Mean	SD	Reduction (%)	
MP4A ratio	LF	0.42	0.04	9.3	0.36	0.03	-14***
	RF	0.42	0.04	8.8	0.35	0.04	-18***
	LSM	0.48	0.04	8.7	0.41	0.03	-14***
	RSM	0.46	0.04	8.2	0.38	0.04	-17***
	LT	0.49	0.03	6.3	0.36	0.05	-25***
	RT	0.46	0.04	8.4	0.34	0.03	-25***
	LP	0.41	0.05	13.2	0.32	0.02	-21***
	RP	0.39	0.05	12.2	0.31	0.03	-22***
	LO	0.39	0.03	6.7	0.32	0.03	-18***
	RO	0.38	0.06	15.0	0.32	0.05	-15**
MP4A ratio	CIN	0.49	0.06	12.8	0.41	0.05	-17***
IMP ratio	LF	0.91	0.07	7.9	0.82	0.11	-10*
	RF	0.92	0.08	9.1	0.82	0.12	-10*
	LSM	0.91	0.07	8.1	0.89	0.10	-2
	RSM	0.95	0.08	8.4	0.89	0.14	-7
	LT	0.96	0.06	6.5	0.86	0.12	-11*
	RT	0.96	0.06	6.4	0.89	0.13	-7
	LP	0.91	0.09	10.2	0.76	0.11	-16***
	RP	0.90	0.07	8.3	0.71	0.15	-21***
	LO	0.97	0.10	9.8	0.92	0.10	-5
	RO	0.96	0.09	9.7	0.95	0.08	0
IMP ratio	CIN	0.93	0.08	8.6	0.77	0.12	-18***

F = frontal, SM = sensorimotor, T = temporal, P = parietal, O = occipital, CIN = posterior cingulate, L = left, R = right
Significant reduction between the normal controls and AD, *: $p < 0.05$, **: $p < 0.01$, ***: $p < 0.001$

quantitative measurement of the radioactivity. The CBF was quantitatively measured based on the microsphere model using the super-early SPECT images and the blood

sample taken for 5 min after IMP injection. A fixed value for the octanol extraction fraction (0.8) was used.^{13,15,16} The CBF ratio (or radioactivity ratio) of a target cortical

Table 2 Values for k_3 (/min) and CBF (ml/g/min) and reduction in 13 patients with AD

ROI	NC			AD		
	Mean	SD	COV (%)	Mean	SD	Reduction (%)
LF	0.077	0.010	13.2	0.066	0.008	-14**
RF	0.080	0.010	12.6	0.067	0.013	-17*
LSM	0.102	0.011	10.9	0.083	0.008	-19***
RSM	0.095	0.013	13.7	0.080	0.011	-15**
LT	0.090	0.010	11.3	0.065	0.011	-28***
RT	0.084	0.007	8.7	0.062	0.012	-25***
LP	0.076	0.012	15.5	0.055	0.007	-27***
RP	0.073	0.008	11.6	0.054	0.013	-27***
LO	0.068	0.009	13.3	0.056	0.009	-19***
RO	0.067	0.008	12.2	0.055	0.013	-17*
k_3 CIN	0.093	0.015	15.6	0.069	0.010	-26**
LF	45.9	7.1	15.4	38.0	10.4	-17*
RF	46.6	8.0	17.2	37.6	10.5	-19*
LSM	45.2	6.6	14.7	40.7	9.8	-10
RSM	47.7	9.1	19.2	40.6	10.3	-15
LT	48.6	7.7	15.7	39.0	9.0	-20**
RT	48.8	9.3	19.0	41.1	11.1	-16
LP	46.1	8.4	18.2	35.0	9.1	-24**
RP	45.6	7.9	17.3	32.6	8.6	-29***
LO	48.9	7.5	15.4	42.8	11.9	-13
RO	48.6	9.1	18.6	45.3	10.6	-7
CBF CIN	49.4	9.0	18.2	35.0	10.3	-29**

The abbreviations of region names are the same as in Table 1.

Significant reduction between the normal controls and AD, *: $p < 0.05$, **: $p < 0.01$, ***: $p < 0.001$

ROI to the cerebellum (mean value of both hemispheres) was calculated in each subject (IMP ratio).

Statistical analysis

The percentage reductions of MP4A ratios and IMP ratios in the AD group were compared to those in the NC group in each cortical ROI using t-test. The correlation with MP4A ratio, k_3 values and K_1 values was also examined. The reduction of MP4A ratios, IMP ratios, k_3 values and rCBF in all 11 cortical ROIs in each AD patient compared to the NC group were calculated in z-score. When the z-score was 2 or more in a ROI, the ROI was defined as positive. When a subject had 3 or more positive ROIs from among the 11 ROIs, the subject was diagnosed as having AD. The reason why we diagnosed a subject as having AD only when the subject had 3 or more positive ROIs was that we were afraid that defining only 1 or 2 positive ROIs as AD might result in the inclusion of false positives. Then, the diagnostic sensitivities of MP4A ratio and IMP ratio were compared. We also investigated the effect of aging on MP4A ratio, IMP ratio, k_3 values and rCBF in the whole cerebral cortex.

RESULTS

$[^{123}\text{I}]\text{IMP}$ SPECT images showed hypoperfusion in the temporoparietal cortex in most AD patients compared

with NC (Fig. 1). $[^{11}\text{C}]\text{MP4A}$ PET images at the late phase showed reduction of radioactivity accumulation in the diffuse cerebral cortices in all AD patients compared with NC (Fig. 2). Both the regional MP4A ratios and IMP ratios were severely reduced in most AD patients compared with NC (Table 1). The percentage reduction of MP4A ratios was significantly greater than that of IMP ratios in the bilateral temporal ($p = 0.0005$ in the left, 0.0001 in the right) and occipital ($p = 0.0021$ in the left, 0.0038 in the right) cortices, and in the left sensorimotor cortex ($p = 0.0026$) in AD patients. The MP4A ratios were correlated better with k_3 values ($r = 0.69$) than with K_1 values ($r = 0.33$) in all subjects. The diagnostic sensitivity for AD was 92% for $[^{11}\text{C}]\text{MP4A}$ ratio and 69% for $[^{123}\text{I}]\text{IMP}$ ratio (Fig. 3). Correlation coefficients of IMP ratios, MP4A ratios, k_3 values and rCBF with age in NC were 0.24 (n.s.), 0.19 (n.s.), 0.01 (n.s.) and 0.54 ($p < 0.05$), respectively (Fig. 4).

DISCUSSION

With $[^{11}\text{C}]\text{MP4A}$ and PET, quantitative estimates of k_3 values, i.e., AChE activity, are obtained in the NLLS analysis using the arterial input function.^{4,12} However, this technique requires fast dynamic scans which most SPECT scanners are not able to perform. Meanwhile, semi-quantitative analysis such as IMP ratio analysis is

often used in SPECT studies.^{17,18} Therefore, we analyzed the data of [¹¹C]MP4A PET by simple ratio analysis in the present study.

We selected the cerebellum as the reference region because it is typically chosen as the reference area in SPECT studies. Although the change of AChE activity in AD postmortem cerebellum is not well known, the cerebellum is not affected pathologically and the CBF in the cerebellum is relatively preserved in AD.^{7,19,20}

The radioactivity of a target ROI is described as follows:

$$\text{Target} = \frac{K_{1\text{target}} \times k_3}{k_2 + k_3} \int_0^T C_p(t) dt$$

where $C_p(t)$ represents the time-radioactivity curve of plasma [¹¹C]MP4A.

In the cerebellum, hydrolysis is extremely rapid,^{2,21} i.e. $k_3 \gg k_2$, which implies, $k_2 + k_3 \approx k_3$, and thus the radioactivity of the cerebellum is given as:

$$\begin{aligned} \text{Cerebellum} &\approx K_{1\text{cerebellum}} \int_0^T C_p(t) dt \\ K_{1\text{cerebellum}} &= \text{CBF}_{\text{cerebellum}} \times \text{EF}_{\text{cerebellum}} \\ K_{1\text{target}} &= \text{CBF}_{\text{target}} \times \text{EF}_{\text{target}} \end{aligned}$$

where EF represents extraction fraction. EF is likely to be similar throughout the brain.

Then the MP4A ratio is derived as follows:

$$\text{Ratio} = \frac{\text{CBF}_{\text{target}}}{\text{CBF}_{\text{cerebellum}}} \times \frac{k_3}{k_2 + k_3}$$

Hence, MP4A ratio depends on not only local AChE activity but also rCBF.

This simple MP4A ratio analysis requires neither arterial blood sampling nor fast dynamic scans, and is thus, non-invasive and applicable to SPECT. In spite of this simplicity, the sensitivity for detecting abnormal change in AD should theoretically be higher than that of quantitative k_3 estimates in MP4A PET, because, as described above, the MP4A ratio in the cerebral cortex is determined by local AChE activity and rCBF, both of which are reduced in the cerebral cortex in patients with AD. The correlation between the MP4A ratios and k_3 values (0.69) was better than that between the MP4A ratios and K_1 values (0.33), suggesting that the MP4A ratio represents mainly AChE activity and only partly rCBF. The coefficient of variance (COV) of the MP4A ratio was relatively small compared with k_3 values (Table 1, Table 2).

Numerous studies have reported the sensitivity of CBF SPECT for the diagnosis of AD, although the sensitivity differed considerably in each study (41 to 96%).^{22,23} Hanyu et al. reported that [¹²³I]IMP SPECT has a sensitivity of 82% for detecting unilateral temporoparietal hypoperfusion and 63% for detecting bilateral temporoparietal hypoperfusion in AD.²⁴ In the present study, the sensitivity for detecting 3 positive ROIs in IMP ratio as the diagnosis of AD was 69% and that for detecting

2 positive ROIs was 92%. Our results of IMP SPECT were compatible with those of previous studies.^{22–24} As for the MP4A ratio analysis, the sensitivity of detection of 3 positive ROIs as the diagnosis of AD was 92% (Fig. 3). Thus, the sensitivity of the simple MP4A ratio analysis in MP4A PET was higher than that of IMP ratio analysis in IMP SPECT in detecting abnormal regions of AD in the present study. This result may be partly attributable to the fact that MP4A ratio depends on not only local AChE activity but also rCBF.

Previous [¹¹C]MP4A and [¹¹C]MP4P PET studies have reported that AChE activity in the cerebral cortices does not change significantly with age, whereas CBF in the cerebral cortices decreases significantly.^{7,25,26} In the present study, we found that the MP4A ratio and k_3 values in the cerebral cortices did not change significantly with age at all, while the IMP ratio and rCBF in the cerebral cortices did tend to change significantly (Fig. 4). Thus, the effect of age is not a major concern when this MP4A ratio analysis is used for the diagnosis of AD patients, which may be another advantage of the MP4A ratio analysis over the IMP ratio analysis.

Clinical trials in patients with AD have shown that AChE inhibitors such as donepezil hydrochloride improve cognitive dysfunction and behavioral psychiatric symptoms of AD. Previous [¹¹C]MP4A and [¹¹C]MP4P PET studies have shown the usefulness for detecting the effect of AChE inhibitors in AD patients *in vivo*. The MP4A ratio analysis should also be useful for detecting and monitoring the effects of AChE inhibitors,²⁷ since the MP4A ratio mainly reflects local AChE activity.

PET technique is still expensive and requires a number of highly trained technical staff. Therefore, the development of SPECT tracers similar to MP4A for the routine examination of dementia is a critical necessity.

ACKNOWLEDGMENTS

We thank the staff of the Department of Medical Imaging, National Institute of Radiological Sciences for supplying [¹¹C]MP4A; Dr. Y. Wada, Siemens-Asahi Medical Technologies Ltd., for technical support for PET data acquisition; and Dr. N. Yui, Division of Nuclear Medicine, Chiba Cancer Center Hospital for performing the SPECT studies.

REFERENCES

1. Perry EK, Tomlinson BE, Blessed G, Bergmann K, Gibson PH, Perry RH. Correlation of cholinergic abnormalities with senile plaques and mental test scores in senile dementia. *BMJ* 1978; 2: 1457–1459.
2. Arai H, Kosaka K, Muramoto O, Iizuka R. A biological study of cholinergic neurons in the post-mortem brains from patients with Alzheimer-type dementia. *Clin Neurol* 1984; 24: 1128–1135.
3. Gsell W, Strein I, Riederer P. The neurochemistry of Alzheimer type, vascular type and mixed type dementias

- compared. *J Neural Transm* 1996; 47(Suppl): 73–101.
4. Irie T, Fukushi K, Akimoto Y, Tamagami H, Nozaki T. Design and evaluation of radioactive acetylcholine analogues for mapping brain acetylcholinesterase (AChE) *in vivo*. *Nucl Med Biol* 1994; 21: 801–808.
 5. Tanaka N, Fukushi K, Shinotoh H, Nagatsuka S, Namba H, Iyo M, et al. Positron emission tomographic measurement of brain acetylcholinesterase activity using *N*-[¹¹C]methylpiperidin-4-yl acetate without arterial blood sampling: Methodology of shape analysis and its diagnostic power for Alzheimer's disease. *J Cereb Blood Flow Metab* 2001; 21: 295–301.
 6. Nagatsuka S, Fukushi K, Shinotoh H, Namba H, Iyo M, Tanaka N, et al. Kinetic analysis of [¹¹C]MP4A using a high-radioactivity brain region that represents an integrated input function for measurement of cerebral acetylcholinesterase activity without arterial blood sampling. *J Cereb Blood Flow Metab* 2001; 21: 1354–1366.
 7. Kuhl DE, Koeppe RA, Minoshima S, Snyder SE, Ficarò EP, Foster NL, et al. *In vivo* mapping of cerebral acetylcholinesterase activity in aging and Alzheimer's disease. *Neurology* 1999; 52: 691–699.
 8. Koeppe RA, Kird A, Frey KA, Snyder P, Meyer MR, Kilbourn, et al. Kinetic modeling of *N*-[¹¹C]methylpiperidin-4-yl propionate: alternatives for analysis of an irreversible positron emission tomography tracer for measurement of acetylcholinesterase activity in human brain. *J Cereb Blood Flow Metab* 1999; 19: 1150–1163.
 9. Ueda T, Irie T, Fukushi K, Ikota N, Takatoku K, Yomoda I, et al. *N*-methyl-3-(1-hydroxy-5-[¹²³I]iodopent-4-enyl)-4-acetoxypiperidine: A novel candidate of acetylcholinesterase activity imaging agent. *J Labelled Cpd Radiopharm* 2000; 43: 753–765.
 10. McKhann G, Drachman D, Folstein M, Katzman R, Price D, Stadlan EM. Clinical diagnosis of Alzheimer's disease: Report of the NINCDS-ADRDA Work Group under the auspices of Department of Health and Human Services Task Force on Alzheimer's disease. *Neurology* 1984; 34: 939–944.
 11. Folstein MF, Folstein SE, McHugh PR. "Mini-Mental State": a practical method for grading the cognitive state of patients for the clinician. *J Psychiatry Res* 1975; 12: 189–198.
 12. Iyo M, Namba H, Fukushi K, Shinotoh H, Nagatsuka S, Suhara T, et al. Measurement of acetylcholinesterase by positron emission tomography in the brains of healthy controls and patients with Alzheimer's disease. *Lancet* 1997; 349: 1805–1809.
 13. Namba H, Yanagisawa M, Yui N, Togawa T, Kinoshita F, Iwadate Y, et al. Quantifying brain tumor blood flow by the microsphere model with *N*-isopropyl-*p*-[¹²³I]iodoamphetamine super-early SPECT. *Ann Nucl Med* 1996; 10: 161–164.
 14. Ohkubo M, Odano I, Takahashi N, Takahashi M, Ohtaki H, Noguchi E, et al. A study on accuracy of rCBF measurement using the conventional microsphere method with *N*-isopropyl-*p*-iodine-[¹²³I]iodoamphetamine and SPECT. *KAKU IGAKU (Jpn J Nucl Med)* 1995; 32: 147–151.
 15. Namba H, Yanagisawa M, Togawa T, Kinoshita F, Sueyoshi K, Yui N. Quantitative measurement of cerebral blood flow by the microsphere model with super-early ¹²³I-IMP brain SPECT. *KAKU IGAKU (Jpn J Nucl Med)* 1997; 34: 1027–1031.
 16. Ikenaga H, Yanagimoto S, Ono S, Tomomitsu T, Mimura H, Morita K, et al. Study of some parameters to calculate regional cerebral blood with microsphere model using *N*-isopropyl-*p*-[¹²³I]iodoamphetamine. *KAKU IGAKU (Jpn J Nucl Med)* 1991; 28: 1187–1191.
 17. Syed GM, Eagger S, Toone BK, Levy R, Barrett JJ. Quantification of regional cerebral blood flow using ^{99m}Tc-HMPAO and SPECT: choice of a reference region. *Nucl Med Commun* 1992; 13: 811–816.
 18. Varrone A, Soricelli A, Postiglione A, Salvatore M. Comparison between cortical distribution of I-123 iomazenil and Tc-99m HMPAO in patients with Alzheimer's disease using SPECT. *Clin Nucl Med* 1999; 24: 660–665.
 19. Geaney DP, Abou-Saleh MT. The use and applications of single-photon emission computerised tomography in dementia. *Br J Psychiatry Suppl* 1990; 9: 66–75.
 20. Kushner M, Tobin M, Alavi A, Chawluk J, Rosen M, Fazekas F, et al. Cerebellar glucose consumption in normal and pathologic status using fluorine-FDG and PET. *J Nucl Med* 1987; 28: 1667–1670.
 21. Atack JR, Perry EK, Bonham JR, Candy JM, Perry RH. Molecular forms of acetylcholinesterase and butyryl-cholinesterase in the aged human central nervous system. *J Neurochem* 1986; 47: 263–277.
 22. Jagust W, Thisted R, Devous MD, Van Heertum R, Mayberg H, Jobst K, et al. SPECT perfusion imaging in the diagnosis of Alzheimer's disease: a clinical-pathologic study. *Neurology* 2001; 56: 950–956.
 23. Scheltens P, Launer LJ, Barkhof F, Weinstein HC, Jonker C. The diagnostic value of magnetic resonance imaging and technetium-99m-HMPAO single photon emission computed tomography for the diagnosis of Alzheimer disease in a community—Dwelling elderly population. *Alzheimer Dis Assoc Disord* 1997; 11: 63–70.
 24. Hanyu H, Nakano S, Abe S, Arai H, Iwamoto T, Takasaki M. Neuroimaging in the diagnosis of Alzheimer's disease. *Jpn J Geriatr* 1994; 31: 683–689.
 25. Namba H, Iyo M, Shinotoh H, Nagatsuka S, Fukushi K, Irie T. Preserved acetylcholinesterase activity in aged cerebral cortex. *Lancet* 1998; 351: 881–882.
 26. Namba H, Iyo M, Fukushi K, Shinotoh H, Nagatsuka S, Suhara T, et al. Human cerebral acetylcholinesterase activity measured with positron emission tomography: procedure, normal value and effect of age. *Eur J Nucl Med* 1999; 26: 135–143.
 27. Shinotoh H, Aotsuka A, Fukushi K, Nagatsuka S, Tanaka N, Ota T, et al. Effect of donepezil on brain acetylcholinesterase activity in patients with AD measured by PET. *Neurology* 2001; 56: 408–410.