Annals of Nuclear Medicine Vol. 13, No. 5, 351–354, 1999

Sub-super bone scan caused by bone marrow involvement of prostate cancer

Yuji SEO, Noriyuki SHUKE, Wakako YAMAMOTO, Kouki USUI and Tamio ABURANO

Department of Radiology, Asahikawa Medical College

A 67-year-old man presented with malaise and marked anemia. A diagnostic workup revealed severe pancytopenia on a complete blood count and diffuse sclerotic change in the axial skeleton on a plain abdominal radiograph. Bone metastases being suspected from these findings, bone scintigraphy was performed. The bone scan demonstrated uniformly increased skeletal activity with faint soft-tissue activity. The findings of the bone scan, however, appeared atypical of the super scan caused by diffuse bone metastases, without any decrease in radioactivities of the appendicular skeleton and kidneys. Bone marrow scintigraphy with In-111 chloride demonstrated central marrow failure and peripheral expansion, which indicated the possibility of myelophthisis. The patient underwent bone marrow biopsy, which revealed replacement of the bone marrow by metastatic adenocarcinoma. Further examinations detected the primary lesion in the prostate. In this case, the findings of the bone scan were insufficient for the super scan, and might be categorized as a sub-super scan. It would be important to recognize this incomplete form of super scan as a rare scintigraphic pattern of diffuse bone marrow metastases.

Key words: sub-super scan, super scan, bone marrow metastases

INTRODUCTION

BONE SCINTIGRAPHY has been performed to search for bone metastasis in various malignancies because of its high sensitivity. As a scintigraphic pattern of metastatic bone involvement which does not show discrete abnormal uptakes, "super bone scan" has been described to alert one not to overlook diffuse bone marrow metastases. The clues for recognizing super scan are diffuse symmetrical increased uptake mainly in the axial skeleton without appreciable kidney and soft-tissue activity. These clues, however, are not always sufficient for detecting diffuse bone marrow metastases, since occasionally they are not seen in a complete form in spite of the presence of severe bone marrow involvement. We experienced a case of prostate cancer with diffuse bone marrow metastases, in which bone scan showed atypical findings of super scan, and bone marrow scintigraphy was useful to confirm the presence of diffuse bone marrow involvement.

Received February 18, 1999, revision accepted July 28, 1999.

For reprint contact: Yuji Seo, M.D., Department of Radiology, Asahikawa Medical College, 4–5–3–11 Nishikagura, Asahikawa 078–8510, JAPAN.

CASE REPORT

A 67-year-old man, who presented with malaise and marked anemia, was admitted to the hospital. Physical examination revealed severe anemia without lymphadenopathy and hepatosplenomegaly. Laboratory tests were normal except for pancytopenia: hemoglobin, 6.6 g/d*l*; RBC, $232 \times 10^4/mm^3$; WBC, $2630/mm^3$; platelets, $9.5 \times 10^4/mm^3$. A plain abdominal radiograph demonstrated diffuse sclerotic change in the axial skeleton. Bone metastases being suspected from these findings, bone scintigraphy was performed with Tc-99m hydroxymethylene diphosphonate (Tc-99m HMDP). Whole body images, taken 2 hours after the injection of Tc-99m HMDP (740 MBq), demonstrated uniformly increased skeletal activity (Fig. 1), but the image appeared atypical of super bone scan caused by diffuse bone metastases, because of the lack of a decrease in the radioactivity of the appendicular skeleton and kidneys. As for the appendicular skeleton, symmetrically increased radioactivities rather than decreased ones were found in the proximal shafts and the ends of the humeri and femora. With regard to these findings, it was a matter of dispute whether the bone images should be interpreted as a super bone scan. Since

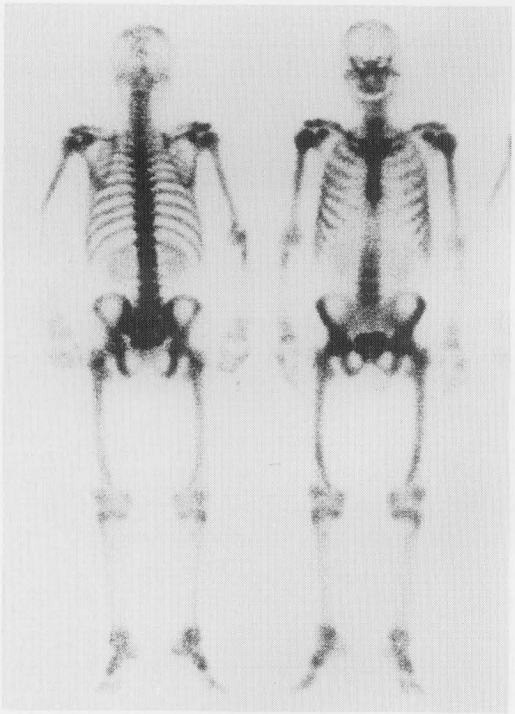

Fig. 1 Bone scan with Tc-99m hydroxymethylene diphosphonate (HMDP) demonstrates diffusely increased activity in the axial skeleton and regional increase in the proximal shafts and ends of femora and humeri. The uniform symmetrical increased activity in the skeleton may be suggestive of a super scan. However, note that the renal activity is not diminished and appendicular skeleton is normally visualized.

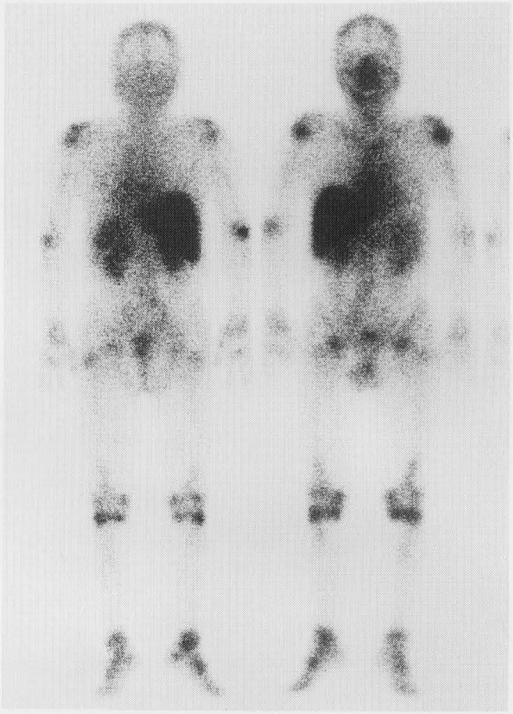

Fig. 2 Bone marrow scan with In-111 chloride demonstrates central marrow failure and peripheral expansion, which suggests primary hematologic disorders or myelophthisis usually caused by hematopoietic neoplasms or bone marrow metastases. Hepatosplenomegaly and extramedullary hematopoiesis are not seen.

a possibility of so-called sub-super scan, which was a rare scintigraphic pattern of diffuse bone marrow metastases, was considered, MRI and bone marrow scintigraphy with In-111 chloride were performed. Whole body images, taken 3 days after the injection of In-111 chloride (111 MBq), demonstrated central marrow failure and peripheral expansion. These findings suggested the presence of primary hematologic disorders or myelophthisis usually caused by hematopoietic neoplasms or bone marrow metastases. Hepatosplenomegaly and extramedullary hematopoiesis were not seen (Fig. 2). Magnetic resonance images of the lumbar spine taken on a unit with a 1.5 T superconducting magnet demonstrated decreased signal intensity in the vertebrae on both T1 (TE = 10 msec/TR = 500 msec) and T2 (TE = 96 msec/TR = 5000 msec) weighted images, indicating the presence of diffuse fatty marrow replacement by the stimulated red marrow or by other causes such as metastatic tumor cells (Fig. 3). Considering the finding of central marrow failure detected on the bone marrow scan, red marrow expansion was not likely and the possibility of bone marrow metastases was highly suspected. The patient underwent bone marrow biopsy, and the biopsy samples from the ilium revealed that the bone marrow was almost completely replaced by metastatic adenocarcinoma. In search of the primary lesion, several screening studies were performed and prostate cancer was detected. Serum PSA was extremely high at 4800 ng/m*l*. The patient has been treated with hormonal therapy.

DISCUSSION

Diffuse metastatic bone involvement of prostate cancer is often demonstrated as a super bone scan on bone scintigraphy. The super bone scan is defined visually as a homogeneous symmetrical increased skeletal radioactivity relative to the soft tissue.[1] The most likely mechanism of super bone scan is diffuse reactive bone formation, which causes diffuse increased uptake of the bone tracer in the skeleton and less uptake in the kidneys and other soft tissues, resulting in an increased skeletal to soft tissue activity ratio. Renal activity is so variable, depending on renal function, that the absence of renal activity should not be used as a strict criterion for the diagnosis. Nevertheless, the absent or faint kidney sign may be a practical clue to the recognition of a super scan.[2,3]

In our case, the bone scan demonstrated slightly increased activities relative to the soft tissue in the axial skeleton and bilateral humeri and femora, but without diminished renal and appendicular skeletal activities, it

Fig. 3 T1 (A) and T2 weighted (B) magnetic resonance images of the lumbar spine. Signal intensity of the vertebrae is decreased on both images, indicating fatty marrow replacement.

appeared unlikely for the super scan to be caused by bone metastases. Where the tracer distribution to the appendicular skeleton was concerned, the bone scan seemed to suggest a generalized metabolic bone disease rather than diffuse bone metastases. Metabolic bone diseases such as hyperparathyroidism could be differentiated from diffuse bone metastases, as the latter usually involves the axial skeleton while sparing the extremities, in contrast to the former which involves both axial and appendicular skeletons.[4] Nevertheless, we should also note the locations of the increased uptakes seen in the bilateral humeri and femora. Increased regional bone tracer uptake in the skeleton can result from increased bone blood flow or an increase in reactive bone formation, and therefore increased marrow blood supply caused by reactive or neoplastic marrow proliferation would be expected to lead to symmetrically increased tracer localization in the metaphyseal regions of long bones.[5,6] In this respect, the symmetrical uptakes at the ends of the humeri and femora were thought to imply a marrow disease, as was confirmed by bone marrow scintigraphy. The bone marrow scintigram apparently showed central marrow failure and peripheral expansion, indicating a marrow disease such as diffuse marrow metastases or hematopoietic neoplasms. Low sensitivity of radionuclide bone imaging is well known in hematopoietic marrow disorders such as leukemia, myelofibrosis and lymphoma, in which there is little reactive bone formation. Except for these hematologic disorders, Podoloff et al.[6] reported a case of breast carcinoma with diffuse marrow metastases, in which bone scan demonstrated only subtle changes in contrast to widespread abnormalities on CT and MRI. On the bone image, there were some increases in skeletal activity without diminution of renal activity. In particular, symmetric regional increases in activity of the ends of long bones and periarticular areas were described as characteristic features. They mentioned that this pattern on the bone image suggested a "forme-frustre" of a super scan, and called it "sub-super scan." Similarly, in our patient the bone scan showed only subtle changes, but the pattern could be categorized as the sub-super scan proposed by Podoloff. We should therefore consider the probability of diffuse bone marrow metastases in addition to primary hematologic disorders. Considering the severity of pancytopenia and marked PSA increase as well as the findings on bone marrow scintigraphy and MRI, the patient had been already in a very progressive state of bone marrow metastases at the time of diagnosis. A sub-super scan therefore does not always appear to indicate the mildness of metastatic disease or the pre-state of super bone scan. From the histopathologic point of view, the primary soil of metastatic bone disease is the microenvironment of bone marrow rather than cortical bone. Types of focal reaction to bone metastasis were classified as osteoplastic, osteolytic, intertrabecular, and mixed type. A high degree of bone marrow replacement usually correlates with the presence of bone destruction and osteoplastic reaction, but the intertrabecular type of metastatic bone

disease occasionally shows slight reaction in the bone matrix in spite of progression of the disease.[7,8] This type of diffuse disease is therefore likely to demonstrate a sub-super scan on bone scintigraphy, and bone marrow scan rather than bone scan is suitable for the detection of the disease.

In summary, although diffuse bone marrow metastases of prostate or breast carcinoma may frequently be demonstrated as a super scan and not as a sub-super scan, we should pay added attention to the recognition of a sub-super scan for correct cancer staging. If a bone scan is still inconclusive for bone marrow metastases, bone marrow scintigraphy may give additional information for the diagnosis and be useful in understanding the histopathological change, although biopsy is necessary for the final diagnosis.

REFERENCES

1. Constable AR, Cranage RW. Recognition of the super-scan in prostate bone scintigraphy. *Br J Radiol* 54: 122–125, 1981.
2. Sy WM, Patel D, Faunce H, Faunce H. Significance of absent or faint kidney sign on bone scan. *J Nucl Med* 16: 454–456, 1975.
3. Lunia SL, Heravi M, Goel V, Tiu AS, Chodos RB. Pitfalls of absent or faint kidney sign on bone scan. *J Nucl Med* 21: 894–895, 1980.
4. Manier SM, Nostrand DV. Super Bone Scan. *Semin Nucl Med* 14: 46–47, 1984.
5. Rieker O, Grunwald F, Layer G, Kurbacher CM, Hotze AL, Menzel C, et al. Disseminated Bone Marrow Metastases from Primary Breast Cancer: Detection and Follow-up by Radioimmune Bone Marrow Scintigraphy. *J Nucl Med* 35: 1485–1487, 1994.
6. Podoloff DA, Kim EE. "Sub"-Super Scan-Manifestation of Bone Marrow Metastases? *Clin Nucl Med* 14: 597–602, 1989.
7. Moriwaki S. Histopathology of Metastatic Bone Tumors. *Jpn J Cancer Chemother* 14: 1680–1687, 1987.
8. Kamby C, Guldhammer B, Vejborg I, Rossing N, Dirksen H, Daugaard S, et al. The Presence of Tumor Cells in Bone Marrow at the Time of First Recurrence of Breast Cancer. *Cancer* 60: 1306–1312, 1987.