Annals of Nuclear Medicine Vol. 12, No. 4, 217–220, 1998

Visualization of pressure-dependent luxury perfusion in a patient with subacute cerebral infarction

Ihn-Ho CHO,* Kohei HAYASHIDA,* Norihiko KUME,*
Yoriko SHIMOTSU* and Kotaro MIYASHITA**

*Department of Radiology, and **Department of Medicine,
National Cardiovascular Center

Luxury perfusion characterized by depressed metabolism compared with CBF might be changed by decreasing cerebral perfusion pressure during the sitting position. A 77-yr-old man with subacute cerebral infarction was studied with brain X-ray computed tomography (CT), raise-up test with ^{99m}Tc-d,l-hexamethylpropyleneamine oxime (HMPAO) brain single photon emission tomography (SPECT) and positron emission tomography (PET). Brain X-ray CT revealed a low-density area in the left middle cerebral artery (MCA) anterior area. Raise-up ^{99m}Tc-HMPAO brain SPECT revealed decreased uptake in the left MCA anterior area in the sitting position and subsequent supine ^{99m}Tc-HMPAO brain SPECT revealed hot accumulation there. PET study in the supine position demonstrated some differences between CBF and the cerebral metabolic rate for oxygen in the left MCA anterior area, indicating luxury perfusion. CBF in the area of luxury perfusion might be decreased during the sitting or standing position and increased during the supine position by dysautoregulation of the cerebral vessels in the luxury perfusion during the subacute infarct.

Key words: luxury perfusion, cerebral autoregulation, raise-up ^{99m}Tc-HMPAO brain SPECT

INTRODUCTION

IN STROKE, paradoxically increased cerebral blood flow (CBF) can be observed at the involved site and is referred to as luxury perfusion.[1] This finding of increased perfusion without increased cerebral metabolic rate for oxygen ($CMRO_2$) is believed to reflect reactive hyperemia in regions of brain surrounding the area of infarction.

A relative increase in blood flow in regions with profoundly depressed $CMRO_2$ or cerebral metabolic rate for glucose (CMR_{Glu}) is often observed between 10 and 40 days after the onset of stroke and reflects cerebral artery paralysis and the low energy consumption of irreversibly damaged neurons, which ultimately become necrotic. Luxury perfusion was noted in the core as well as in the vicinity of the infarct.[2,3] The region of luxury perfusion showed signs of dysautoregulation because the vessels in such regions are already dilated at normal pressure.[1,4]

We report luxury perfusion in which there was demonstrated a loss of autoregulation by raise-up ^{99m}Tc-HMPAO brain SPECT in a patient with subacute cerebral infarction.

CASE REPORT

A 77-yr-old man was admitted to our hospital following the sudden onset of aphasia and urinary incontinence. On physical examination at admission, his blood pressure was 192/88 mmHg and heart rate was 78 bpm. Based on results of neurological evaluation, transcortical mixed aphasia was diagnosed.

Brain X-ray CTs were obtained on the 2nd and 16th hospital days. The first examination revealed a low-density area in the left middle cerebral artery (MCA) anterior area, and this low-density area was faintly visualized in the second brain X-ray CT, with a fogging effect (Fig. 1).

Neck echogram revealed total occlusion of the left internal carotid artery with plaque in the region of the

Received November 27, 1997, revision accepted June 4, 1998.

For reprint contact: Kohei Hayashida, M.D., National Cardiovascular Center, Department of Radiology, 5–7–1 Fujishirodai, Suita, Osaka 565–8565, JAPAN.
E-mail: khysd@hsp.ncvc.go.jp

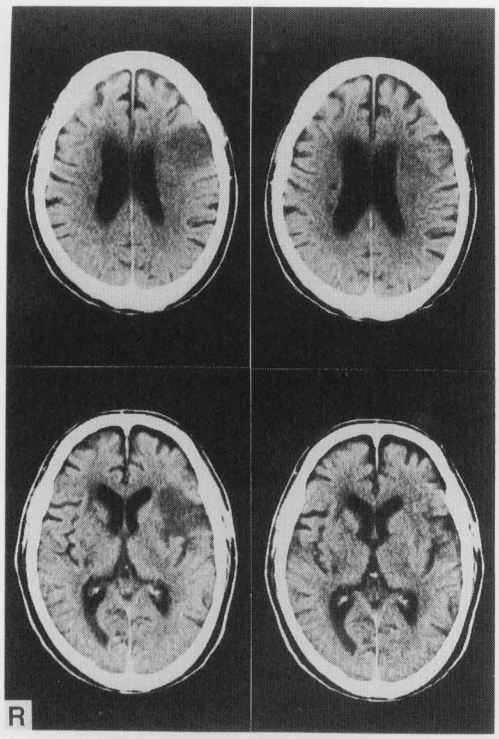

Day 2 Day 16

Fig. 1 Brain X-ray CT (left) shows a low-density area in the left MCA anterior area. This low-density area is faintly visualized in a later brain X-ray CT image (right), suggesting fogging effect.

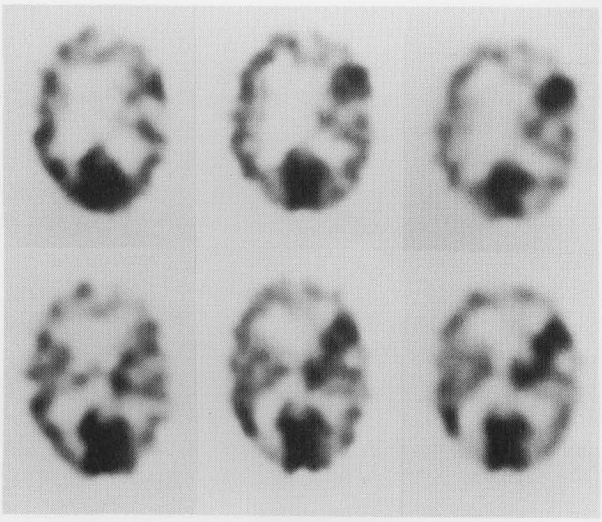

UP DOWN SUB

Fig. 2 ^{99m}Tc-HMPAO brain SPECT images reveal decreased activity in the left MCA anterior area in the sitting position and hot accumulation in the supine position. ^{99m}Tc-HMPAO brain SPECT subtraction image demonstrates hot accumulation in the left MCA anterior area, indicating luxury perfusion in the supine position. (UP: sitting position image, DOWN: supine position image, SUB: subtracted image)

bifurcation of the left carotid artery. A raise-up test with ^{99m}Tc-HMPAO brain SPECT was performed on the 14th hospital day, and brain PET was performed on the 22nd hospital day.

Raise-Up Test with ^{99m}Tc-HMPAO Brain SPECT

After insertion of a flexible plastic needle into the antecubital vein, the patient lay on a bed in a quiet and dim room. After being supine for 30 minutes, he was instructed to sit up within about 3 seconds. As soon as he had sat up, he was injected with 370 MBq ^{99m}Tc-HMPAO in a bolus flushed with 20 m*l* saline and then moved to the imaging room to initiate the first SPECT scan after 10 minutes of injection. After the first SPECT study, another 480 MBq ^{99m}Tc-HMPAO was administered while the patient remained in the SPECT bed. During these two SPECT studies, the position of the patient's head was monitored by alignment with reference points. His blood pressure was measured with a sphygmomanometer at 1-min intervals.[5]

^{99m}Tc-HMPAO brain SPECT was performed with a conventional rotating gamma camera (STARCAM, 400AC/T, General Electric Co.) with a restraint firmly attached to the headrest and marking reference points reflected by lasers. Data were obtained from 64 projections with a sampling time of 20 seconds; a general all-purpose collimator was employed, and data were collected into a 64 × 64 matrix. Data acquisition in the second brain SPECT study was performed as in the first study, except that the sampling time was 15 seconds. Data were processed to measure the net change in cerebral blood flow, first by subtraction of projection data from the first and second brain SPECT studies with dose and acquisition time correction, and then by reconstruction as in the first brain SPECT study but with additional 3 × 3 smoothing. All data were corrected for an attenuation of 0.45 cm^{-1}, and the tomographic data were reconstructed with a filtered back-projection algorithm. In this fashion, transaxial, coronal and sagittal slices were obtained, with each slice being 6 mm in thickness.

PET

CBF, oxygen extraction fraction (OEF) and $CMRO_2$ were measured with a Headtome IV PET scanner (Shimadzu, Kyoto, Japan) with a spatial resolution of 4.5 mm at FWHM and ^{15}O-labeled gas inhalation.[6,7] Emission scans were corrected for the effect of tissue attenuation by using a transmission scan with an external ^{68}Ge-^{68}Ga ring source. Separate emission scans were performed during continuous inhalation of ^{15}O-labeled carbon dioxide ($C^{15}O_2$) and oxygen ($^{15}O_2$) for the measurement of CBF and OEF, respectively. During the scans, serial blood samples were obtained through a fine gauge brachial artery catheter for measurement of arterial isotope activity and arterial oxygen content (O_2con), and arterial PCO_2. $CMRO_2$ was calculated as CBF × OEF × O_2con.

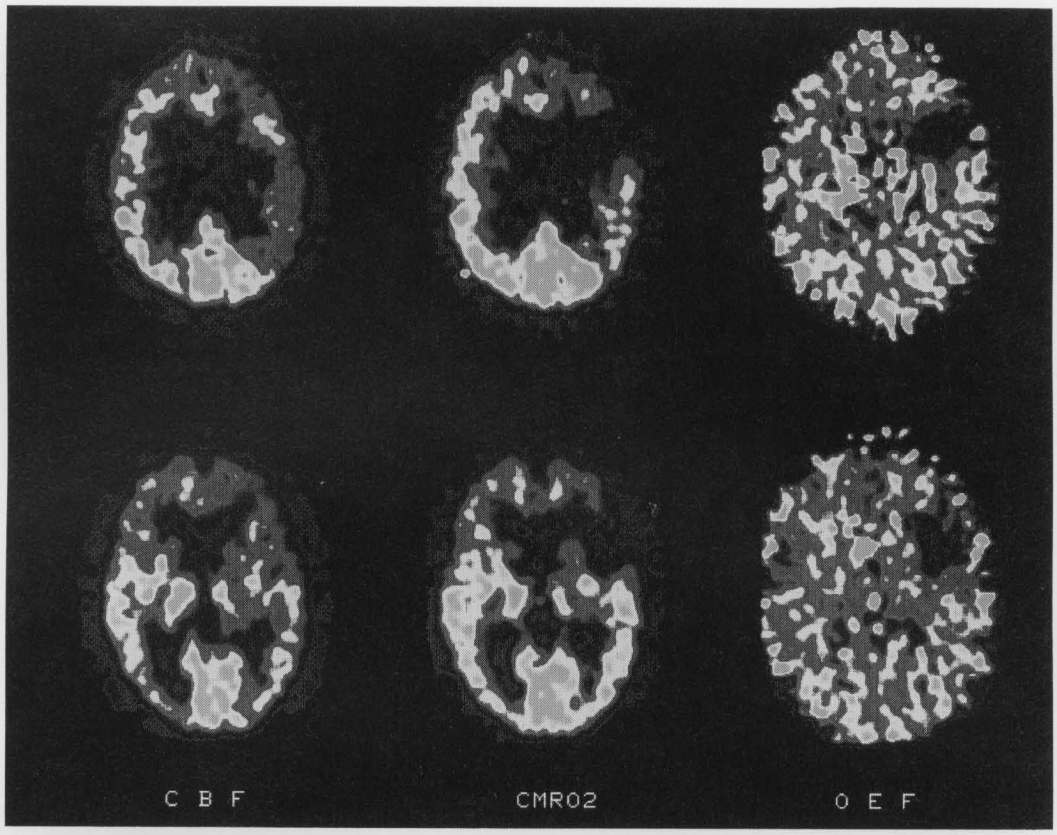

Fig. 3 PET shows that CBF is increased in the left MCA anterior area, but that $CMRO_2$ and OEF are decreased in there, indicating luxury perfusion. (CBF: regional cerebral blood flow, $CMRO_2$: cerebral metabolic rate of oxygen, OEF: oxygen extraction fraction)

RESULTS

The patient's blood pressure fell from 160/90 mmHg in the supine position to 150/88 mmHg in the sitting position without neurological symptoms. ^{99m}Tc-HMPAO brain SPECT revealed decreased uptake in the left frontotemporal area in the sitting position and hot accumulation in subsequent supine brain SPECT images. The subtraction image obtained by subtraction of sitting from supine position images revealed hot accumulation in the left frontotemporal area (Fig. 2). The CBF on PET in this region was only slightly decreased below that of the corresponding region on the healthy side, but $CMRO_2$ and OEF were noticeably decreased in the left frontotemporal area. The CBF on PET in the region of infarction was 27.5 m*l*/100 mg/min, but $CMRO_2$ and OEF were 1.41 m*l*/100 g/min and 0.31, respectively (Fig. 3). The infarct/corresponding region of the contralateral hemisphere ratio was 0.88 for CBF, and 0.50 for $CMRO_2$, indicating luxury perfusion. The infarct/corresponding region of the contralateral hemisphere ratio with ^{99m}Tc-HMPAO brain SPECT was 1.31 in the supine image, 0.95 in the sitting image and 1.39 in the subtracted image.

DISCUSSION

We observed pressure-dependent luxury perfusion with raise-up ^{99m}Tc-HMPAO brain SPECT in subacute infarction.

The presence of a focal region of hyperemia in the cerebral infarction was the first described by Lassen in 1966 as the "luxury perfusion syndrome." Luxury perfusion is characterized by an overabundant cerebral blood flow relative to the metabolic needs of the brain tissue.[1]

Normally, cerebral vasodilatation caused by a decrease in blood pressure tends to keep regional cerebral blood flow constant despite the drop in pressure.[8] This regulatory mechanism (cerebral "autoregulation") is expected to be diminished or absent in regions with "luxury perfusion," since in such regions the vessels are already dilated at normal pressure.[1,4]

Large CBF changes between the sitting position and supine position were noted in our case. Lower CBF in the sitting position may be due to the loss of cerebral autoregulation. The change in CBF in the luxury perfusion was large despite only a small decrease in systemic blood pressure from 160/90 mmHg to 150/88 mmHg without neurological symptoms. The infarcted area with luxury

perfusion might be very sensitive to changes in cerebral perfusion pressure.

Raise-up ^{99m}Tc-HMPAO brain SPECT and PET studies were done in our patient with the subacute infarction. PET demonstrated luxury perfusion in the infarcted area. CBF in the luxury perfusion fluctuated according to body position, since raise-up ^{99m}Tc-HMPAO brain SPECT revealed decreased uptake in the infarcted area in the sitting position and hot accumulation in the supine position. This strongly suggests that CBF in luxury perfusion might be unstable due to the patients position because of the loss of autoregulation.

REFERENCES

1. Lassen NA. The luxury-perfusion syndrome and its possible relation to acute metabolic acidosis localised within the brain. *Lancet* 19: 1113–1115, 1966.
2. Ackerman RH, Correia JA, Alpert NM, Baron JC, Gouliamos A, Grotta JC, et al. Positron imaging in ischemic stroke disease using compounds labeled with oxygen 15; initial results of clinicophysiologic correlations. *Arch Neurol* 38: 537–543, 1981.
3. Lenzi GL, Frackowiak RST, Jones T. Cerebral oxygen metabolism and blood flow in human cerebral ischemic infarction. *J Cereb Blood Flow Metab* 2: 321–335, 1982.
4. Olsen TS, Larsen B, Skriver EB, Herning M, Enevoldsen E, Lassen NA. Focal cerebral hyperemia in acute stroke; incidence, pathophysiology and clinical significance. *Stroke* 12: 598–607, 1981.
5. Hayashida K, Nishiooeda Y, Hirose Y, Ishida Y, Nishimura T. Maladaption of vascular response in frontal area of patients with orthostatic hypotension. *J Nucl Med* 37: 1–4, 1996.
6. Frackowiak RSJ, Lenzi GL, Jones T, Heather JD. Quantitative measurement of regional cerebral blood flow and oxygen metabolism in man using ^{15}O and positron emission tomography: Theory, procedure, and normal values. *J Comput Assist Tomogr* 4: 727–736, 1980.
7. Lammertsma AA, Jones T, Frackowiak RSJ, Lenzi GL. A theoretical study of the steady-state model for measuring regional cerebral blood flow and oxygen utilization using oxygen-15. *J Comput Assist Tomogr* 5: 544–550, 1981.
8. Lassen NA. Autoregulation of cerebral blood flow. *Circulation Research* 15 (suppl. I): 201–204, 1964.