Annals of Nuclear Medicine Vol. 12, No. 3, 165–167, 1998

Extrarenal uptake of Tc-99m-DTPA in a case of retroperitoneal abscess causing spurious data in renal function assessment

Wonsick CHOE

Nuclear Medicine Service, Department of Veterans Affairs Medical Center and Department of Radiology, The University of Texas Southwestern Medical Center, Dallas, Texas, U.S.A.

The author reports CT of the abdomen and quantitative analysis of renal scintigraphy that was spuriously assessed due to unwanted extrarenal uptake. The patient had a retroperitoneal abscess that was related to fistula from the right kidney. Renal scintigraphy was performed to assess split renal function as a preoperative evaluation for nephrectomy. The computer generated differential function did not appear to coincide with the visual analysis. This discrepancy was believed due to extrarenal uptake from the area of the retroperitoneal abscess.

Key words: renal scintigraphy, split renal function, spurious data, retroperitoneal abscess

INTRODUCTION

SPLIT RENAL FUNCTION assessment with intravenous injection of radiotracer has been available, and a commonly used radioisotope is Technetium-99m. Rarely, uptake of the radioisotope outside the genitourinary system has been reported on various occasions.[1] Among them there was a case report of retroperitoneal abscess imaged with Technetium-99m-glucoheptonate.[2] The patient to be presented had a retroperitoneal abscess but was imaged with a different radiotracer, Technetium-99m Diethylenetriaminepentaacetic acid (DTPA). The renal images of this patient also demonstrated the presence of extrarenal uptake, and actually created spurious data in split renal function assessment.

CASE REPORT

The patient was a 75-year-old man, who was admitted for right flank pain. Urinalysis was positive for infection and leukocytosis was present. CT obtained prior to this admission had shown that the kidneys contained cysts. Particularly the right kidney contained a large septated complex cyst, and the patient had continually developed urinary infections over the last several years. CT obtained on this admission demonstrated a large perirenal mass and fluid collection that extended through the posterior soft tissue (Fig. 1). Intravenous antimicrobial therapy was started, and CT-guided drainage was performed, which removed approximately 800 m*l* of thick, purulent material. Follow-up CT was obtained approximately one month after the drainage (Fig. 2).

The highest levels of BUN and creatinine during this admission were 41 mg/d*l* (normal, 6–19 mg/d*l*) and 1.6 mg/d*l* (normal, 0.5–1.2 mg/d*l*). Elective right nephrectomy was planned, and preoperative renal imaging to assess split renal function was performed. Technetium 99m-DTPA 555 MBq (15 mCi) was intravenously administered. A Toshiba 7200A dual-headed camera and software were used for the imaging. Flow images at 1.5 second intervals for 1 minute were obtained. Subsequently 30 second interval posterior images were obtained for 45 minutes. Time-activity curves were generated by drawing regions of interest, and quantitative analysis was performed.

Renal images showed definite asymmetry in uptake (Fig. 3A). Nevertheless, the split renal function determined by computer-analysis (Left 54% vs. Right 46%) did not appear to reach the degree of asymmetry that was visually observed. Interestingly, there was diffusely increased uptake surrounding the right kidney and extending medially and superiorly. This uptake was considered due to the residua of the known retroperitoneal abscess.

Received January 8, 1998, revision accepted March 10, 1998.

For reprint contact: Wonsick Choe, M.D., Nuclear Medicine, Inha University Hospital, Inchon, S. KOREA 400–103.

E-mail: wchoe@dragon.inha.ac.kr

When a region of interest (ROI) for background subtraction was intentionally placed in the area that included the abscess, the degree of asymmetry approached that of visual analysis (Left 78% vs. Right 22%) (Fig. 3B).

DISCUSSION

The area of residue of the abscess showed diffusely increased uptake.[1-3] Drawing a ROI for the right kidney summed all the counts of radioactivity crossing the abdomen throughout from posterior to anterior. The computer

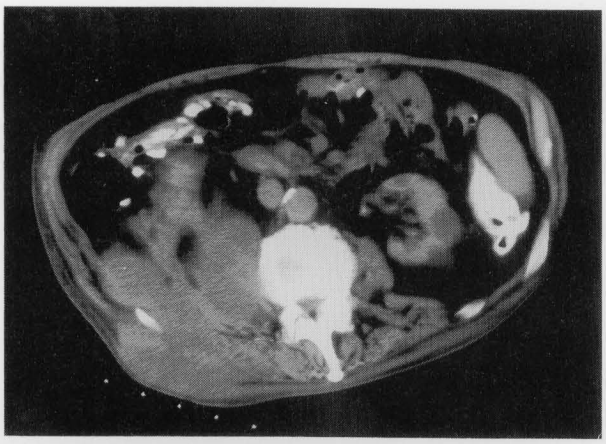

Fig. 1 CT shows a huge perirenal mass and fluid collection that extends through the posterior soft tissue.

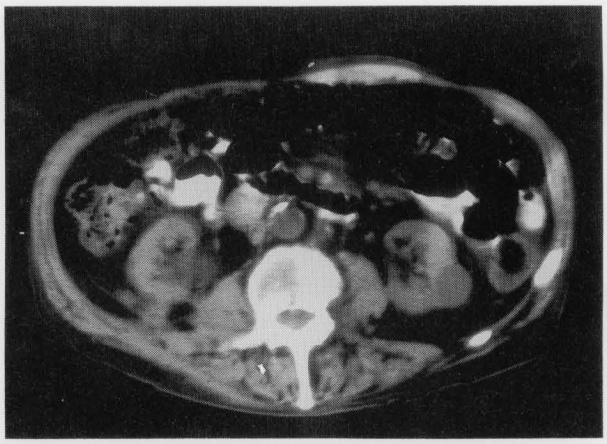

Fig. 2 CT shows remarkably decreased but persistent perirenal and psoas abscess.

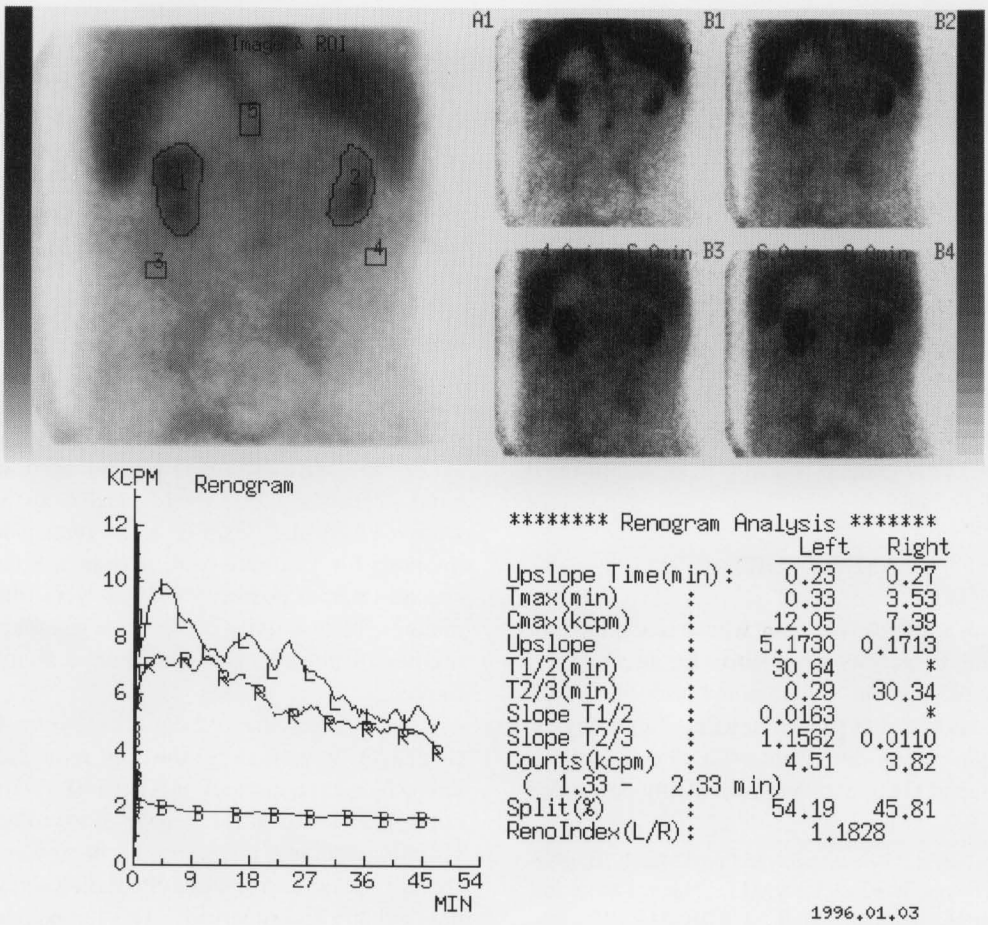

Fig. 3A

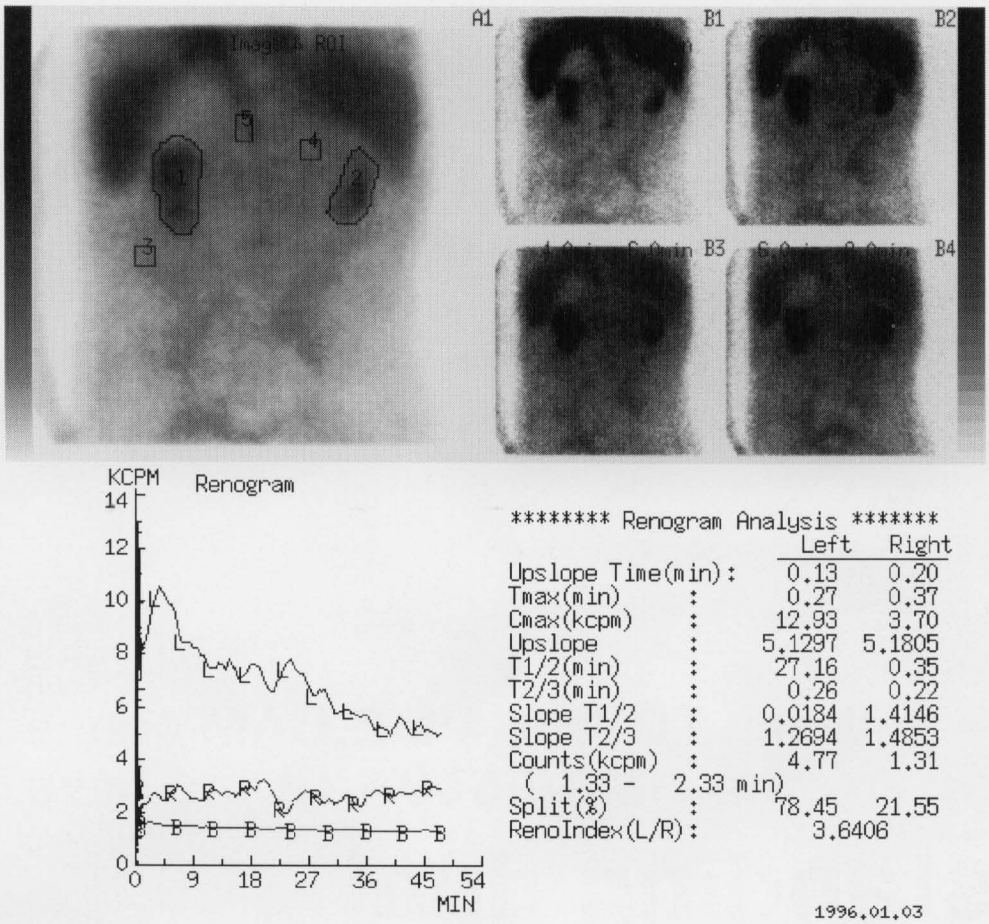

3B

Fig. 3 Renal imaging shows definite asymmetry in uptake (Fig. 3A), but the computer generated split renal function (Left 54% vs. Right 46%) does not appear to reach the visually observed asymmetry. Reprocessing with different placement of background subtraction shows that the degree of asymmetry approaches that of visual analysis (Left 78% vs. Right 22%) (Fig. 3B). The image of the left kidney shows a photopenic area in the lower half of the kidney that corresponds with a simple cyst seen on CT imaging.

analysis surely included the extrarenal uptake from the abscess that was located posteriorly to the kidney, which caused a spuriously increased count. When reprocessing was performed by intentionally placing a ROI for the background subtraction into the area of residue of the abscess, the asymmetry changed; it became similar to that of visual analysis. This was simply because that ROI contained more counts for subtraction than that of the conventional background subtraction. The unwanted counts of radioactivity were subtracted by intentional placement of a ROI for the background subtraction in the abscess area, that there might be the same number of unwanted counts as in the extrarenal uptake posterior to the right kidney.

Routine quantitative analysis by computer and visual analysis should be complementary to each other and the interpreters should have insight into the particular clinical problem.

REFERENCES

1. Datz FL. Renal imaging. DTPA uptake outside the genitourinary system. *In* Gamuts in Nuclear Medicine. Datz FL (ed.), 3rd ed., Missouri, Mosby, pp. 358–359, 1995.
2. Sty JR, Wells RG. Tc-99m glucoheptonate imaging retroperitoneal abscess. *Clin Nucl Med* 15: 270–271, 1989.
3. Goshen E, Meller I, Lantsberg S, Sagi A, Moses M, Fuchsbrauner R, et al. Radionuclide imaging of soft tissue masses with Tc-99m DTPA. *Clin Nucl Med* 16: 636–642, 1991.